COUNTWAY LIBRARY
HC 52DD J

BOSTON MEDICAL LIBRARY
PURCHASED FROM THE INCOME OF THE
SAMUEL WHEELER WYMAN
MEMORIAL FUND

6/6

"UNRIPE" CATARACT.

Printed by
Wm. Strain and Sons,
Belfast.

A TREATISE

ON

"UNRIPE" CATARACT

BY

WILLIAM A. M'KEOWN, M.D., M.CH.

Surgeon to the Ulster Eye, Ear, and Throat Hospital, Belfast;
Member of the Senate of the Royal University of Ireland;
Lecturer on Ophthalmology and Otology, Queen's College, Belfast

---

ILLUSTRATED BY NINE PLATES CONTAINING SIXTY ORIGINAL DRAWINGS.

London:
H. K. LEWIS, 136, GOWER STREET, W.C.

1898

18674 Hy
28 N. 92



This Treatise is Dedicated

TO

MISS HARRIET BENN

IN RECOGNITION OF

THE GREAT SERVICES RENDERED BY HER FAMILY AND HERSELF

TO THE RELIEF OF SUFFERING AND THE ADVANCE OF

SURGICAL SCIENCE BY THE ESTABLISHMENT AND

ENDOWMENT OF HOSPITALS IN THE CITY OF

BELFAST, AND AS A SLIGHT MARK OF

THE SINCERE REGARD OF THE

AUTHOR.

PREFACE.

In the year 1884—just fourteen years ago—I brought to the notice of the Profession the Treatment of Immature Cataract by Intra-ocular Injection and Irrigation, in my address as President of the Ophthalmological Section of the British Medical Association, at its meeting in Belfast. The method was not limited to that form of Cataract, but likewise was advocated for removal of Cortex in Cataracts completely developed as a substitute for other methods.

From that time till the present, Injection and Irrigation have been in constant use by me, and I have applied them in about 700 cases of various kinds. My purpose now is to limit my observations as much as possible to the immature or unripe forms.

There is doubtless a widespread desire on the part of the Profession to operate on Cataract at an earlier period than has been hitherto customary. The *sine qua non*, however, to give effect to such desire is a method of very general application, involving no very great difficulty for the surgeon, and no special risk for the patient, with a precise statement of the rules for its application, and detailed reports of an adequate number of illustrative non-selected cases. It seems to me that the time is opportune for a serious consideration of the subject.

When I began, some time ago, to give renewed attention to the subject, with the view of writing an article for one of our periodicals, I found it necessary to regard the matter in so many aspects that I could not do justice to the importance of it in a short space, and I considered my purpose might be better served by putting my views in the more lasting and more readily accessible form of a monograph.

The treatment of Unripe Cataract of the common cortical forms was a matter of such frequent occurrence in my practice that I had almost ceased to regard it as at all out of the common. So it happened that I did not take always, as I should have done, full notes of all the circumstances of each operation at the time.

I have already reported on several occasions to societies and in journals the results of my earliest work with my instruments of the early period, but I have published nothing on the subject for the past eight years.

My purpose is to give particulars of my own most recent work and views. I am aware of the work done by other surgeons in Intra-ocular Irrigation; but it would serve no useful purpose, and be outside the scope of this treatise, to enter upon any detailed description of their various views and practice, or of the various instruments devised by them for the purpose.

It may be noted that I use as the title of this treatise the term "Unripe Cataract," which I condemn as unscientific and of no definite meaning. I am obliged, however, to use it as giving, in what I hope I may justly designate the present transition stage, the best idea of the general scope of the subject of which I treat.

I am much indebted to the artist, Mr. Kilpatrick, of this city, for the excellent drawings made by him under my supervision, and on which he expended much time and care, and to the Zinco-Collotype Company, of Edinburgh, for the delicacy and truthfulness of their reproduction.

Messrs. Weiss & Co. have kindly lent me the electros of instruments which appear in the text.

WILLIAM A. M'KEOWN.

BELFAST,
November, 1898.

CONTENTS.

CHAPTER I.

GENERAL OBSERVATIONS.

The Primary Object of this Treatise.—The Present Position of the Surgery of Cataract.—The Removal of Cortical Substance the Chief Question.—The Importance of the Solution of the Problem of Safe Early Operation.—The Surgery of Cataract for some time non-progressive.—Circumstances, Past and Present, limiting Range of Operation—Efforts to Extend Range of Operation.—Uncertainty of Diagnosis and Insufficient Surgical Resources.—A Rooted Idea to be Discarded ... ... Page 13—22

CHAPTER II.

CLASSIFICATION.

Objections to Various Classifications.—Essentials of a good Classification—should be Objective, and not Inferential.—Objections to various Terms in Common Use.—Llandolt's Proposition.—Vagueness even in Use of Terms supposed to represent Facts.—Cataracts Adapted for Main Classification on Structural Basis.—Cataracts also to be considered Functionally and Surgically.—Cataracts considered Structurally.—Cataracts in regard to Stage of Development, Complete and Incomplete.—Sharp Distinction between Cortical and Nuclear Cataracts.—Cataracts considered Functionally.—Structural Completeness and Incompleteness not equivalent to Functional.—Cataracts considered Surgically—Surgical Completeness and Incompleteness.—Detailed Structural Classification Page 23—38

CHAPTER III.

EXAMINATION OF THE PATIENT.

Objective Examination.—Simple Inspection.—Oblique Illumination.—Ophthalmoscopic Examination. — The Use of a Mydriatic.—Examination in Secondary Cataract ... ... Page 39—44

SUBJECTIVE EXAMINATION.—The Degree of Vision.—The Amount of Light Perception.—Sudden Diminution of Light Perception in Affections of the Vitreous.—Temporary Diminution of Light Perception.—Examination of Phosphenes.—Manner of Onset.—Age of the Patient.—Age of the Cataract.—General History and Condition.—Patient's Own Story.—Judging the Value of Different Factors Page 44—52

CHAPTER IV.

REMOVAL OF CORTEX.

Discussion of Methods from a Physical Standpoint.—Different Typical Conditions.—Methods of Dealing with Cortex.—Preliminary Treatment of Cortex.—Preliminary Needle Operation some time before Extraction.—Foster's Artificial Maturation some time before Extraction.—Intra-capsular Injection by Hollow Needle as a stage in the Extraction at one Sitting.—Action of Liquid Injected.—Methods Applicable after Expulsion of Body of Lens.—Pressure and Friction, and what they can do.—Scooping, and what it can do.—The Force and Disintegrating Action of Liquid Introduced into the Eye; and what they can do.—Combinations of Methods. — Intra-capsular Injection by Hollow Needle and Massage.—Scoop with Irrigation.—Irrigation and Massage.—Form of Jet from Irrigating Nozzle.—Diagnostic and Prognostic Value of Intra-capsular Injection by the Hollow Needle.—Table showing Probable behaviour of Various Descriptions of Cataract on Operation ... ... Page 53—65

CHAPTER V.

PREPARATION FOR OPERATION.

Asepticism and Antisepticism in Ophthalmic Surgery.—The Micro-Organisms to be Killed.—Antiseptic and Germicidal Agents.—Physical and Chemical.—Objections to Mercuric Preparations.—Chinosol as a Substitute for Mercuric Preparations.—Explanation of the Success Attending Antiseptic Methods. — Preparation of the Patient.—Selection and Preparation of Instruments.—Suitable Light and Optical Aids.—Electric Lamp, Acetylene Lamp, Magnifying Lenses.—Suitable Assistance.—Antiseptic and Aseptic Solutions and Dressings ... ... Page 66—81

CHAPTER VI.

DETAILED DESCRIPTION OF APPARATUS FOR INJECTION AND IRRIGATION AND METHOD OF USE.

Sterilizing and Irrigating Bottle.—Needles and Nozzles.—How to Maintain the Apparatus at a Suitable Temperature.—Different Modes of Using Irrigator.—Preparation of Irrigator for Operation.—Injection and Irrigation, Slight or Free.—The Liquid to be Used.—Tenacity of Prejudices.—Exclusive Charge of Irrigator by Experienced Nurse ... . Page 82—92

CHAPTER VII.

OPERATIONS FOR CATARACT.

Technique of Intra-capsular Injection by Hollow Needle.—Technique of Irrigation.—Needle Operation.—Simple Linear Extraction.—Wecker's 3 Mm. Flap.—Irrigation for Toilette of Wound.—When Section Downwards should be Made.—Variations of Section.—Should Iridectomy, as a rule, be Performed in Cataract Operations.—Accidents and Circumstances during Operation by Injection and Irrigation.—Difficulty of Introducing Hollow Needle.—Prolapse of Vitreous.—High Tension during Operation.—Operations on Traumatic Cataract ... ... Page 93—109

CHAPTER VIII.

POST-OPERATIVE INCIDENTS AND TREATMENT.

Suppuration of the Wound.—Slow Healing of the Wound.—Total Want of Reparative Power of Cornea.—Iritis and Irido-choroditis.—Nervous Shock from Cataract Operation.—Secondary Cataract Page 110—125

CHAPTER IX.

STATEMENT OF CASES.

Table I.—Incomplete Cortical Cataract in persons under 30 years of age.
Table II.—Incomplete Cortical Cataract in persons from 30 to 60 years.
Table III.—Incomplete Cortical Cataract in persons 60 years and upwards.
Table IV.—Cataracts with Semi-Transparent Cortex Simulating Complete Cataract.

Table V.—Incomplete Cortical Cataract with very fine Cortical Opacities Associated with Myopia.
Table VI.—Incomplete Cortical Cataracts Characterised by White Opacities, like bars of varying size and shape, with intervening clear spaces.
Table VII.—Posterior Polar Cataracts.
Table VIII.—Zonular Cataracts with Nucleus.
Table IX.—Incomplete Nuclear Cataract in persons under 60.
Table X.—Incomplete Nuclear Cataract in persons 60 years and upwards.
Table XI.—Anomalous Sclerosis of Lens Secondary to Inflammatory Conditions.
On Cataracts at Stages Sequential to that of Complete Development.—On Traumatic Cataract.—Remarks on the Tables.—The Efficiency of the Methods of Dealing with and Removing Cortex.—Accidents during Operation.—Post Operative Incidents.—The Confirmation or Disproof of Certain Notions.—Estimation of the Value of some Diagnostic Points.—Early Operation in relation to the well-being of the Patients ... ... Page 126—181

CHAPTER X.

Conclusions ... ... Page 182—184

APPENDICES.

A.—Discussion of the Question of Iridectomy in Cataract Operations Page 185—192
B.—Extracts from Address of Author as President of the Ophthalmological Section of British Medical Association in 1884 ... Page 193—196

Index ... ... Page 197—202

BOSTON MEDICAL
APR 1 - 1911
LIBRARY

CATARACT.

CHAPTER I.

GENERAL OBSERVATIONS.

The Primary Object of this Treatise.—My primary object is to contribute from my personal experience to a more precise clinical knowledge of the various forms of cataract, and especially their behaviour under operation ; to shew how various forms and stages of cataract, hitherto not usually thought suitable for surgical treatment, may be successfully operated on ; and to support my views by detailed reports of cases in such numbers of the common forms as to put aside, as far as possible, the element of chance.

The Present Position of the Surgery of Cataract.—To judge of the questions which demand attention it is desirable first, however, to take a brief survey of the present position of the surgery of cataract. I think the following is a fair statement :—

(1.) The relatively good results of operations at the present time on cataracts, presumed to be ripe, is owing chiefly to antiseptic and aseptic precautions, and not to any special form of section or other operative detail.

(2.) Almost all operators of experience, however they may vary in details, shew by their statistics about the same average of good, doubtful, and bad results, and whenever a difference appears it involves, not a

radical matter of principle or method, but a more careful selection of cases, or, perhaps, manual dexterity.

(3.) With a few exceptions, surgeons only operate on those cases which, in their opinion, have reached the stage in which it is supposed to be easy to extract—in other words, have become "ripe."

(4.) "Unripe," or incomplete cataracts cannot, in the majority of cases, be extracted by the ordinary methods with certainty and safety, and hence persons suffering from such cataracts are allowed to wait till "ripeness" is reached—a period of months or years—the worry and anxiety, the loss of health and the loss of means, being considered lesser evils than the risk of an unsuccessful operation.

(5.) The real barrier, at the present time, to the surgical treatment of all those cases which are reckoned "unripe" is the difficulty of removing cortex, sometimes certain, sometimes supposed, and how to remove that barrier is the great question in the surgery of cataract.

(6.) The difficulty of removing cortex, which is generally recognized as the chief danger in operating on "unripe" cataract, also accounts for a considerable proportion of the failures, absolute and relative, in operations on cataracts specially selected because of their "ripeness."

(7.) The method of removing cortex by massage and scoops is no better than it was a long time ago, and no improvement in that method can be reasonably expected.

(8.) When it is stated that "unripe" cataracts have been operated on by the old methods with success, it is almost certain the cataracts belonged to only one class of "unripe" cataract—viz., sclerosed lenses (described hereafter as incomplete nuclear cataract) easily extracted,

though not completely opaque—and the other forms of "unripe" cataract were not included.

(9.) The persons, at any time or place, suffering from cataract not fully developed, but sufficiently so to disable from work, outnumber those in whom the process has reached completion, and a means which would bring them early relief would be an invaluable boon.

The Removal of Cortical Substance the Chief Question.—The possibility of the complete removal of the cortex depends, not on the condition of the whole of it, but of the superficial cortical layers, and the nature of their connection with the capsule. If the cortical layers, whether soft or hard, separate readily from the capsule, the operation is, as a rule, easy, and success in completing it is practically assured; if not, the operation may be attended with grave difficulties, and the whole of the lens may not be removed. A competent operator, with a steady patient, is pretty sure to complete all the other stages of the operation to his satisfaction, but in a certain proportion, even of selected cases, the surgeon may have been mistaken in his diagnosis on this important point, and the removal of cortex is then the most delicate and difficult stage of the operation. Any method, or methods, therefore, more effective than that by massage and scoops for removal of cortex will be a valuable addition to our surgical resources, even for ordinary operations, but for operation on incomplete cataract such are absolutely essential. Cortical cataracts are really allowed to reach a certain stage of development, because of the certainty that the cortical substance will offer the greatest resistance to removal at previous stages, and nuclear cataracts, permitting of some vision, are, as a rule, not operated on because of the uncertainty as to whether the transparent cortical substance will be

expelled or remain in the eye. I hope to show that for the cases of cortical cataract, of the most common occurrence, in which there was certainty of a difficulty so great as to deter operators, there are methods by which extraction, without preliminary or supplementary operations, may be performed with as high an average of success as if the cataracts had been allowed to pass through further stages of development, and that in the nuclear cataract a more rigid sifting and balancing of diagnostic points, an addition to our diagnostic resources, and improvement in operative methods may replace uncertainty by confidence and security, and warrant the surgeon in operating without delay.

Further, whilst I am most concerned with the common forms of cataract and their various stages, and surgeons generally will doubtless be likewise, I have had some experience of operations on uncommon forms which hardly ever attain full development, a record of which may raise the hope of the surgeon that he may undertake operation in like cases with fair prospect of success.

The Importance of the Solution of the Problem of Safe Early Operation.—What is involved in the problem of safely operating early will be better understood when we think of the incalculable advantage to the patients if the months and years of waiting and anxiety can be diminished,* if the too prevalent practice of allowing persons to become blind or nearly blind from double cataract before undertaking an operation can be banished, if the interruption of the work of life can be reduced to a short period, and if a large number can be

* I have only occasionally noted the period from the commencement of cataract till the performance of the operation. I chance to have a report of Dr. St. John Roosa in which that information is given in 97 cases. I find the average is within a small fraction of four years.

saved from poverty, dependence, and their too frequent attendants—demoralization and debasement—I hope to convince the reader that these advantages are within reach.

In entering upon a field of work which is practically unexplored, I shall take care to make this treatise a repertory of facts so arranged as to admit of easy reference, and by which the reader may not only form his own deduction in relation to the matter, but may test and judge the truth or falsehood of some current ideas and theories.

The Surgery of Cataract for some time Non-Progressive.—It must be admitted that the surgery of cataract, in contradistinction to surgery generally, has been for some time practically non-progressive. Indeed, the chief feature noticeable is that the profession has been largely occupied in discussing questions of a very minor character when estimated by results. For almost all ophthalmic surgeons operate on the same sort of cases with variations in method, and their results show a striking sameness. Under other circumstances such remarkable uniformity and good results might be evidence that further progress was hardly possible. The question will present another aspect when it is considered at what sacrifice—often ruin of health and worldly prospects—such similitude of results is attained.

When advance by the old road can hardly be expected with reason, common sense dictates that another way should be sought.

Circumstances limiting Range of Operation.—The circumstances limiting range of operation in times past were more numerous than those at the present time, and therefore surgeons now are in a more favourable

position than their predecessors. In the old days of the flap operation they were five—

(1.) The hazard from suppuration.

(2.) The danger of subsequent prolapse of the iris.

(3.) The uncertainty of diagnosis of consistence.

(4.) The want of safe and effective methods of removing sticky and transparent cortex.

(5.) The prolonged confinement and rigorous after-treatment.

The patient, whilst retaining vision of some little utility, naturally hesitated to face all the chances and inconveniences and to run the risk of losing what still remained to him, and the surgeon was deterred from operating except in the clearest cases, from the dread of leaving the patient worse than he found him.

Suppuration, which used to destroy a considerable percentage of the eyes operated on, is to all intents abolished. Large prolapse of iris, which led to the loss of many eyes and to prolonged after-treatment, can be almost always avoided by iridectomy; and the period of confinement to bed, amounting to many days, and very trying to old people, may be reduced to a day or two if the surgeon so wishes.

Now, the reasons for still restricting operations, as in the past, are really the 3rd and 4th, viz., the uncertainty of diagnosis of consistence, and the difficulty of removing sticky and transparent cortex, and to these two matters chief attention should be directed.

Efforts to Extend Range of Operations.—Several methods have been tried to overcome the difficulties arising from cortex which has not, or is supposed not to have, undergone such changes as to make its removal easy.

(1.) Removal of the lens in its capsule.

(2.) Artificial softening of the cortex by preliminary needle operation.

(3.) Forster's method of artificial maturation.

(4.) Immediate extraction with iridectomy, the capsule of the lens being opened peripherally.

(5.) Injection of a liquid inside the capsule of the lens, and the irrigation or washing out of cortical remains.

The first method—The removal of the lens in its capsule—has not, and for very good reasons, found much favour. Any operation which has for its basis the breaking up the vitreous humour, with more or less loss of that substance, and liability to evil consequences, sometimes imminent, sometimes remote—as, for example, intra-ocular hæmorrhage and detachment of the retina—has and should have no chance of general adoption. Besides, it is a very uncertain method of removing the majority of incomplete cataracts. This method is only adapted for very old sclerosed cataracts in which the zonule of Zinn is weakened, or in which it is ruptured from the shrinking of the lens and its capsule in the course of the affection, or accidentally during an operation.

The second method—Artificial softening of the cortex by preliminary needle operation—is only applicable to cortical cataract in persons relatively young. If applied at late periods of life it is attended with risks of a grave character—glaucoma, iritis, inflammatory thickening of the capsule, and sometimes actual condensation of the substance of the lens, necessitating secondary operations.

As to the third method—Forster's method of artificial maturation—those who practise it are not quite clear about the indications for it, and the bulk of evidence in its favour is not calculated to rouse great enthusiasm. The information given in reports I have seen is of little guidance; it is evidently of limited application. In a

large proportion of the cases trituration is ineffectual, and many of the cases recorded as proving its utility I judge from the history would have been easily operated on without it, and when most needed it is least useful. With one operator it failed in about 50 per cent. It is said to be liable to cause dislocation of the lens, iritis, and loss of vitreous humour, and convalescence is reported to be tedious from retention of the cortex. With large experience these objections may be minimised. The method has the great disadvantage of requiring two operations—first, preliminary iridectomy and trituration, and, second, extraction, and frequently a third operation for secondary cataract. Methods involving multiple operations are very objectionable, and I think very few patients with full knowledge would submit to such treatment.

The fourth method—Immediate extraction with iridectomy—is, in my opinion, preferable to any of the three preceding methods. It involves, however, nearly 50 per cent. of necessary secondary operations, and these operations are rightly not regarded with favour.

The fifth method—That by intra-capsular injection and irrigation—is dealt with in detail in this treatise.

Uncertainty of Diagnosis and Insufficient Surgical Resources.—It is strange that the operations by ordinary methods noted as having been performed on so-called unripe cataract have been usually done at the urgent and persistent solicitations of the patients. Although unexpected satisfactory results have been obtained, the experience has never had more than an individual influence, and never spread or grown or exercised any marked effect on the practice of the profession, and doubtless for the very cogent reason that there always has been, and there is now, uncertainty as to how transparent cortex would behave, and when difficulty did

occur there were no means of overcoming it. When an attempt was made to generalize from the fortunate result of isolated cases,* and to act on such a generalization, the results were so often disappointing as to lead to abandonment of the attempt.

But in cortical cataract in the incomplete stages, the risks of the ordinary operations were so well known, so certain, and so formidable in their character as to be deterrent.

---

* Sichel writes: "On peut opérer avec un entier succes des cataractes incomplètes, séniles et non compliquées, quand des circonstances particulières rendent ces opérations urgentes. Nous nous sommes trouvé plusieurs fois dans ce cas; nous n'en citerons qu'un fait. Une ouvrière, trieuse de laine, a perdu depuis long-temps la vision de l'oeil droit, affecté d'un staphylome de la cornée. Dans l'oeil gauche il se forme une cataracte lenticulaire dure, compliquée de congestion oculaire interne. Nous combattons victorieusement la complication, mais la cataracte ne fait aucun progrès reste stationnaire et incomplète, permettant à la malade de se conduire et de se livrer aux occupations du menage et a d'autres travaux grossiers, mais la mettant dans l'impossibilité absolute de continuer son métier; le triage des laines en effet ne peut se faire par le sens du toucher seul, sans l'aide d'une vision nette. Après un mois d'attente, la cataracte ne marchant point, la pauvre femme était sur le point d'epuiser ses faibles économies, et n'avait aucun moyen de subsistance ni aucun sécours; nous lui déclarâmes alors qu'elle pouvait être opérée avec toutes les chances d'un succes complet, mais qu'un accident imprévu survenant par suite de l'opération pourrait également la priver totalement de la vue; nous lui dîmes enfin que si elle se faisait opérer, elle jouait quitte ou double. Comme elle désirait ardemment se soumettre à toutes les chances, nous n'hesitâmes pas à accéder a ses voeux et a notre grande satisfaction, a notre clinique, elle vit bien, et la vision se fortifia si rapidement que trois semaines après cette femme reprit ses travaux ordinaires." —*Sichel. Traité de l'ophthalmie la cataracte et l'amaurose, 1837.*"

Critchett says: "More than eight years since, at Moorfields, Mr. Tweedy removed an immature cataract from a respectable artizan, who had to no slight extent forced his hand by declaring that, if no surgical aid could be afforded him, he must enter the workhouse and remain there till the eye was ready for an operation. Referring to this case in May, 1888, Mr. Tweedy writes: 'The extraction was uncomplicated and the lens left the capsule entire. Recovery was prompt, and a few weeks later, with suitable glasses, the patient could read "brilliant" type quite fluently. Since that operation I have rarely refused to extract a cataract, no matter how immature, whenever both eyes were so affected that the patient was unable to earn his livelihood.'"—*British Medical Journal*, 1889.

Critchett, at a meeting of the Ophthalmological Society of the United Kingdom on 21st June, 1890, in a discussion on "Immature Cataract," "spoke of seven or eight cases of which his experience consisted, which had been commenced under great compulsion, and proceeded with with great caution and some misgiving. Iritis had occurred in two, but no eye had been lost. During the last few years his success had quite equalled his expectations, and he thought that immature cataracts could be removed almost as well as mature ones. He was convinced that it was wiser to wait till the patient could no longer see to find his way about before operating."

Tweedy, at the same meeting, said "for more than nine years he had operated when necessity arose upon unripe cataracts" (referring to immature senile)—"that is, where both eyes were so affected that the patient was unable to follow his occupation."

For all practical purposes, then, either through uncertainty of diagnosis or insufficient surgical resources, or both, we stand pretty much where we stood a long time ago.

A Rooted Idea to be Discarded.—It will be found in this, as in other departments of surgery, that some ideas have dominated and still dominate surgical methods. The chief of these is that the easier an operation the better for ultimate result. Ease and expedition are certainly very desirable, but they are not everything, and they are not the most important in the present state of surgical knowledge. It was natural that surgeons, before the era of antiseptic and aseptic methods, and the still later era of local cocaine anæsthesia, should have been averse to prolonged manœuvres. But if ophthalmic surgery is to advance, if operations be undertaken on incomplete cataract, the guiding idea must be different from what has prevailed. For a slow operation, if perfectly performed, is not now to be feared; on the contrary, slowness may be essential to success. If the surgeon succeed in clearing out the lens completely, leaving a clean capsule, he need have no fear of the consequences, though he may not accomplish it quickly. Slow and deliberate operations on incomplete cataract would only bring the surgery of cataract on a line with other surgical work. Take, for example, abdominal operations. Nobody thinks of quick operation, but, on the contrary, of minute attention to every detail. The peritoneum, contrary to even ideas of twenty-five years ago, may be handled, washed, flushed, and exposed for a long time almost with impunity. So again the quick and imperfect operation of lithotrity was nearly the ruin of the method, but now the slow and deliberate removal of all fragments at one prolonged sitting is shown to be the safe and certain method. So it is with cataract.

CHAPTER II.

CLASSIFICATION.

Objections to Various Classifications.—When an examination is made of various classifications, it will be apparent that they are, for present scientific purposes, extremely faulty. For we find a curious mixture of terms derived from the most varied sources, some from empiric knowledge, some from objective examination, some from ætiology, some from age, some from inference, some from fact, some from theory, and some used with different meanings by different surgeons of different times, and even of the same time. A consistent and uniform plan of classification is a pressing necessity for the progress of ophthalmic science.

Essentials of a Good Classification—Should be Objective and Not Inferential.—A classification should, so far as possible, be made by what we can see and not by what we infer. In other words, it should be objective, and not inferential. Judging from this standpoint, the real value of certain terms can be estimated, and a fitting place assigned to them.

Objections to Various Terms in Common Use.—The terms soft, hard, liquid, sticky, are, before operation, all inferential, and the inference may be right or wrong, according to the experience and ability of the surgeon, and therefore uncertain, but after operation they represent an ascertained fact, and may be correctly used to represent the knowledge obtained.

So the terms "ripe" and "unripe," having reference to suitability for operation, are also inferential, and vary according to the times and methods in vogue, and to the knowledge and accuracy of the writer. It is a fact which cannot be disputed that there is so much confusion about ripe and unripe cataract, that a surgeon taking up reports of operations on so-called unripe cataract gets little information as to what, in the opinion of the operator, constituted an unripe cataract.

Llandolt's Proposition. — The proposition of Llandolt to get rid of confusion by substituting the term "operable" for the general term "ripe" gets over no difficulty, and is liable to the same objection as urged against "ripe," as representing only an opinion, and the opinion would vary according to the views of the various surgeons. And how they would vary, Llandolt himself proves in the paper in which he puts forward the proposition. This is so striking that I subjoin a summary of his statement.* There is a wide range between the stage in which "vision is sensibly altered" and "total opacity," and I fear that a surgeon seeking information

---

* Llandolt, in his article on "L'opération de la cataracte de nos jours," writes as follows:—

"Déjà avant de procéder à l'opération on ne semble même pas d'accord sur son indication. Et entre ceux qui comme Gayet, évitent 'autant que possible d'opérer des cataractes non mûres' ou qui trouvent, avec Sprague que c'est 'bad surgery to extract immature cataracts' et ceux auxquels l'opération de cataractes non mûres donne d'aussi bons résultats que l'extraction de cataractes mûres (Fuchs, Hirschberg, Schweigger et bien d'autres) toutes les opinions possibles se trouvent représentées et dignement représentées."

After speaking of the different practice of different surgeons, he says:—

"En réfléchissant un peu, on trouvera sans peine qu'il y a non pas une seule, mais un assez grand nombre de raisons qui expliquent cette diversité de principes touchant le mode d'opération de la cataracte.

"En premier lieu, elle peut tenir a *un manque de clarté* dans certains définitions. Tel est sûrement le cas pour ce qui concerne la maturité de la cataracte.

"Pendant longtemps on a considéré une cataracte comme mûre, c'est à dire bonne à opérer, seulement lorsque le cristallin était opaque dans toute son épaisseur.

"L'expérience a prouvé que bien des cataractes sont parfaitement opérables tout

would hardly find guidance in the multitude of counsellors. From the general way in which the statement is made in relation to the practice of these different operators, it would probably be found on enquiry that operations such as mentioned were restricted to the nuclear cataract. There is little doubt but that almost all ophthalmic surgeons in their habitual practice required for operation total opacity. But of one thing I have no doubt whatever that if a surgeon were tempted to do operations as a matter of course on ordinary incomplete cortical cataract with such an amount of vision as seeing from one foot up to three and a-half metres, without

---

en laissant encore un bon passage à la lumière. En remplacant le terme 'mûre' qui pret à l'équivoque par celui d' 'opérable' on rallie déjà la majorité des confrères."

The following is a summary of the indications of operability according to the views of different surgeons, as extracted from Llandolt's paper :—

Degree of opacity ...	$\frac{1}{3}$ of lens opaque	Barraquer.
	Total opacity of at least the external layers	Chadin.
	Total opacity	Bagnores, Foucher, Manz Panas, Schmidt-Rimpler, Waldhauer.
Degree of vacuity of vision.	As soon as the vision is sensibly altered	Mme. Rosa Kerschbaumer.
	When the patient can no longer count fingers at $3\frac{1}{2}$ metres	Manolescu.
	At 1 metre	Bribosia.
	At 4 feet	Jnouye.
	At 1 foot	Argyll Robertson.
	When he cannot count fingers.	Juler.
	When he can no longer read Jaeger No. 16	Critchett.
	When he can no longer read.	Bader.
Age	Past 56	Mooren.
	60	Deutschmann.
	50	Hirschberg.
	50 to 60	Schweigger.

Llandolt expresses his own views as follows :—" Un viellard peut être porteur d'une cataracte qui l'empêche absolument de lire et nous l'engagerons néanmoins à reculer l'époque de l'opération, si un examen répété nous a démontré que sa cataracte fait encore des progrès. Par la raison inverse nous n'hésiterons pas à tenter sur une personne bien plus jeune, l'extraction d'un cristallin bien plus transparent si nous avons pu nous convaincre de son état stationnaire, voire même régressif."—*Archives d'ophthalmologie*, 1892.

resorting to some special measures, his illusions would soon be dispelled.

Vagueness even in Use of Terms supposed to represent Facts.—When we examine some terms supposed to represent facts easily verified, and about which one would suppose there would be no doubt, we are confronted with the all-pervading vagueness. For example: Cataracts have been described as congenital, juvenile, and senile. As to the existence of certain cataracts at birth all are agreed, but there are cases of cataract which may not be observed for many years after birth, and which are yet classed as congenital. In this case the term does not, as it seems, represent even a fact, but only an opinion. I do not pass beyond the bounds of fair criticism when I say that various observers who have given much attention to zonular cataract are not agreed as to whether it is congenital or appears some time after birth. The term "congenital," I think, should be used more carefully.

The term "senile" is specially abused. In some works it is impossible to find what the writer means by senile; in others it would appear that cataracts in persons from 30 years upwards are senile; whilst in others from 40 or 45 years is the age intended. Whatever way the term may be regarded, the absurdity is evident, for in a great many of the cases so classed there is no evidence of either local or general senility. If the presence of a nucleus at about the age of 30 regulates the fixing of that age as the beginning of the senile period for cataract, we have the anomalous position of regarding a structure of a perfectly normal and physiological character as an evidence of decay. Besides, the span of years from 30 or 40 to 80 or 90 includes persons in the prime of life and the most extreme old age, and so different in other respects that between some of them there is little in common but life.

The word "senile," as applied in many cases, is false in fact and contrary to the common meaning of the term, and besides vulgarizes a theory as to the ætiology of cataract which in many cases is erroneous and mischievous. If the surgeon regard cataract as an evidence of senile decay, local or general, he becomes an apathetic observer waiting for the gradual and inevitable loss of vision. If, on the contrary, he is impressed with the idea, as he ought to be, that cataract of the cortical forms is very often a disease, he may look forward with hope to the discovery of some method which will so alter the nutrition of the eye as to cure or arrest the affection in its early stages.*

What we do know points to such a possibility. It would be obviously unwise to think that cataract can never be cured except by operation, for many things in surgery at one time unhoped for or reckoned impossible have been accomplished.

So far as age is concerned, there are just three landmarks which should be remembered, viz., birth, 30 years or thereabouts (existence of nucleus), 60 or thereabouts (loss of accommodation).

In the present stage of this question all ends regarding the ætiological value of age as a factor can be attained by a simple note of the age of each patient.

Cataracts Adapted for Main Classification on Structural Basis. — It will be evident, from the examination of the terms already mentioned, that it would be a task beyond human power to construct a

* Brailey points out, in his paper "On some points in the Development of Cataract," that nuclear cataract develops slowly and without irritation, whilst the cortical is, in at least two-thirds of the cases, attended with distress, and he hazards the opinion "that whereas the senile *nuclear* cataract is primarily a true degenerative senile change, the cortical cataract is not of this nature, but is a disease, the course of which may be altered by hygienic measures, and probably also by the action of other remedial means."—*Transactions of the Ophthalmological Society of the United Kingdom*, 1891.

scientific classification by their use. Happily, however, it is possible to evolve some order out of this state of chaos.

The terms to which I have referred and all other terms open to a like objection should be removed from the main classification, and only used, when used at all, in their proper sense as subordinate, inferential, or descriptive. Cataracts, from their position, being open to inspection and presenting so many distinct features of opacities in colour, extent, position, and shape, are specially adapted for structural classification.

This applies likewise to different stages of the various forms of cataract, especially the cortical, from the incipient stage to complete development. The surgeon who operates only on complete cataract is chiefly concerned about recognising the signs of that completeness, and in cataracts before that stage his immediate duty of advising delay entails no responsibility, and his diagnosis of "unripeness" satisfies his practical necessities. But a surgeon dealing with cataracts between the incipient and complete stage, if he desire to make intelligible the character of his work, is obliged to give minute description, and must for that purpose have a suitable classification. The material, too, is ready at hand, for by a better arrangement, by the excision of terms not proper to my purpose, and by precise definition, some old structural classifications too elaborate for the operative knowledge of the period, and rather of academic than practical interest, may now be adapted to meet the necessities of the present.

I therefore adopt for the main classification the structural basis—

Cataracts also to be Considered Functionally and Surgically.—It is necessary also to note the functional or physiological change induced by the

opacities in uncomplicated cataract which can be accurately measured, and lastly the inference to be drawn as to whether an operation should be performed, and in what manner.

In other words, cataracts may be considered from three different points of view—1st, Anatomical or Structural; 2nd, Functional or Physiological; 3rd, Surgical.

Cataracts considered Structurally.—From the structural or anatomical point of view, having regard to the part or parts affected by the opacity, cataracts may be classified as—

CAPSULAR,
LENTICULAR, and
CAPSULO-LENTICULAR.

The capsular cataracts are, at this stage of our enquiry, sufficiently described by the name, but the lenticular cataracts occurring in persons who have attained the age of 30 years or thereabouts, at which the nucleus is distinguishable, may be sub-divided into—

CORTICAL,
NUCLEAR, and
NUCLEO-CORTICAL,

according to the part or parts chiefly involved.

It must be remembered, however, that the mere presence of a nucleus does not constitute a nuclear cataract, for a perfectly opaque cortex may contain a transparent nucleus; and besides, whether a nucleus is transparent or opaque is of no importance when a cataract is to be extracted. The presence of a nucleus is only an incident regulating size of section; and if one wished to designate a cortical cataract occurring in a person above the age mentioned with great accuracy he would do so by describing it as a cortical cataract with a nucleus.

Cataracts, in regard to Stage of Development, Complete and Incomplete.—But cataracts may not only be described in the general way mentioned according to the part affected, but also as regards the stage of development. From this point of view they may be described as—

(1) Complete.
(2) Incomplete.

By complete lenticular cataract is meant one in which the opacity has affected the whole of the lens, or at least the superficial layers, and in which the cortical opacity has become *equal and uniform.*

Incomplete cataract, on the contrary, of whatever description, and in patients of whatever age, is one in which the opacity may be partial—in other words, has *not* become *equal and uniform.* By this definition all cataracts which are striated, flaky, cloudy, segmented, dotted, lamellar, or partially opaque, are incomplete.

An uncomplicated capsular cataract never becomes complete, as it never has been found to affect the whole of the capsule.

Sharp Distinction between Cortical and Nuclear Cataracts.—It is necessary to draw a sharp distinction between cortical and nuclear cataract. The opacification is quite different in the *typical* cases of the two forms. In the former it is so easily observed by marked colour changes in the cortex that the identification is readily made, and the progress of the affection can be followed and described with accuracy from its inception till its completion. Besides, as a general rule the consistence of the lens can be diagnosed in the various stages with average certainty. In the latter the opacification proceeds from the centre towards the surface of the lens, and the opacity does not present, sometimes for a con-

siderable period, characters visible to the naked eye of such a certain and easily-measured character as in the cortical forms. Besides, as a general rule, in contradistinction to cortical cataract, the consistence of the lens cannot in its stages before complete development be accurately diagnosed from structural appearance. Indeed, before the attainment of full structural development it would be difficult to find a number of surgeons agree that the lens had reached the condition required for easy operation. The diagnosis of hardness is really a matter difficult of inference. To avoid, therefore, confusing uncertain with certain, I make the signification of complete nuclear cataract correspond with that of complete cortical in relation to structure, *i.e.*, equal and uniform opacity, and in my description of incomplete nuclear cataract state the degree in which the alteration of structure can be observed, and how much the function of vision has been impaired without any attempt at closer definition.

Cataracts considered Functionally.—The degree of the impairment of vision caused by the opacities, whether progressive or not, is a ready measure of the necessities of the patient, and almost always is thought of in relation to the expedience of undertaking surgical treatment. For purposes of comparison, cataracts may be regarded from the view of the loss of function as—

FUNCTIONALLY COMPLETE, and
FUNCTIONALLY INCOMPLETE.

A functionally complete cataract is one in which the patient cannot distinguish objects such as the fingers with his back turned to the light.

A functionally incomplete cataract is one in which a varying amount of vision, from a slight diminution to counting fingers, remains.

Structural Completeness and Incompleteness not Equivalent to Functional.—A lenticular cataract structurally complete, whether cortical or nuclear, is likewise functionally complete. A lenticular cortical cataract, however, may be incomplete structurally, and yet may be complete functionally. For example, a striated and flaky cataract is incomplete structurally, *i.e.*, has not attained uniform opacity, and yet may prevent the patient counting fingers.

Cataracts considered Surgically — Surgical Completeness and Incompleteness.—The character of cataract structurally and functionally can be ascertained, but the observations made are meant to lead up to an inference—whether such changes have taken place in the lens as to admit of its easy removal by ordinary methods on rupture of the capsule.

Those found to be easily extracted on rupture of the capsule are surgically complete.

Those found to be very difficult or impossible to extract are surgically incomplete.

Those found in their behaviour to be doubtful cannot be classed with the surgically complete or incomplete.

The pure nuclear form may be structurally and functionally incomplete in various degrees, and yet may be found on operation to be surgically complete, but the diagnosis of the condition of the cortex is a doubtful matter, and such cases would come under the class of surgically doubtful.

When cataracts which have attained structural completeness are allowed to pass beyond that stage, there are conditions of the most varied character which are not capable of any general classification, but must be dealt with individually.

STRUCTURAL CLASSIFICATION.

As already stated cataracts may be lenticular and capsular; and lenticular may be cortical, nuclear, or nucleo-cortical. In lenticular cataract the opacity may either affect the whole of the lens or a part, and may be found at any age from birth to advanced years. Before the period at which the nucleus is found the whole of the lens commonly undergoes structural change. After that period the nucleus usually remains distinct, but the mere presence of the nucleus, as I have said, is an incident, and does not indicate that the cataract is nuclear.

Cortical Cataract.—The changes in the cortex, as the name implies, are either the sole or the predominant changes. There is a common form, and several other forms of an uncommon or special character.

Common Form.—In the immense majority of cases it begins with striae in the cortex, and passes through certain stages which are important clinically.

1st Stage—Striae greyish white, more or less broad and shining, appearing at or near the anterior or posterior surface of the lens or both, assuming geometrical forms of a triangular character with the base towards the equator of the lens, and the apices towards the poles of the lens, and permitting the fundus to be seen in a greater or less degree.

2nd Stage—The extension of the striae over the whole of the surface, interrupted by transparent facets and flaky patches, so that no details of the fundus can be seen.

3rd Stage—Striation over whole of surface. Lens often segmented. Lens swollen as shewn by advance

of iris towards the posterior surface of the cornea, and reduction of the depth of the anterior chamber.

4th Stage—Disappearance of striae and assumption of uniform opacity. The anterior chamber becomes deeper from diminution of the swelling of the lens.

The cases which have reached the fourth stage are those regarded as "ripe" or easy to operate on.

Uncommon and Special Forms in their earlier or incomplete stage—

(1) Occasionally a diffuse opacity of a hazy bluish semi-transparent character appearing in the cortex without any striation or want of superficial uniformity, and in which the vision for large objects is lost. This may be taken as an exception to my general definition of completeness structurally. It is liable to be mistaken for a lens in which the cortex has been broken down, but on operation is found to have pretty much the same consistence as the perfectly transparent lens. At a later stage the cortex loses its semi-transparent character, and the cataract in its ultimate development is just the same as the common form of cortical.

(2) Small white punctated or dotted opacities, with some fine striae quite superficial and close to the capsule, making little progress in very many years, occurring usually in myopic persons from 40 to 60 years of age. The fundus more or less obscured can be seen for a long time.

(3) White opacities, like bars of varying size, close to capsule with intervening clear spaces—very slow in progress and very rare.

(4) A central opacity at posterior pole of lens, more or less rounded, but with margin somewhat irregular, and usually a few narrow opacities diverging, occurring

as a rule in persons with deep-seated affection. Very slow in progress. Commonly known as posterior polar.

(5) A stellate opacity of the posterior cortex, quite close to the capsule, usually very slow in progress, but extending in time to peripheral and anterior cortical layers.

(6) An opacity of varying degree from a slight haze to a well-marked whiteness affecting deeper layers of the cortex, surrounding the nucleus, and enclosed by transparent superficial cortical layers, usually permitting of considerable vision, often non-progressive. This form of cataract, which is either found at birth or discovered within the first few years of life, and commonly known as "zonular" or "lamellar" cataract, furnishes occasionally examples of an exception to the general rule of the absence of a recognizable nucleus before about 30 years of age. This cataract may be found to be without recognizable nucleus, or to have a sclerosed nucleus.

(7) Small punctate opacities, sometimes not easily recognized, disseminated through different layers of the cortex, interfering little if at all with vision, and probably never requiring operation.

Nuclear.—A central opacity of the lens of varying colour—greyish, greyish yellow, or brown, whilst the superficial cortex is at first transparent and without any striation. The opacity gradually extends towards the surface until the lens may become quite opaque. If the opacification is accompanied by a flattening of the anterior surface of the lens, deepening of the anterior chamber, it is an indication of a sclerosis or shrinking of the lens, especially if the impairment of vision has been going on for a long time. For a variable period the red of the fundus, and often the optic disc and vessels, may be dimly seen, and the patient may be able to make his way about for years.

Nucleo-Cortical. — The cataract has the same features as to the beginning and progress of the affection as the pure nuclear form, but there is some striation of the superficial cortex, usually of a fine character, slow in progress. At the end in some cases the lens comes to assume quickly a ground-glass appearance.

Capsular is usually seen as an opacity apparently of the capsule in the centre (therefore called anterior polar) of a dense fibrous or white character, commonly small in area, irregular in shape, showing no distinctively linear or triangular formation more prominent than the surrounding lens, and not tending to extend. What is known as "Pyramidal" is only a form of the "anterior polar" in which the opacity forms a conical projection into the anterior chamber.

Changes after Complete Structural Development of Lenticular Cataract.—The various forms of cataract, or some of them, take on certain changes if not submitted to operation at or before the stage of structural completeness—

(1.) The whole lens may become, in young persons, of a uniform bluish white or milky appearance, or may have that character even at birth. This indicates fluidity. If the patient have been at rest, solid particles may subside and will take the most dependent position. In such cases there may be a layer of fluid perfectly transparent.

(2.) Glistening particles indicative of the presence of chloresterin may be observed to float about or to be attached to the inside of the capsule, or the whole of the lens may appear of a dirty grumous colour, and of unequal opacity.

(3.) The whole lens may appear as a flat plaque,

white and irregular on the surface, or even chalky in appearance, indicating the absorption of a part of the lens substance, and perhaps a thickening of the capsule itself. A nucleus may be indicated by a whitish-yellow colour.

(4.) When a yellow or brownish oval structure appears and disappears in the lens according to the position of the head of the patient, it indicates that the cortical substance has become fluid, and that there is a firm nucleus floating about in the liquefied cortex. (Morgagnian cataract.)

(5.) The anterior capsule may become secondarily involved both in cortical and nuclear cataract, and the changes reveal themselves by dense whitish opacity of varying shape, quite superficial, but never following any regular structural formation, and often elevated slightly above the rest of the surface. These forms are commonly known as capsulo-lenticular.

Secondary Cataract (after operations for cataract) may appear under three different aspects—

(1.) As a fine membrane, gauze-like, or presenting folds, and sometimes only observable by oblique illumination, or direct ophthalmoscopic examination.

(2.) As a membrane, dotted or spotted with opacities of various degrees and character, thickened at parts and thin at others.

(3.) As a dense and extensive opacity of the capsule with iritic adhesions of variable degree.

Traumatic Cataract from the very varied circumstances must be treated as a separate class. It does not admit of structural classification. Some observations will be found under the heading of "Operations on Traumatic Cataract."

Complicated Cataract.—Whilst all cataracts are owing to some disturbance of nutrition, it is only occasionally that the cause of disturbance in uncomplicated cataracts admits of easy demonstration. But there are other cataracts which are so obviously associated with well recognized local diseases that the cataracts are called "complicated" cataracts. It would in such cases be advantageous to use a nomenclature emphasizing the primary disease, the mere physical characters of the cataract being of relatively little importance.

For example, we would have—

Iritis with cataract.
Irido-choroiditis with cataract.
Detachment of the retina with cataract.
Intra-ocular tumour with cataract.
Retinitis pigmentosa with cataract.
Retino-choroiditis with cataract.
Glaucoma with cataract.

Sometimes these affections are so manifest that there can be no difficulty in determining the disease to which the cataract is owing by ocular inspection, but at other times the real nature of the affection is only determined by the ophthalmoscope, the light test, and the field of vision.

CHAPTER III.

EXAMINATION OF THE PATIENT AND THE RESULTING INFERENCES.

It is now well that I should describe in detail the manner of proceeding with the examination, objective and subjective, and point out the indications thereby obtained.

OBJECTIVE EXAMINATION.

The classification already given shows the various conditions to be looked for on objective examination.

For such examination we have—

(1.) Simple ocular inspection.
(2.) Oblique illumination.
(3.) Ophthalmoscopic examination.
(4.) Palpation of the globe to estimate tension.

Simple Inspection can readily detect—

(*a*) All forms of cataract affecting the anterior layers of the cortex in the pupillary area, also changes from change of position, as appearance and disappearance of nucleus in Morgagnian cataract, permanent change of position of nucleus when cortex has softened, become fluid, and been subsequently condensed.

(*b*) The marked forms of zonular cataract with the dark ring round the opacity.

(*c*) Capsular cataracts—the superficial appearance and the want of any regular or geometric form, and the projection in front of the rest of the lens surface.

(*d*) The transparence of cortical substance by the depth of the opacity behind the pupil.

(*e*) Opacities of the posterior cortex when the centre of the lens and the anterior cortex are pretty clear.

(*f*) The reaction of the iris to light when the other eye is covered.

(*g*) The depth of the anterior chamber, and whether the anterior surface of the lens is more convex or flatter than usual, also whether the anterior plane of the lens is normal. An unequal depth of the anterior chamber with iris normally moveable may indicate partial dislocation of the lens.

Oblique Illumination gives the same information as simple inspection, and shows some points to more advantage.

By it, the observer, standing in front of the patient, may see a shadow thrown by the iris on the lens which indicates one of two conditions—(*a*) the transparence of cortical layers of the lens, or (*b*) a space between the iris and the anterior surface of a lens opaque, but shrivelled or dislocated.

This method sometimes shows a central lens opacity which ophthalmoscopic examination proves to be only apparent.

Ophthalmoscopic Examination.—By the reflection of the light from a concave ophthalmoscopic mirror, held in different positions, and at different angles on the pupillary area, whilst the surgeon regards the eye as in simple ocular inspection, the same appearances are found as by the first two methods.

We understand, however, by Ophthalmoscopic Examination the use of transmitted light, as in ordinary

ophthalmoscopic examination of the fundus to ascertain whether the lens is so pervious to light as to admit of seeing the fundus in any degree.

There are many cases in which the appearances on ocular inspection so obviously indicate that it would be impossible to see through or around the opacity that the surgeon need not expect anything from this method, as for example in—

(*a*) Cortical cataracts, in which an opacity of uniform character occupies the whole of the pupillary area, coming quite close to the iris (*i.e.*, in which the iris throws no shadow).

(*b*) Nucleo-cortical cataracts, where the cortex is opaque, ground-glass, etc.

(*c*) Various cataracts in the stages sequential to structural completeness.

Excluding cases of such sort, ophthalmoscopic examination may shew either that no red of the fundus is visible, or that the red of the fundus, with or without details, may be seen.

When there is a want of red reflex it is then necessary to inquire with what form of cataract this sign is associated, assuming that other causes have been excluded. The most important cases in which it may be wanting when the pupil is not dilated are—

(*a*) Even in incipient nuclear cataract, and of course during its further development.

(*b*) In zonular cataract.

(*c*) In cortical cataracts even far from complete structural development, but in which there is no direct clear path for rays through the lens within the area of the pupil.

The dilatation of the pupil is necessary to further pursue the investigation, and for this purpose, in case

immediate operation may be probably determined on, it is well to apply a drop of a solution of four grains of homatropine to the oz. of water, the effect of which passes off within twenty-four hours. Then varying conditions in the above cases in which there was no red reflex from the undilated pupil may be found.

(*a*) The opacity in the incipient nuclear cataract being due to a slight central cloudiness, now the fundus with details can be more or less seen. In cases more advanced the fundus is obscured to a variable degree according to the density and colour of the lens, and, finally, in the most advanced no red of fundus can be seen.

(*b*) In the zonular the fundus can be seen quite clearly peripherally. Should there be an opaque nucleus, as sometimes occurs in zonular cataract, the densest opacity is in the centre ; but if the centre of the lens is clear, as is usually the case, the peripheral part of the opacity is the more dense.

(*c*) In incompletely developed cortical cataract, when there are clear spaces right through the lens at any part of the dilated pupil, the red of the fundus, or the fundus with some details, may be seen, the opacities, when of notable size, form, and density, standing out dark on a red back ground ; but where the opacities, though partial and limited, do not admit of rays so passing, no red of the fundus can be seen, just the same as if opacification were complete and uniform.

It is necessary to remark that the density of an opacity, as observed by oblique and transmitted light,

does not entirely correspond, as an opacity of a very marked kind by oblique light may be found transparent to some extent by transmitted light.

As will be seen, quite erroneous notions are commonly entertained as to the significance of seeing or not seeing the red of the fundus in relation to the operation, for seeing it in nuclear cataract, with a dilated pupil, is no indication of a difficult operation, but is of a doubtful one, and not seeing it in certain stages of cortical cataract is no indication of an easy one.

A red reflex seen in an eye when the pupil is not dilated always indicates that the cataract, if cataract exists, is in a very incipient stage. In all cases when the area of the pupil is not obviously involved the periphery of the lens should be examined by directing the rays peripherally. In this way striæ may be found behind the iris. Particular attention should be directed to the inner and lower segment of the lens.

The examiner should be careful not to attach any importance to a very narrow fringe of opacities all round the periphery of the lens.

In addition, the use of a mydriatic may be required to detect adhesions of the iris in cases where the motion of the pupils is not free enough to put beyond question the existence of adhesions. It may be noted that sometimes with considerable iritic motion there may be adhesions, and the surgeon should take care to be informed beforehand of their existence, as they may put him on his guard against difficulties in performance of the operation from undue resistance of the capsule, although not obviously altered, and abnormal coherence of the lens substance, not to speak of the indication for the performance of a large iridectomy.

Examination in Secondary Cataract.—When vision, after operations for cataract, is not so satisfactory

as it ought to be, the examination of the pupillary area must be made. It will be found that opacities which by oblique illumination are with difficulty perceived cause considerable disturbance of vision, supposed to be because of wrinkling; whilst others easily seen, and regarded as likely to be very detrimental to vision, impede it slightly. In such cases operative interference is more dictated by visual acuity than by ophthalmoscopic examination.

SUBJECTIVE EXAMINATION.

The subjective examination embraces the following matters :—

(1.) The degree of vision.
(2.) The amount of perception of light.
(3.) Examination of phosphenes.
(4.) The manner of onset.
(5.) The age of the patient.
(6.) The age of the cataract.
(7.) General history and condition.
(8.) The patient's own story.

The Degree of Vision. — The surgeon should always, for his own satisfaction, note the degree of vision remaining, but no general rule can be tabulated as to the advisability or non-advisability of operating, or as to the ease or difficulty of the operation on this ground alone. For, as may be seen further on, a cortical cataract so far developed as to prevent a person going about or counting fingers may be very difficult to extract, whilst a nuclear cataract which does not hinder the patient from going about freely or counting the fingers at many feet may be easily extracted.

The Amount of Light Perception.—To determine the degree of integrity of the retina, optic nerve, and

visual centres in cases of cataract structurally or functionally complete, the light test is indispensable. It is used for two purposes—

1st. To test the central sensibility, and

2nd. The peripheral sensibility or field of vision.

Both these may be usually ascertained simply by a taper. When a patient with a completely-developed cataract (the eye not under examination being covered) points instantly to the light of a taper in different directions at 15 or 20 feet, there is no difficulty in deciding that the nervous structures are so sound as to warrant operation. Not only the distance at which the light is perceived, but the quickness of the response of the patient, may tell of an acute sensibility. But quite equal retinal integrity may be found often without such distant vision or such readiness of perception.

As this test is commonly described, one would imagine that it is solely a test of the sensibility of the retina, and the surgeon is taught that he can indicate the sensibility fractionally according to the distance at which the light is seen, just as he would state the acuity of vision by the distance at which test types can be read.

For example :—If seeing the light of a taper at, say, 5 metres is normal (Graefe), then at 4 metres it is $^4/_5$, or at 3 metres it is $^3/_5$. This is erroneous. The seeing of the light at a certain distance depends in ordinary cases chiefly on two considerations—(1st) on the integrity of the nervous structures, and (2nd) on the character of the lens opacity. It will be evident, on a little reflection, that it is not a measure of the sensibility of the retina alone, but is largely a measure of the degree or sort of opacity of the lens. In the use of the taper in cases in which there may be a doubt, the surgeon requires to take care that the light of the ophthalmoscopic lamp be so lowered that it will not interfere with the distant

perception of the test light, and that there be no large white or bright object or other light near the taper. A nurse's white apron may lead the observer astray by causing an apparent false projection.

In a considerable number of cases of double cataract there may be such a difference in sensibility to the light test in the two eyes as to lead the surgeon to believe that there may be some complication in one eye, and yet after operation the results in the two eyes are practically the same.

Sudden Diminution of Light Perception in Affections of Vitreous.—Not only does the degree of light perception depend on the character of the opacity of the lens, but on the condition of the vitreous humour. For an obstruction to the passage of the rays of light in that medium affects the perception of light, and it is a nice problem to apportion the total defect of perception between the retina, the cataract, and the vitreous.

The following case is an apt illustration :—

H. C., aged 20, was under my care in 1895 for an injury to both eyes by a dynamite explosion in stone quarrying. There was a traumatic cataract with a foreign body contained and thickened capsule. I operated on him with restoration of vision sufficient to enable him to count fingers at ten feet, and to go about alone. He came back to me stating that his vision had recently become much impaired, and I found that the thickening and opacity which I had previously noted had extended over the whole pupil, and I admitted him to hospital for operation. He could move about with some difficulty. When I came to perform the operation he reported that when he was out walking the previous day he suddenly became blind. I found that he could not see the taper light at more than two feet, and his projection was very unsatisfactory. His answers on examination of phosphenes were unreliable, and his description of the sudden loss of vision did not afford

much guidance. After about three months the perception of light at 20 feet and at various angles was acute. I resolved to do an operation on the false membranes, but on cutting through a straw-coloured watery fluid escaped, and it was impossible to excise the false membranes from condition of the globe, and the parchment-like character of the membranes. The case is of interest as shewing in a remarkable way how in an eye so thoroughly disorganized a sign usually considered as *per se* forbidding an operation completely disappeared.

The differential diagnosis is between hæmorrhage into the vitreous and detachment of the retina. The suddenness of the loss and the ultimate recovery seem to point to the former.

Temporary Diminution of Light Perception.—It is the common and well-founded opinion of surgeons that in adults even prolonged disuse of the eyes from cataract does not permanently impair the retinal sensibility or the visual centres to a material extent. But that there is at times a blunted perception of light of a temporary character I have no doubt. Should the surgeon not be aware of the possibility of such an occurrence he is liable to give an unfavourable opinion, and refuse to operate in a case in which the prospects of success are really good. Under such circumstances the patient may be satisfied with the opinion and remain without operation, or he may consult another surgeon under more favourable conditions and have the operation performed. The first surgeon may be the subject of unmerited reflection on his capacity, and the second may get credit for special skill to which he is in no sense entitled.

The following are notes of a case of a most marked character—

I. H., male, aged 57, came to hospital on account of loss of vision in his right eye on 30th March, 1896. I found a

cortical cataract with cortex white and pretty uniform in character. The field of vision for the taper was bad, and his central vision was only two feet. He was a cool, intelligent man, and therefore I could not consider his defect in light perception as merely apparent and owing to nervousness. Indeed he ridiculed the idea of nervousness. I examined him again on 9th April with the same result as at first, and was about to dismiss him as unfit for operation. The cataract in every other respect seemed good for operation, and there being an entire absence of other symptoms, and of facts in the history of the case which would lead one to believe in retinal detachment or other complication, it occured to me to prolong the testing for a short time, in fact put him through a sort of training in light perception. I did so for about ten minutes, and I had the satisfaction of finding that the perception of the light was so far restored that he could point to the light in different directions at eight or ten feet. I operated on the same day, and was pleased to find that immediately after the extraction he counted fingers readily, shewing at once how misleading were his first answers, and how narrowly I escaped a great but pardonable blunder. He progressed favourably and $V = \frac{1}{3}$.

The following case is remarkable for the extent of the diminution of light perception, its long continuance, and final disappearance :—

J. B., aged 51 years, caretaker of a farm, came to me in June, 1897, with a fully-developed cortical cataract in the left eye, and a commencing cataract in the right ($V. = \frac{20}{200}$). On using the taper light I found he could not see it with the left eye more than a couple of feet, and the field was very unsatisfactory. Examination of the phosphenes gave no guidance. I examined him several times, but without any improvement in his responses. I kept him in hospital for a number of days, and, with the view of stimulating the retina, the nurse put him through a training with the light several times daily for a few minutes at a time. There was no improvement. I made inquiries into the whole history of his affection. The vision began to fail four years previously, and especially in the other eye. Two years ago, during the night, a severe pain started in the left eye-ball, the brow, and temple, but went away the same night. When he got up he found he could not see his hand. There was no indication, on inspection of the eye, of what had occurred at the time in question. I refused to operate on the

left eye, and sent him home, to return when the right eye failed further. Thinking I had only one eye to operate on, I considered it expedient to wait till the cataract was functionally complete. He came back in November, the right eye having failed, so that he could not go about. At this time I was surprised to find that with the left eye, on which I had refused to operate in June, he could see the taper light at eight to ten feet, but not briskly. I cannot give any explanation, but I record the fact.

The cataract in the left eye had passed the stage of complete structural development. I operated on the eye; the course was normal, and V. = $\frac{20}{60}$.

Whatever the explanation of the diminution of the perception of light may be, it is clear that the surgeon would act prudently in case of such apparent diminution in an eye with all the external evidence of being good to operate on, not to dismiss such patients as unfit for operation without subjecting them to more than one careful examination.

Examination of Phosphenes.—This test is unnecessary except in cases of doubt. Even when applied, owing to want of trained faculty of observation of the patient, it often gives very little guidance. It is only, therefore, of very limited utility. Its chief use is in determining whether in case of very defective central or peripheral sensibility to the light test, or both, the defective sensibility may be owing to effusion of blood in the vitreous humour, or, perhaps, to the presence of a foreign body. Acute perception of phosphenes, with very defective light perception, usually negatives retinal defect.

Manner of Onset.—Cataract is almost always gradual in its progress, but occasionally a history of what tends to a belief in a very quick onset is given. A history of a slight general dimness gradually and slowly advancing, with a blank in every other respect, is favourable, whilst a sudden blindness is the reverse. This opinion must, however, be qualified. Many years

ago I saw a patient with double cataract fully matured. His history was remarkable. He was a farmer. One day when engaged in ploughing his vision so suddenly failed that he not only had to cease ploughing, but he could not go home, and was obliged to stay in the field till his friends came to seek him and bring him home. This occurred so long before I saw him, and his cataracts were of such standing, and had so fully developed, that I could not form an opinion as to the explanation. That his vision must have been good when he went to the field is evident, for ploughing requires very good vision. Whether it had been a little hæmorrhage into the vitreous I cannot say, or a sudden extension of a previous opacity, but in both eyes excellent vision was restored by operation. Similar observations have been occasionally made by other surgeons.

Age of the Patient.—This should always be an object of inquiry, for our mode of operation is dictated largely by age, or rather by the conditions known to be usually associated with certain ages. The existence of a nucleus at about 30 years, and the condensation of the lens so as to cause loss of accommodative power at about 60, are facts not to be forgotten. But they are not facts of quite the overruling importance some surgeons make them.

So much, however, has been said in relation to age as a guide to the operability of cataract that I have arranged my tabular statement of cases by ages, so that the reader may have before him facts by which to judge of the value of the opinions expressed as a guide in practice. It will be evident that my operations on the pure nuclear form of cataract show that such cataracts, though incomplete structurally and functionally, can often be removed successfully by ordinary methods at 50 or 60

BOSTON M
APR 1 - 1921
LIBRARY

years, but that on the contrary, where the cataract is of the cortical form, the guidance of age is not in any way to be relied on. If the cortex be of the striated, flaky, mother-of-pearl character, it matters not whether a person be 60, or over, or under that age, the cortex resists removal by the ordinary methods of pressure, massage, scoops, and spoons. I am confident that any operator guided by the age of the patient solely, and not by the character of the cortex, would find himself confronted with grave difficulties. As it is, even with the aid of irrigation, I do not find the removal of cortex at 60 years and upwards always as easy as I should wish. Because a certain class of cataract, incomplete structurally and functionally (the pure nuclear), can be often easily removed at 60 years and upwards, is no ground for asserting that all cataracts, whatever their character, can be so dealt with at that period of life.

Age of the Cataract.—This is in many cases of some importance, and should be always ascertained. The surgeon, however, would make great mistakes if guided by this alone. If it be of the nuclear variety, and of some other forms described, this is a valuable indication; but in others, as, for example, the uncommon form described as "barred," it would be most misleading if the surgeon thought that through mere duration it could be easily extracted.

General History and Condition.—The importance of the general health of the patient for the best surgical results has not been as much thought of in recent years as formerly, and not nearly so much as it ought to be. Bacteriological investigations have, however, shown that good general health is of much consequence. The surgeon should ascertain whether there is any neurotic, rheumatic, gouty, syphilitic, malarial, or alcoholic taint or

tendency, and likewise whether there has been any recent depressing ailment, as for example influenza. This information is of vital importance in directing treatment of any post-operative complications. The surgeon is sufficiently warned about diabetes, Bright's disease, local eye ailments, but sufficient attention, in my opinion, is not given to those I have mentioned.

Patient's Own Story.—Not unfrequently the story of the patient as told by himself may reveal circumstances and complications which cannot be found out by our ordinary methods of diagnosis. In this way small retinal detachment, retinal hæmorrhage, central choroiditis, hæmorrhage into the vitreous, not sufficiently marked to be discovered by the ordinary tests may be detected, or at any rate a reasonable suspicion of their existence established. It is a good general rule in all cases in which any doubt exists to listen with attention to the patient's own description, and help the elucidation by opportune questions. I am satisfied that undue haste is to be credited with some mistakes in diagnosis and disappointments in results.

Judging the Value of Different Factors.—In Chapter IX. will be found an object lesson of the application of these different factors in determining whether an operation should be performed or not, in the selection of the method of operation, in diagnosing the character of the cortex, in judging whether the operation will be easy or difficult, and forecasting the probable result.

PLATE I.

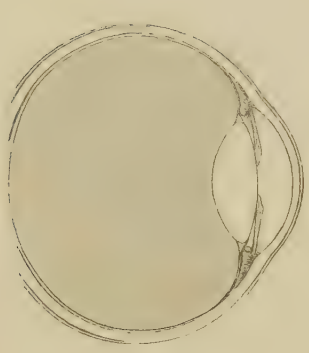

Fig. 1.

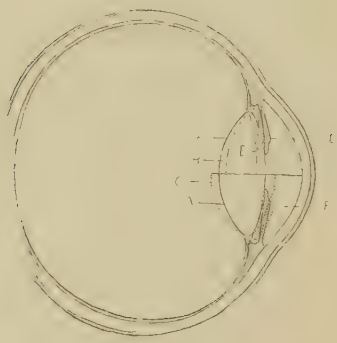

Fig 2.

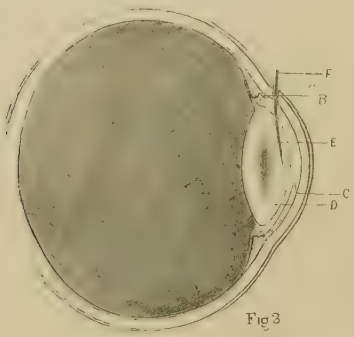

Fig 3

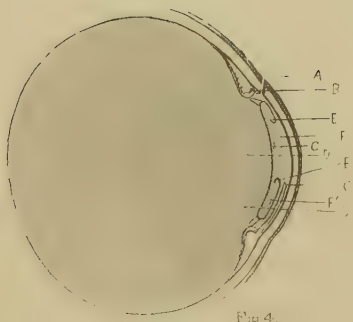

Fig 4.

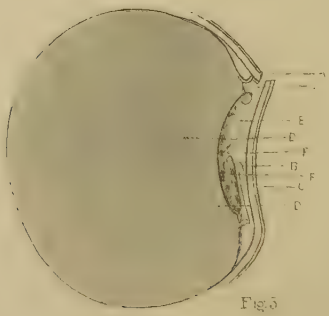

Fig. 5

PLATE I.

FIG. 1—Schematic representation of the eye, shewing normal relations of the various parts.

FIG. 2—Schematic representation of alterations in the lens and its relations in sclerosis of lens, and in the swollen stages of cortical cataract.

A.—Normal lens.
B.—Sclerosed lens.
C.—Swollen lens.
D.—Iris in normal position.
E.—Iris fallen back to position of sclerosed lens, making anterior chamber deep.
F.—Iris pushed forwards by swollen lens, making anterior chamber shallow.

FIG. 3—Vertical antero-posterior section of the eye, shewing relations of the parts after section of the cornea with lens of normal size. Fine needle represented inside of capsule of lens.

A.—Peripheral section of cornea.
B.—Ciliary margin of iris where iridectomy has been performed.
C.—Iris pushed forwards against cornea.
D.—Lens which has come forward against or towards iris and cornea.
E.—Nucleus of lens.
F.—Fine needle introduced inside the capsule of the lens in front of the nucleus.

FIG. 4—Relation of the structures after expulsion of body of the lens.

A.—Corneal section.
B.—Ciliary margin of iris.
C.—Iris close to cornea.
D.—Vitreous has come forward causing posterior capsule of the lens (G) to be convex anteriorly.
E.—Anterior capsule of lens directed inwards by coherent and sticky cortex and other conditions, which neutralizes the ordinary elasticity of the capsule. The drawing is diagrammatic, and not supposed to represent accurately an anatomical condition which must vary much in the disturbed relations of the parts.
F.—Remains of lens free.
F′—Remains of lens imprisoned in capsule.
G.—Posterior capsule of the lens.

FIG. 5—Conditions of the parts on pressure on the cornea to remove cortical substance.

A.—Incision gaping.
B.—Iris.
C.—Cornea depressed by finger or scoop.
D.—Vitreous pressed back.
E.—Posterior capsule of lens pressed back.
F.—Cortical substance free.
F′—Cortical substance confined inside capsule.
G.—Suspensory ligament of lens pressed forward towards wound by vitreous behind it.

CHAPTER IV.

REMOVAL OF CORTEX.

Discussion of Methods from a Physical Standpoint.—Probable Behaviour of Different Descriptions of Cataract on Operation.

It is now fit to inquire, looking at the structures involved, and judging from a purely scientific and physical standpoint, what the different means at our disposal for the removal of cortex can be reasonably expected to accomplish. But first let us look at different conditions of a typical character with which we have to deal.

DIFFERENT TYPICAL CONDITIONS.

Fig. 1 is a schematic representation of the vertical section of a normal eye introduced for the purpose of comparison, whilst Fig. 2 represents the changes which take place in the relation of the parts in sclerosis of the lens, and in swelling during the development of cortical cataract.

In Fig. 2, A represents the normal lens; B, the contracted lens in ordinary sclerosis of the lens; C, the enlarged lens in cortical cataract; D, the normal position of the iris; E, the iris fallen back on the sclerosed lens, causing the anterior chamber to be deep; F, the iris pressed forward by the swollen cortical substance, causing shallowness of the anterior chamber. These figures make evident the value of the degree of the depth of the anterior chamber, and the flatness or convexity

respectively of the anterior surface of the lens in the diagnosis of the character of the lens. It is to be remarked that, whilst usually sclerosed lenses are small, they are sometimes of large size.

The nuclear cataract, when sclerosed sufficiently, escaping whole if the corneal section be sufficient, the question of difficulty of removal of cortical substance does not arise in that class of cataract. But in the early stages of nuclear cataract, and in all cases of incomplete cortical cataract, the removal of the cortex is the crux of the operation.

Methods of Dealing with Cortex.—We will now consider the methods of dealing with the cortex. These are six in number, and there may be a combination of all or some of them. Three of these methods may be classified as preliminary or preparatory treatment of the cortex; two of them practised some time anterior to the extraction of the lens, and the third practised at the time of the extraction, but before the expulsion of the body of the lens. The three others are available after the expulsion of the lens.

Preliminary Treatment of Cortex.—

1st. By preliminary Needle Operation.

2nd. By Foster's Artificial Maturation.

(These two I have already discussed.)

3rd. By the introduction of a liquid inside the capsule of the lens by a fine hollow needle immediately before the stage of capsulotomy after the manner I advocate. This constitutes a stage of the operation.

Action of Liquid Injected by Fine Hollow Needle. — Fig. 3 represents the conditions existing after section at the sclero-corneal junction with iridectomy in case of ordinary cortical cataract. The lens advances to

or towards the cornea, and from its relative size and softness lies close to the wound. The fine hollow needle is shewn introduced superficially inside the capsule of the lens, and liquid is injected after the manner hereafter described. See also Fig. 48 for movement of needle inside capsule.

The conditions are all favourable for the safe and usually effective performance of this stage of the operation. The cortex being soft, the needle readily enters, and there is no danger of dislocation of the lens. The fibrous, radiate, stratified structure of the cortical substance aids and directs the superficial spreading and diffusion of the liquid under and near the capsule towards the periphery of the lens. It renders transparent substance opaque, it breaks up striated, flaky, mother-of pearl cortex, it separates cortical substance from the capsule, and may, if the surgeon uses the method freely, wash out more or less. How far its disintegrating action may extend it is not easy to say in any given case, but that it is great may be seen on watching the changes which take place in that part of the lens under the surgeon's eye. The action of the needle is the result of two direct mechanical forces, viz., the force of the needle itself varying according to its movement, and the more far-reaching force of the liquid, and its imbibition by the cortex.

Methods Applicable after Expulsion of Body of Lens.—These are :—

1st. Pressure and friction on the outer surface of the eye, whether by spoon or finger, and directly on the eye, or on the eye through the medium of the lids.

2nd. Scooping out by a scoop introduced into the eye.

3rd. The force and disintegrating action of liquid introduced into the eye.

Pressure and Massage and what they can do.—After the expulsion of the body of the lens the condition existing is represented by Fig. 4. The posterior capsule of the lens is pushed forward by the vitreous. There may be cortex (F) free in the pupillary area, and cortex (F′) imprisoned behind the retracted and incurved capsule (E).

Fig. 5 shews the nature of the problem of removing cortex by pressure or massage. The soft jelly-like vitreous (D) is the point or rather cushion of resistance, the force, whether by finger acting through the lid or by curette on the cornea at C, causes a depression of that membrane with a corresponding depression of the remains of the lens F and F′. It is obvious that whether the remains of the lens will be expelled, or, on the contrary, the vitreous at G depends on the relative resistance of the lens remnants, and of the posterior capsule E and zonule of Zinn G. If the cortex is separated from the capsule, and therefore free, it may be rubbed and pressed out; but, if not, the chances are that, notwithstanding all efforts by pressure and massage, it will in great part remain in the eye.

Further, that pressure and massage may be effective, even in their limited field, it is necessary to have the presence of a liquid, whether the natural aqueous humour or a liquid introduced from the outside, as, for example, water or an artificial aqueous humour. Hence even in cases of cataract, regarded as easy of operation, should the secretion of the aqueous fail before the removal of the cortical substance, difficulties almost insurmountable in completing the operation satisfactorily are met with unless the place of the aqueous is supplied artificially.

Scooping, and what it can do. — The idea of removal of a body like the lens from the interior of the eye by a scoop introduced behind it is a very natural one,

PLATE II.

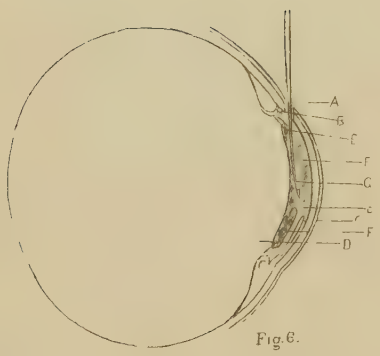

Fig. 6.

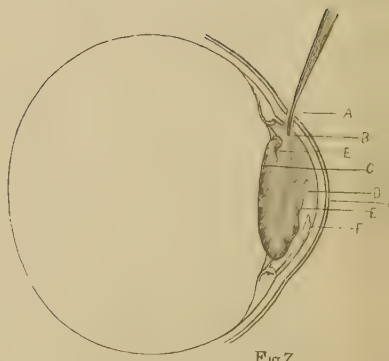

Fig. 7.

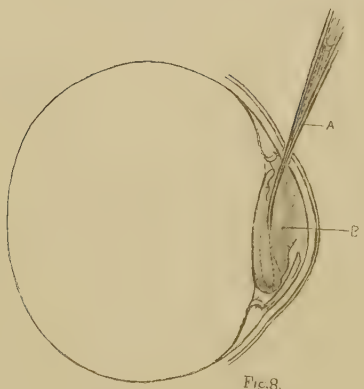

Fig. 8.

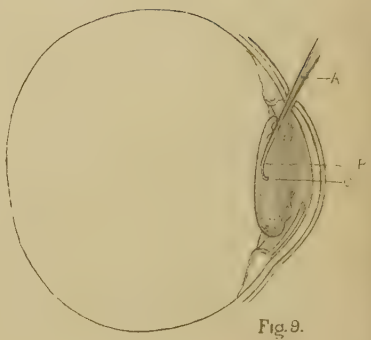

Fig. 9.

Fig. 10.

Fig. 10. A.

PLATE II.

FIG. 6—Condition of the parts on introduction of a scoop to remove cortex.

A.—Incision.
B.—Ciliary margin of iris where excised.
C.—Iris against cornea.
D.—Vitreous.
E.—Anterior capsule.
F.—Remains of lens in pupillary area.
F′—Remains of lens inside capsule and behind iris.
G.—Scoop in anterior chamber.

FIG. 7—Relation of the parts in intra-ocular irrigation.

A.—Incision.
B.—Nozzle in wound, introducing fluid from irrigating apparatus.
C.—Posterior capsule of lens more or less pressed back by the fluid towards the position it had before the extraction of the body of the lens.
D.—Cortical substance.
E.—Capsule floating.
F.—Iris represented as pressed forwards by fluid towards cornea; but if fluid was so directed as to come with any force in front of the iris, it would assume a backward position.
G.—Cornea is pressed forward so as to assume its normal anterior convexity.

FIG. 8—Same as Fig. 7, but representing more effective irrigation by nozzle in the capsular sac and behind cortical substance.

A.—Nozzle—antero-posterior vertical section.
B.—Termination of nozzle with fluid issuing from slit in the end.

FIG. 9—Same as Figs. 7 and 8, but shewing a scoop nozzle with slit in posterior surface from which liquid issues.

A.—Scoop nozzle.
B.—Slit.
C.—Ledge of scoop.

FIG. 10—Anterior view of jet issuing from simple nozzle. For purpose of illustration a strong jet is shewn.

FIG. 10 A.—Lateral view of jet.

and in certain circumstances, such as escape of vitreous and dislocation of the lens, may be indispensable, but for removal of residual cortex its use is very restricted.

Fig. 6 shows the conditions under which a scoop is used to remove cortex. The posterior capsule of the lens is pushed forward by the vitreous, the torn capsule E is retracted and curled inwards, imprisoning cortex F′, concealed behind the iris. F is cortex in the pupillary area. G is a scoop introduced into the pupillary area. It is well known that it can only be used safely in that region, *i.e.*, to remove visible cortex. It cannot be employed on cortex enclosed in the capsule and concealed behind the iris. Its field is therefore very restricted. In simple extraction the only part of the lens area under view is that corresponding to the natural pupil—that is, about $\frac{1}{8}$ or $^1/_{10}$ of the anterior surface of the lens, or, in other words, $\frac{1}{8}$ or $^1/_{10}$ of the whole field of operation. The combination of iridectomy remedied this to some extent, but, on the most favourable view, just about in proportion to the enlargement of the pupil. If iridectomy enlarged the pupil so as to expose one-fourth of the area of the lens, then the scoop might be used, and often only with partial success, on one-fourth of the field, but on the other three-fourths it could not be used at all. It only, too, can be used to deal with the opacities of a coarse character, and not with those of delicate and doubtful nature, or with a cortex which is transparent. All scoops, as scoops, must therefore be condemned as insufficient, but may be of service as auxiliaries in the manner hereafter described.

The Force and Disintegrating Influence of a Liquid introduced into the Eye, and what they can do.—The methods of applying this force are illustrated by Figs. 7, 8, and 9. Some features in the diagrams, and which truly represent what takes place in

actual operation, stand out prominently—viz., that the tendency is to re-establish the normal relations of the parts. The liquid, whether introduced by a nozzle in the wound, as in Fig. 7, or well in the interior of the eye, as in Figs. 8 and 9, presses the posterior capsule of the lens backwards, usually causes the cut and torn capsule to come forwards, and to flap about according to the direction and force of the stream, and reaches every part of the interior of the capsule, searches every corner for cortical remains, whether large or small, concealed or exposed, opaque or transparent. The cornea assumes its normal convexity. The force is equable and gentle, and acts everywhere in the field of operation.

But the liquid acts not by its mere force alone, but by its mere presence altering the character of the cortical substance, diminishing its cohesiveness and consistence.

Whilst I think I have stated fairly what these different methods which I have here discussed may be expected to do and not to do separately, I wish to emphasize the fact that various combinations of them, as clinical experience has taught me, sometimes accomplish more than any one can do alone.

Combinations of Methods.—The combinations of which I have experience are three :—

1. Combination of Injection by Fine Hollow Needle and Massage.
2. Combination of Scooping with Irrigation.
3. Combination of Irrigation with Massage.

Combination of Injection by Fine Hollow Needle and Massage.—The object of injection by the fine needle is not the immediate evacuation of the cortical substance, but to secure a separating action on the superficial layers of the cortex, so that in many cases, especially in transparent cortex, only a very little injection may

be desirable. After injection a little delay in allowing the fluid to make its way may render material service. The capsule having been more or less disturbed in its connection with the body of the lens, a still further separation may be brought about by circular massage of the cornea at its periphery by the forefinger through the eyelid, and a massage from the centre towards the periphery. What is specially wanted is to separate the body of the lens from the capsule, to shift it, as a whole, and to make it start forward complete. Where the cortical substance is segmented, and partly opacified, it is my opinion that freer injection is necessary, and that it is well to move the needle about under the capsule in different directions whilst the injection is going on. In fact the needle may be made in this way to strip as it were the capsule off the lens in a wide area.

Combination of Scooping with Irrigation.—Occasionally when the cortex is unusually tenacious, and the liquid force is not quickly effectual, the nozzle with the little ledge introduced as in Fig. 9 behind cortex, and made to move whilst injection is going on, is successful. When I speak of moving I do not mean a leverage motion, but simply a to-and-fro one in the axis of the chamber.

Combination of Irrigation with Massage. — After the use of irrigation when it is thought likely there may be cortex behind the iris, or when a little piece seems to be peeping into the pupil indicating perhaps much more concealed, massage may bring into view cortex not in the least previously seen, and may alter the appearance of what has been noticed in such a way as to enable the operator to judge more accurately the precise operative work he has to do. I have often seen the value of the use of irrigation and massage alternating

with each other as I have noted in some of the cases. After the pupil seems clear, massage may make it evident that there is more cortex to remove. It may be remarked that if irrigation is so much more effectual than massage, why does it not clear everything out at once? The answer is obvious. Unless the nozzle of the instrument is within the capsule the force of the liquid may sometimes not act directly on all the fragments, but more by general diffusion and consequent maceration and softening. This diffusion and maceration may make particles so free as to allow massage to bring them to the pupillary area. In fact the presence of liquid, as I have already pointed, is one of the conditions of effective massage.

Form of Jet.—The form of the jet from the nozzle depends on a number of circumstances, and the action of the jet is influenced by its form. The surgeon would find observations on jets from various forms and various calibres of nozzle of considerable interest. Fig. 10 is an anterior view of a jet from the simple nozzle. It is at first heart-shaped, wide, and flat, and its plane corresponds with that of nozzle. The edges incline toward each other and cross, and the plane of the jet then becomes at right angles to the initial plane, and so on in succession. Fig. 10A is the lateral view of the same jet. It will be apparent that such a nozzle, introduced inside anterior chamber, will at first sweep the parts laterally, and then tend to do so antero-posteriorly.

Diagnostic and Prognostic Value of Intra-capsular Injection by the Hollow Needle.—Whilst the fine needle for intra-capsular injection plays a very important part in my operations, the ease, or difficulty, or it may be failure, to introduce it readily is of great moment from a diagnostic and prognostic point of view.

(1.) Often in nuclear cataract it is found that the needle cannot be safely introduced inside capsule, *i.e.*, instead of entering the lens it seems to push it before it. The surgeon must desist lest he should rupture the zonule of Zinn, and he may be confident that he is dealing with a lens sclerosed, though partially transparent, and that the lens will come out *en masse*. The action of the needle proves the character of the cataract.*

(2.) When in nuclear cataract the needle enters readily it proves that the cortex is relatively soft, and may remain after expulsion of the nucleus. Here, after injection, the superficial cortex becomes opaque generally at once, but there should be no hurry in removing the lens.

(3.) When cortical opacity is the predominating feature of the cataract, the needle enters easily, and if softening is nearly completed the injection swells the lens, and if freely used may evacuate large masses of

---

* Several surgeons have discovered in recent years what was known to St. Yves, and doubtless to many of the surgeons of old times who operated by depression or reclination —viz., that a lens with cortex transparent might be perfectly sclerosed.

The reader will find ample evidence in this treatise of this fact, but it is strange that St. Yves had very similar experience in his needle operations. He found that lenses with transparent cortex were sometimes so hard as not to be entered by the couching needle, therefore easily couched, *i.e.*, ripe for the couching operation.

He says: "The situation of true cataracts is various. Sometimes they advance towards the pupil, till they are fully ripe, then they lie on the inner circumference of the iris. At other times, though the crystalline is loosed from the socket of the vitreous humour, still it advances very little towards the pupil, but remains in the middle of the posterior chamber where the cataract ripens. Persons attacked with this last species do not entirely lose their sight; and though their cataracts be fully ripe, they can perceive objects, but in a very confused manner, because some rays pass to the bottom of the eye about the circumference of the cataract."—*St. Yves*, 1741, English translation.

The form of cataract which St. Yves describes as "advancing very little towards the pupil, but remaining in the middle of the posterior chamber, and in which the patients do not entirely lose their sight," were really like those hereafter described as "incomplete nuclear cataract," many of which are proven by their behaviour to have been completely sclerosed.

Panas says: "Lorsque à coté d'un noyau sclereux petit, il existe des couches corticales transparentes denses et comme cirrheuses on est conduit à admettre faussement que la cataracte n'est pas mûre, cela d'autant mieux qu'un degre suffisant de vision subsiste longtemps." That certain cataracts with transparent cortex are sclerosed cannot be disputed, but the question is how to make such a diagnosis with fair certainty.

cortex, and in case of small nucleus the latter might sink down and lead artificially to the same condition and the same troubles as are met with in Morgagnian cataract.

(4.) When the cataract is in a young person and without nucleus, injection should be carefully watched. It may evacuate large masses from the area of the pupil by a very small capsular opening whilst cortex remained behind the iris. There is danger in this case in using the cystitome afterwards of rupturing the posterior capsule of the lens. The lesson is, therefore, to do little with the needle, but to trust to irrigation after expulsion of as much as possible by pressure.

Probable Behaviour of Various Descriptions of Cataract.—The following represents what may be expected to happen on operating on various descriptions of cataract arranged according to the Classification in Chapter II. :—

CORTICAL CATARACTS.

Common Form.

	Pressure, Massage, and Scoop.	Influence of Injection by Hollow Needle.	Influence of Irrigation
1st Stage in which more or less of fundus can be seen. Incomplete structurally and functionally.			
2nd Stage — Unequal opacity, but fundus cannot be seen.	Cortex cannot be expelled.	Breaks up cortex, and makes opacity more uniform ; separates cortex from capsule.	Removes cortex when massage and scoop fail.
3rd Stage — Segmented and swollen.	Doubtful ; sometimes escapes easily ; generally resists removal.	Makes opacity more uniform.	Removes cortex when massage and scoop fail.
4th Stage—Disappearance of striæ and assumption of uniform opacity.	Easy Extraction.	Not necessary.	Not necessary, as a rule, but is easier than any other method of removing residual cortex.

Other and Special Forms.

	Pressure, Massage, and Scoop.	Injection by Fine Needle.	Irrigation.
(1.) Diffuse, hazy, bluish, semi-transparent cortical opacity, without striation.	Very sticky, and cannot be expelled. Commonly nucleus is pressed out, leaving all the cortex.	Makes cortex opaque.	Cortex, if not separated by injection by fine needle, may resist irrigation very much.
(2.) The cataract of myopes of long standing; opacities superficial and very slow in progress, and admitting of considerable vision.	Doubtful—(a) Lens may escape completely leaving no fragment or (b) large transparent masses may be left.	May separate lens from capsule.	Irrigation by scoop nozzle; removes clear cortex when pressure and scoop fail.
(3.) White "barred" opacity.	Almost certainly impossible to remove cortex; sometimes on puncturing the capsule a fluid escapes, leaving non-liquefied cortex closely adherent to capsule.	Breaks up and makes uniform the opacity.	Removes cortex, but sometimes with difficulty when pressure and scoop fail.
(4.) "Posterior polar."	Behaves just as clear lens.	No experience of this.	Only experience in one case, but whole cortex was removed.
(5.) Stellate opacity in posterior cortex extending to peripheral and anterior cortical layers.	Behaves just like common cortical cataract, according to the degree of opacification—that is, cannot be extracted till cortex structurally complete.	Equalizes the opacity.	Acts just as in common forms, according to stage of development.
(6.) Zonular cataract.	(Have never extracted this form of incomplete cataract except after previous needling in the usual way.)		

NUCLEAR.

	Pressure, Massage, and Scoop.	Injection by Needle.	Irrigation.
When complete structurally and functionally.	Easy expulsion.	Needle not required.	Not necessary.
When incomplete structurally and functionally.	Lens may behave in two ways — (*a*) come out *en masse;* (*b*) nucleus may separate, leaving clear cortex, which is very difficult to expel.	If cataract is old, anterior surface of lens flat, it may not be possible to cause needle to enter capsule. This indicates that cortex is sclerosed, and lens will come away entire. If needle enter capsule, it proves that cortex is not sclerosed, and injection opacifies lens, and makes it more easily expelled.	Removes residual cortex when massage and scoop fail.

NUCLEO-CORTICAL.

Depends on Condition of Cortex.

CAPSULAR.

No Observation.

CHANGES OF THE VARIOUS FORMS OF CATARACT AFTER COMPLETE DEVELOPMENT.

	Pressure, Massage, and Scoop.	Injection by Needle.	Irrigation.
(1.) With characters indicating total fluidity of lens.	Description indicates result.		
(2.) With lens of a dirty colour, with spots of greyish or brownish opacity or glistening deposits.	On opening capsule a dirty grumous fluid will escape, but usually the deposits which are adherent to the capsule remain. Particles escaping from the capsular sac may adhere to the iris, and cannot be removed by these methods, but remain a source of danger to the eye, and may entail total loss.		Removes particles readily, and performs the toilette of the whole capsular sac and anterior chamber in the most perfect way.
(3.) With characters indicating shrivelling chalky degeneration and thickening of the capsule.	May be difficult to remove. As a rule, the whole lens in its capsule must be removed.		If it have been possible to open the capsule, and if any fragments be left, irrigation removes them when other means fail.
(4.) With a floating nucleus.	Should corneal section have been made above, after the rupture of the capsule fluid escapes, and the nucleus falls away from the section to the most dependent part, the nucleus usually cannot be expelled by pressure, but must be scooped or hooked out. The section should, in cases of this kind, be made below.		Not required in such case for removing lens, but possibly might be useful. It might be desirable for thorough cleansing out degenerate products.
(5.) Capsulo-lenticular.	May be impossible to tear capsule at thickened part, therefore thickened capsule must be cut round or torn off with forceps. If zonule of Zinn rupture, lens cannot be removed by pressure, but must be scooped out.		

SECONDARY CATARACT.

(1.) Fine membrane.—Knife needle cuts it readily, but uniform shape of rent in capsule not easily secured. (Fig. 55 *a*, *b*, *c*, and *d*.)

(2.) Membrane with different degrees of opacity.—May be cut at weak, clear part, and pushed out of the way, or extracted as in Figs. 54 and 55 should it not retract sufficiently.

(3.) Dense opacity, with adhesions of iris.—As a rule, must be cut with intra-ocular scissors; occasionally may be hooked out and cut off, as in Figs. 54 and 55.

CHAPTER V.

PREPARATION FOR OPERATION.

For all important operations on the eye the preparation required is considerable and of a special character, and must be carried out with the greatest care. These preparations embrace :—

(1) Preparation of the patient.

(2) Selection and preparation of the ordinary instruments.

(3) Preparation of the apparatus for injection and irrigation, as described in Chapter VI.

(4) Selection of room with suitable light, and provision of suitable aids for examining the field of operation, viz., artificial light, reflectors, and magnifying glasses.

(5) The providing of suitable assistance.

(6) Antiseptic and aseptic solutions and dressings.

Asepticism and Antisepticism in Ophthalmic Surgery.—As asepticism and antisepticism play such an important part, not only in the preparation for operation, but in the operation itself and in the after-treatment, it is desirable to consider the agents and the methods to secure these conditions.

There are very different methods of obtaining asepticism and antisepticism according to the subject of the process, for we have to deal with steel and silver, rubber tube and glass, cutting instruments and

blunt ones, solutions and dressings, skin and mucous membrane, vascular and non-vascular parts, transparent and opaque structures, and finally the internal structures of the eye—the anterior chamber, the iris, the lens, and its capsule.

So what may suit one description of instrument may not suit another, what may suit instruments may not suit the animal textures, and what may suit one animal texture may not suit another.

Further, in relation to the agents to be used, some in certain strengths kill all germs, some kill some germs, and some in certain strengths only prevent fructification for a time more or less long.

So far, therefore, as asepticism and antisepticism being a simple, mere rule-of-thumb business, it is in ophthalmic surgery a highly technical and complex affair.

The Micro-Organisms to be Killed or Development Restrained.—They are really pus cocci—staphylococcus pyogenes aureus, staphylococcus albus, and streptococcus pyogenes. Considering the universal prevalence of these organisms on the surface of the body and on mucous membranes, in air, water, soil, &c., if they were always potent hardly any wound could be expected to be free from inoculation leading to pus development. But fortunately, either through attenuation of the cocci or from the resisting power of the tissues, the dire consequences are not so prevalent as the universal existence of the recognised common cause or causes would lead us to expect.

Antiseptic and Germicidal Agents.—These are of two main classes, viz., physical and chemical. The former are applicable to instruments, dressings, and

solutions alone, and the latter both to instruments and patients. The physical agents are—

Boiling.
Steam in motion.
The flame of a spirit lamp.

Chemical agents—

Boracic acid and its solutions.
Solution of perchloride of mercury.
Solution of bin-iodide of mercury.
Hydro-naphthol.
Alcohol.
Iodoform.
Solution of chinosol.

In estimating the relative position of these different agents as antiseptics and germicides, I take as my guide bacteriological research, so far as it bears on ophthalmic surgery.

Physical Agents. — *Boiling Temperature.* — Exposure to a boiling temperature for a minute or two will infallibly destroy the micro-organisms I have mentioned, and all others of a like kind, when they are in a moist condition or moist heat is used. Even the spores of all known pathogenic bacteria are destroyed by a temperature of 100° C. maintained for five minutes. Boiling, therefore, for all practical purposes, is sufficient to sterilize all instruments and solutions. All cutting instruments, such as knives, needles, cystitomes, and scissors, are injured in their temper by such an amount of boiling in water. It does seem strange that when temper is of so much importance, and the instrument maker requires years of experience to know how to temper a cataract knife, the very first act of the surgeon in the preparation for operation is to injure that very quality. Such injury would perhaps more than counter-

balance the gain from a rigid asepticism of these instruments obtained by this method, and therefore it is well to modify it. Dipping them in boiling water for two minutes would perfectly accomplish all that is required, but I think mere immersion for about a minute would be sufficient for smooth instruments such as knives, needles, etc.

The greatest danger is really from instruments having little niches in which septic material may be lodged, such as forceps and scoops and nozzles, which may be boiled freely.

Steam in Motion or Streaming Steam.—Streaming steam of a temperature of 100° C. is a most effective germicide, in fact the same as boiling water. Hence the passing of steam through bottles and rubber and glass tubes effectually sterilizes them.

Discontinuous Heating to Kill Spores.—This method, introduced by Tyndall, is now in general use in many bacteriological laboratories. The liquid to be sterilized is boiled for a short time, destroying all the bacteria in the vegetative stage. After the lapse of 24 hours another boiling is made to destroy bacteria, which may have developed from spores during that period, and on one or two further occasions after a like lapse of time. I mention this to indicate what must be done to have perfect security, but considering that the liquid I use for intra-ocular irrigation is distilled water, containing some chloride of sodium in solution, I consider one boiling is sufficient for all practical purposes.

The Flame of a Spirit Lamp.—Passing instruments through the flame of a spirit lamp has been practised by many operators. Some years ago I followed this plan, but I have given it up, for it undoubtedly injures the quality of cutting instruments, which in eye operations is of far more importance than in ordinary surgery.

A nozzle or scoop, about whose asepticism one has doubts, may in an emergency be treated in this way, but the flame of the spirit lamp should not be regarded as one of the regular appliances for asepticism.

Chemical Agents.—The agents commonly used in ophthalmic surgery are of the most varied power as antiseptics and germicides. It may be said of them generally that some are mildly antiseptic, but valueless as germicides, whilst others are powerfully antiseptic, but cannot be used in a strength sufficient or for long enough time in all circumstances as to be germicidal. The chief agents in common use are boracic acid, perchloride of mercury, biniodide of mercury, hydro-naphthol, alcohol, and iodoform. Chinosol is a new agent which I consider superior to all others.

Boracic Acid is said to have a restraining power, or to be antiseptic in a proportion of 1 in 143, but a saturated solution does not kill pus cocci in two hours (Miguel). It is, therefore, useless as a germicide.

Perchloride of Mercury has, according to Miguel, an antiseptic power in the proportion of 1 in 14,300, and, according to Sternberg, 1 to 15,000. Its restraining power is very remarkable. Koch has found that even the development of spores is restrained by 1 : 300,000 in a culture medium. Sternberg says that the pus cocci are restrained in their development by 1 in 30,000. It has been found that spores which have been subjected to the action of the perchloride, although not killed, will not grow after ordinary washing (Geppert), but a chemical agent must be used to neutralize the perchloride.

Although there is a difference in the degree of the antiseptic power according to different observers, they are all agreed in placing it at a very high level.

The germicidal power is stated to be as follows for the staphylococcus aureus, in bouillon cultures :—

1—1,000. 8 secs. (Gärtner and Plagge).
1—1,000. 2 minutes (Tarnier and Vigal).
1—1,000. 5 minutes to 30 (Abbott).

The probability is that these different observers experimented with cocci of different degrees of resistance.

About its action on the staphylococcus albus I have no definite information, but this coccus is said to have little pyogenic capacity.

The streptococcus pyogenes is killed by exposure for two hours to a solution of 1 in 2,500.

Bin-iodide of Mercury, according to Miguel, is antiseptic in the proportion of 1 : 40,000, whereas Sternberg states it to be 1 : 20,000.

Hydro-naphthol has been found, according to Foote, to have some germicidal power in the proportion of 1 : 2,300, but the conclusion is reached that a saturated aqueous solution (1 : 1,150) does not equal a 1 per cent. solution of carbolic acid, which kills pus cocci in two hours. The germicidal power is therefore a negligable quantity.

Alcohol.—The popular notion about the germicidal power of alcohol is quite erroneous. The mere dipping of an instrument in absolute alcohol gives no protection.

Iodoform is supposed to be of very slight value as an antiseptic; but from the fact that it is non-irritant, and may be kept in prolonged contact with wounds, it may have an influence in preventing development of germs. At any rate I have used it a good deal, and I believe it to have an influence in promoting the healing of wounds.

Chinosol.—This agent, which is a coal-tar product, I have been using in ophthalmic practice for upwards of a year and a-half. One part of chinosol in 10,000 of

water is stated to kill in ten minutes the following pathogenic organisms—those of typhoid, diphtheria, cholera, and erysipelas, and the staphylococcus pyogenes aureus. It is non-poisonous, very soluble in water, does not form deposits in or combine with the tissues, but readily penetrates them, and finally does not coagulate albumen. It is said to have a germicidal and antiseptic power even greater than that of perchloride of mercury.

Objections to Mercuric Preparations.—Whilst they may be used safely in a germicidal strength to the skin, they should be only used in an antiseptic strength to the conjunctiva, about 1 in 6,000, and with certain limitations. It is difficult to see what a momentary washing of the conjunctiva, by a solution of this strength, before operation can effect, but after the section has been made there are grave drawbacks to their use. Their power of coagulating albumen, and liability to form combinations with the tissues, and to cause indelible opacities, are qualities which may occasionally bring about disastrous consequences, but not in such number as to be a set-off to their positive advantages if there were no substitute. I think there is little doubt, too, that the solution of perchloride of mercury, whilst it may prevent suppuration, has the disadvantage of retarding the healing process.

Solution of Chinosol as a Substitute for Mercuric Solutions.—This agent seems to have all the good points of the mercuric salts without their disadvantages. I have abandoned the use of mercuric salts for a year and a-half, and I have been using instead chinosol, in a strength of 1 in 4,000 for application to the eyeball in operations on the eye, and likewise extensively in ulcers of the cornea, and occasionally I have injected a solution of one part in 8,000 into the

anterior chamber in extensive suppuration of the cornea with hypopyon, and I have not found any objection to it save that it smarts a little. It is my opinion that wounds and ulcers heal more quickly under the chinosol treatment than by any other, and with unusually slight opacity, and I think I have given it a long enough trial to speak decidedly.

Explanation of the Success attending Antiseptic Methods.—The success in ordinary cataract operations, then, cannot be owing to germicidal action when momentarily applied to the conjunctiva, but doubtless to the selection of cases without any obvious affection of the conjunctiva and appendages, and to the care attending the preparation of the instruments, and the attention given to the hands, the solutions, and dressings. Besides the general cleanliness, as a necessary consequence of efficient antisepticism, embraces of course attention to the thorough washing of the parts around the operative field, and the application of antiseptics of sufficient strength to the lids.

It may be reasonably asked, why apply an antiseptic solution to the conjunctiva at all during operation? It really secures, as a matter of routine, an aseptic liquid, and the prevention of the introduction of germs from the outside through the medium of impure water.

In addition, as I have stated, the micro-organisms are not always virulent. Indeed, in wounds treated antiseptically, they may be present without doing any harm. Bossowski, in 50 cases of wounds, treated antiseptically, obtained bacteria from the discharges in 40, and in 26 of these he found staphylococcus albus, in 9 staphylococcus aureus, in 2 streptococcus pyogenes, and in 8 various non-pathogenic bacteria. In 45 laparotomy wounds, examined by Ghrisky and Robb,

in which strict antiseptic precautions had been observed, bacteria were found in 30, and in 19 of this number staphylococcus albus was present, in 5 staphylococcus aureus, and in 3 streptococcus.

Professor Gayet, of Lyons, made elaborate bacteriological investigation relating to the microbes of the conjunctiva, and states as a result that antiseptic or aseptic measures exercise only a very slight influence on the presence of germs in the conjunctival *cul de sac*, and that whatever care may be taken one is never certain of getting rid of them in the operative field, and further, that these germs are not all pathogenic, since the number of cases of suppuration in his practice was 6½ per cent., whilst the fertility of the operative field was 75 per cent.*

Preparation of the Patient.—When an operation has been decided on, and there is no evidence of any local affection to contra-indicate it, the surgeon should proceed to do it as soon as possible. It is a good rule to have the patient under the eye of a skilled nurse from the previous evening to ascertain whether there are any peculiarities or idiosyncrasies of which he should be aware. In this way information may be obtained which would not be got by direct enquiry. As a rule, the only matter to be attended to is the administration of a purgative when required the night before operation. If the patient suffer from any affection of the conjunctiva, or of the margins of the lids, or of the lacrymal passages, or even nasal passages likely to lead to an inoculation of the eye by pyogenic organisms, the operation should be postponed till such affection has been cured, or as far as possible mitigated. If there be no such evidence of a local affection nothing further is required

* *Archives d'ophthalmologie*, 1887.

than washing the face with soap and water, and the subsequent application to the skin of the solution of chinosol.

When one eye has been operated on for cataract, and both eyes have been bandaged for a few days, the surgeon should allow the second eye to remain uncovered for a day or two before operating on it to remove the congestion and slight conjunctival discharge, which is frequently caused by the bandage, and should treat the conjunctiva with a suitable local application, nitrate of silver or other antiseptic as the case may be.

Undoubtedly the conjunctiva of an eye which has been bandaged for some time affords a nidus favourable for the breeding of micro-organisms.

Selection and Preparation of Instruments.—The operations for cataract really necessary are few in number, and require only a few instruments. There are some instruments hardly ever required, but which should be at hand for emergency. Whatever the operation may be, the surgeon requires a speculum to separate the lids, and a pair of forceps to keep the eye steady. A great many of the specula are radically defective in construction. The speculum I use is an old sort, which has the valuable property of never allowing the lids to slip out. The bent loop is complete, and not open at one side, as in many specula (see speculum in figs. in Plates V., VI., and VII.), and the lids lie in a deep space or trough, from which no movement of the patient can relieve them. Any speculum from which the patient can wriggle out the lids is a bad one. The instrument is so long and so curved back towards the temple that the assistant can readily hold it and gently support it, so that the eyeball is relieved from any pressure of the lids or of the instrument. I think the plain fixing forceps, without any spring catch, is the best (Fig. 12).



Fig. 12.

For needle operation the only other instrument required is the needle (Fig. 13).

Fig. 13.

For simple linear extraction, spear-shaped knife (Fig. 14), curette and pricker (Fig. 15) are required, in addition to the speculum and fixation forceps.

Fig. 14.

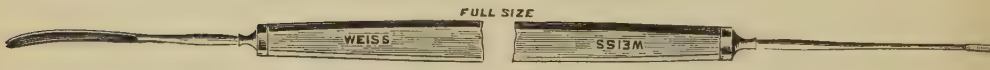

Fig. 15.

The following for Wecker's 3 Mm. flap in addition to the speculum and fixing forceps :—

Graefe's knife (Fig. 16).

Iridectomy forceps, straight and curved (Figs. 17, 18).

Iridectomy scissors (Figs. 19, 20).

Currette and pricker (Fig. 14).

Critchett's scoop (Fig. 21).

Taylor's vectis (Fig. 21A).

Spatula (Fig. 21B).

Fig. 16.

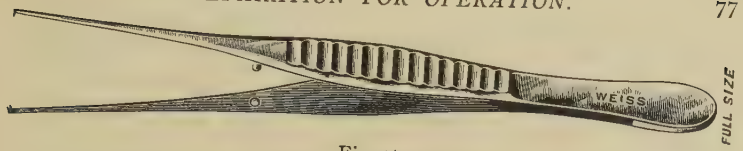

Fig. 17.

Fig. 18.



Fig. 19.



Fig. 20.



Fig. 21.

Fig. 21A.

Fig. 21B.

For injection and irrigation the needles and nozzles for use with the irrigating apparatus are elsewhere described.

For operations on the capsule :—

Knapp's knife needle (Fig. 21C).

Bowman's two stop needles (Fig. 13).

A capsular hook (Fig. 21D).

Wecker's scissors (Fig. 21E).

Fig. 21C.

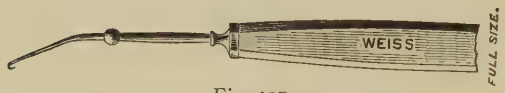

Fig. 21D.

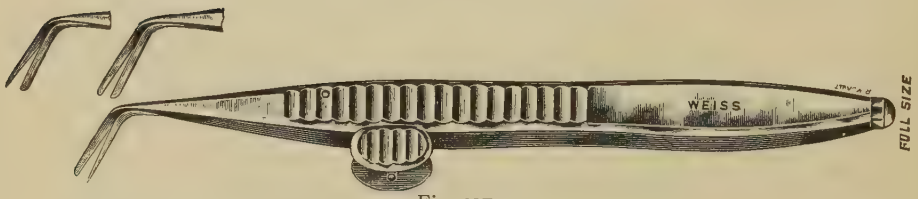

Fig. 21E.

Various modifications will be found of the most of the instruments to suit the particular views of individual operators, but in actual work the surgeon will find he can accomplish all the operative work on cataract he is ever likely to be called on to do with the instruments specified.

These instruments should all be boiled for a few minutes with the exception of the knife, pricker, and scissors, which should only be boiled for about a minute in order to avoid damaging the temper of the steel as much as possible. I do not know of any efficient chemical germicide which does not injure steel instruments. I therefore do not put my instruments into any fluid after the boiling.

PREPARATION OF THE APPARATUS FOR INJECTION AND IRRIGATION. *(See Chapter VI.)*

Suitable Light and Optical Aids.—It is most important for all operations, and especially in operations on incomplete cataract, that the light should be good and reliable, and that its source be in such relation to the eye to be operated on that the view of the field of operation is not obscured by corneal reflexes. It does not matter whether the light be a northern or any other light if these conditions be fulfilled.

In climates so fickle as we have in most parts of the United Kingdom, it is necessary to have available good artificial light if the operation is not to be postponed. It is not very unusual to find the light which was good at the beginning of an operation fail before the termination of it, and this is specially perplexing in extracting incomplete cataract.

Now that electric light has come to be in such general use in cities and towns of any importance, the surgeon, as a rule, has little trouble in having a sufficient supply from the public electric works. When such is the case it should always be provided, as it makes the surgeon independent of atmospheric or other conditions, and enables him to see precisely what he has to do, and to judge of the condition of the cortex in all sorts of cataracts, complete or incomplete. The electric light lamp which I use is as follows :—It consists of a lamp* of 100-candle power enclosed in the metallic cylindrical case shown in Fig. 23, with a condensing lens at the end capable of being moved. If the light is placed at a point corresponding to the focal length of the glass, the rays emerging are parallel rays, and the surgeon, having ascertained this, can vary the intensity of the light by

* Messrs. Lizars of this city have supplied me with both the electric and acetylene lamps.

varying the distance of the condenser from the light. When it is desired to inspect the field of operation or to use the light in carrying out any step of the operation, an assistant directs the light on the eye to such an extent as the operator may desire. The lamp which I use may be placed so far from the eye to be operated on as not to interfere with the movements of the surgeon or his assistants.

The electric light is certainly convenient, but not always to be had. Fortunately, however, it is now within the power of the surgeon to whom the electric light is not available to have acetylene light, an illuminant at least as good as the electric light, and very well borne by the eye. It may be had at a very small cost, and used anywhere.

The apparatus for acetylene consists of a generator, an india-rubber tube to convey the gas to the burners, two acetylene burners, enclosed in a metallic case provided with a condensing lens, as described (Fig. 22). I have employed this light to the entire exclusion of daylight, in winter, throughout operations for incomplete cataract, and I can see cortical substance, whatever its character, and observe the action of the irrigation and injection with a distinctness not attainable by the very best daylight. There are no corneal reflexes, which are often so provoking and disconcerting in operations by daylight. So advantageous is this light, and so superior to daylight, that no operator who undertakes operation on incomplete cataract, if he have not the electric light, should be without it. Indeed, the light of a single burner is of 60-candle as against the 16 to 30-candle power of the ordinary electric lamps used in private dwellings.

Assistants.—It is essential in all cases in which injection and irrigation are used to have one assistant

whose sole duty is to look after the preparation of the instruments and apparatus, and to have them always ready, and another assistant to help the operator.

Antiseptic and Aseptic Solutions and Dressings.—A solution of chinosol, 1 part in 4,000, with sterilized cotton wool immersed, should be at hand, and all the dressings should have been sterilized in the usual way.

If the surgeon use cocaine in solution it is necessary to use a fresh solution, because, if kept for some time, it develops poisonous products. Cocaine is decomposed by boiling. It must, therefore, be dissolved in a sterilized liquid. I have been in the habit for several years of putting into the eye the solid hydrochlorate of cocaine a few minutes before operation.

CHAPTER VI.

DETAILED DESCRIPTION OF THE APPARATUS FOR INJECTION AND IRRIGATION—METHOD OF USE AND LIQUID TO BE USED.

The instruments invented since 1884 to give effect to intra-ocular irrigation and injection are so numerous that it would take up too much time, and I think without corresponding profit, to describe them. I shall not even so much as mention the various instruments I have from time to time used, and my varied experiences during that period, but shall rest satisfied with giving details regarding the apparatus at present and for some time employed by me.

The figures on Plates III. and IV. represent the character of the instruments and appliances so well that it is necessary here only to supplement by pointing out the purposes the different appliances are meant to serve. The whole apparatus, with the exception of the needles and nozzles, could be found in chemical and physiological laboratories. It may be described as consisting of a receptacle to contain the liquid to be used, a tube leading into it through which syphon action may be started by aid of Richardson's india-rubber pump, and an efferent tube to which the needles and nozzles may be attached.

Sterilizing and Irrigating Bottle. — The receptacle for the liquid is a flat-bottomed Florence flask

PLATE III.

Acetylene Lamp.

Fig. 22.—

A.—Body of acetylene lamp.
B.—Condensing lens.
C.—Tubing from generator to lamp.
D.—Stop-cock of acetylene burner.
E.—Pin on which burner is supported.
F.—Rods for regulating distance between lens and light.
G.—Standard for supporting fittings. This is upwards of six feet high, and is fitted on a heavy metal base.
H.—Rod for supporting acetylene lamp.
I.—Screw for regulating height of lamp on stand.
J.—Universal joint for setting lamp at any angle.

Electric Light Lamp.

Fig. 23.—

K.—Sliding tube containing condensing lens. (N.B.—This tube is represented as sliding on outside of L. Since this drawing was made I have had the tube K fitted to slide inside, which I find better.)

L.—Tube containing electric lamp of 100 c.p.

M.—Ebonite handle. I have since had the ebonite handle made to grip on the outside of the tube L all round.

N.—Conduction wire.

Needles and Nozzles for Injection and Irrigation.

Fig. 24—Cylindrical tube with flat central projecting stem. The india-rubber tube from the irrigating flask is passed over the stem on to the cylinder. Into the other end is inserted one of the needle terminals.

Fig. 25—Cylindrical tube with fine, hollow, straight needle at one end. The cylindrical tube is smaller than that represented by Fig. 24, and fits into it tightly.

Fig. 26—Front view, curved needle.

Figs. 27 and 28—Lateral views of needles, curved and straight.

Fig. 29—Cylinder with needle end inserted into outer cylindrical tube.

Fig. 30—Front view of simple irrigating nozzle.

Fig. 31—Lateral view of same.

Fig. 32—Front view of scoop irrigating nozzle.

Fig. 33—Lateral view of same.

Fig. 34—Nozzle cleaners.

PLATE III.

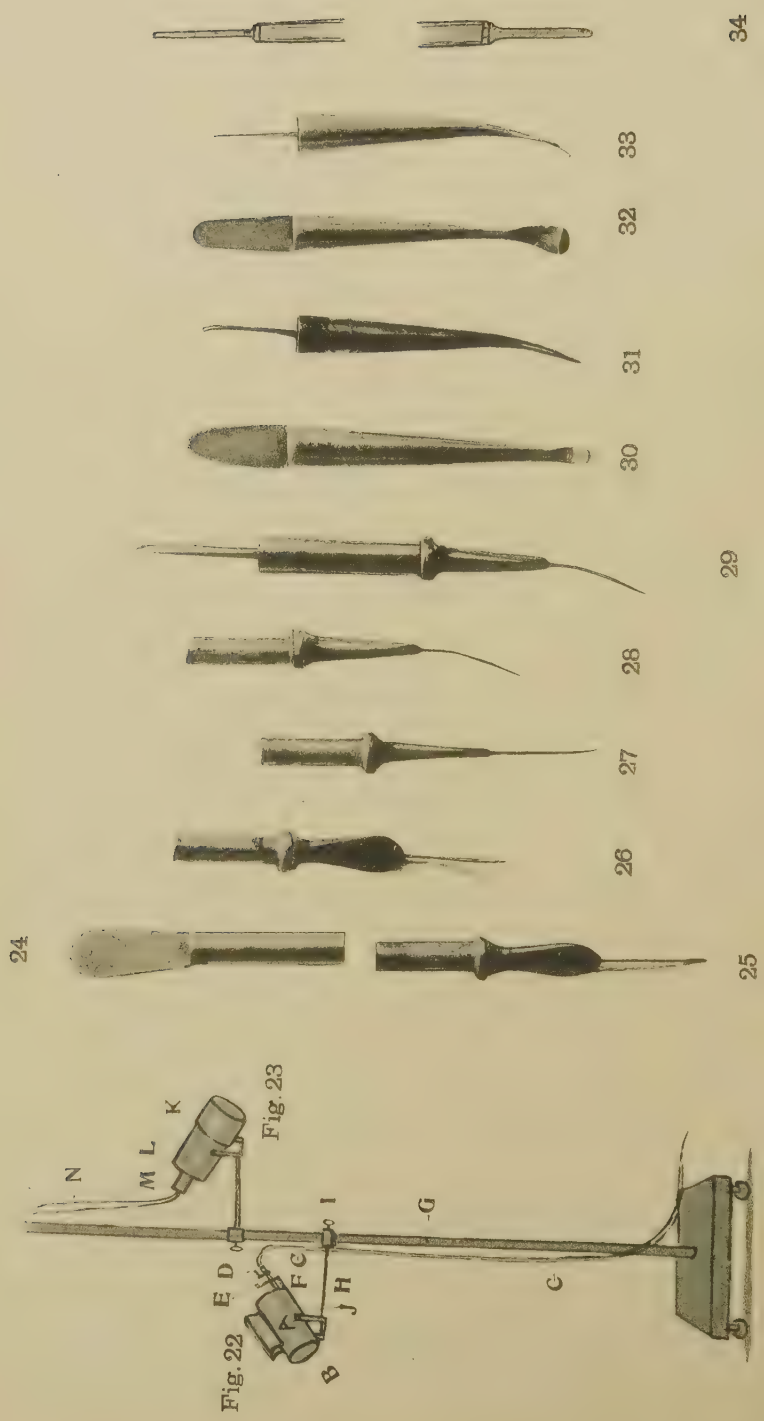

(See Plate IV.), into the mouth of which is inserted a close-fitting cork through which two glass tubes pass. The short tube with the bulb just passes through the cork, and may remain always in the same position. The other tube is so long that it may be pushed down to the bottom of the flask.

The advantage of the Florence flask as a receptacle for the liquid consists in the fact that it is suitable both for carrying out the preliminary precaution of sterilizing the liquid, and for the actual operation. It makes one apparatus take the place of two, and does away with the necessity of transferring the liquid from one vessel to another. The flask with the flat bottom is much more convenient and handy than the common round-bottomed form.

The cork is of ordinary corkwood, which serves the purpose much better than the rubber cork. The long tube can be readily pressed down into the liquid, or pulled out of it, as may be desired, without taking out the cork.

Into the bulb on the short tube is inserted cotton wool, which, whilst it readily allows steam to escape, prevents germs passing from the air outside into the flask during the cooling of the liquid or during the pumping of air into the flask by Richardson's pump.

Fig. 35 represents the flask with the liquid being sterilized by boiling. The liquid must not fill the bottle, and the ends of the glass tubes which pass through the cork must be a considerable distance above the level of the liquid when boiling is going on. Were this precaution not attended to there would be an escape of boiling liquid through the tube which dipped into the liquid, and which would be highly inconvenient. As may be seen in Fig. 35, steam issues from both tubes, so that not only is the liquid sterilized, but the tubes likewise by the steam

in motion. The india-rubber tube into which the needles and nozzles are to be inserted should be attached to the arm of the long tube, as shown in the figure, for purposes of sterilization. The rubber bellows shown in Fig. 38 must not be attached during the boiling, because, there being a valve permitting only of ingress but of no egress, the steam would not find exit through the tube, and if the pressure of steam were sufficient, either the cork would be blown out of the flask or the latter would burst. I notice this particularly, as it is a mistake which might readily occur in the first use of the apparatus. The boiling should be continued for about ten minutes. When stopping the boiling, an ordinary clamp (A, Fig. 36) should be put on the end of the india-rubber tube, whilst the short glass tube with the bulb should be allowed to remain open. Were the rubber tube not so clamped, the air, with whatever germs it might contain, would be sucked into the apparatus during the condensation of the vapour in the process of cooling, and the germs would be deposited chiefly in the tube. Thus, were this detail not attended to, the process of sterilization, instead of being a source of safety, might be positively a cause of disaster. Whilst a single boiling, as above described, will kill any of the pathogenic organisms likely to be met with, if the most absolute certainty be desired Pasteur's method of a like boiling on three successive days, so as to destroy spore-bearing organisms, may be adopted. But if an operator do as I recommend, use only distilled water with a little chloride of sodium dissolved, reserve the apparatus for cataract operations alone, clamp the rubber tube when the apparatus is not in use, it is obvious that a single boiling before operation is all that the most exacting care should require.

Needles and Nozzles.—These are represented on Plate III. The needle consists of two separate parts,

PLATE IV.

FIG. 35—Flat-bottomed Florence flask, during boiling.

A.—Fluid in bottle.

B.—Glass tubes with the ends well away from the fluid.

C.—Small glass bulb on short glass tube, containing cotton wool to prevent entrance of germs.

D.—End of tube for subsequent attachment of india-rubber pump.

E.—India-rubber tube for attachment of needles and nozzles.

F.—Steam issuing from tubes.

FIG. 36—Same flask just removed from flame, to be allowed to cool.

A.—Clamp applied on rubber tube to prevent entrance of germs on cooling.

B.—Small glass tube with bulb, allowing escape of steam. Both the ends of the tubes inside the bottle are out of the fluid.

FIG. 37—Incubator, with thermometer shewn at one side, and gas regulator at the other.

FIG. 38—Irrigating apparatus ready for use.

A.—Assistant's hand holding bottle; thumb pressing on cork.

B —India-rubber pump attached to short glass tube.

C.—Assistant's hand holding rubber ball and pressing it to start syphon action.

D.—Long glass tube now pressed down to bottom of flask.

E.—Needle held loosely by surgeon, allowing water to be pumped through.

PLATE IV.

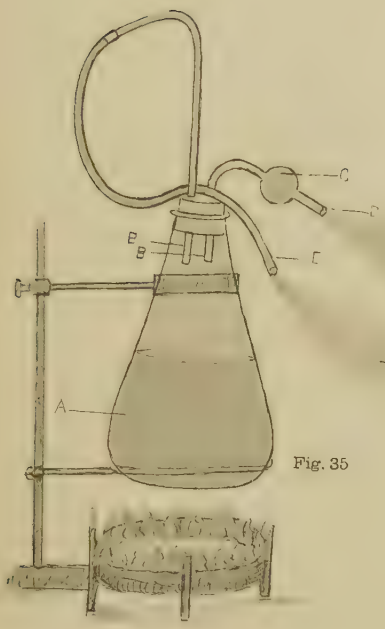

Fig. 35

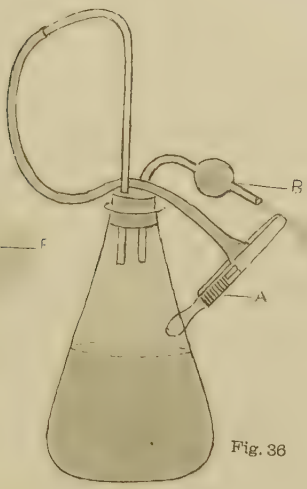

Fig. 36



Fig. 37

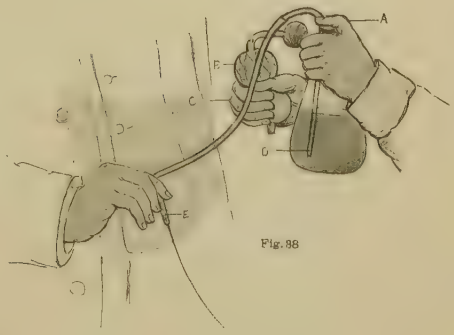

Fig. 38

viz., a cylindrical tube with a flat projecting stem (Fig. 24), and another tube, partly cylindrical and partly flat, like the terminals of some hypodermic syringes, fitting tightly in the former, to one end of which the hollow needle end is attached (Fig. 25). The parts put together are represented in Fig. 29. There are two advantages in having the needle so separated into two parts—(1.) The hollow needle end may be placed in position to direct the stream of water in any direction. (2.) In case the water in the long tube should become too cool it would be rather a slow process to pump it out through the hollow needle terminal. By slipping out the cylinder with the needle, and letting the water flow freely, the desired temperature is quickly secured, and the needle end can be at once replaced. The needle terminals may be either straight or curved. Fig. 25 represents front view of straight needle, and Fig. 26 that of curved needle. Figs. 27 and 28 represent lateral views.

The nozzles are two in number. Fig. 30 represents front view of common nozzle, and Fig. 31 lateral view of the same. The latter shews the slit in the end. Fig. 32 represents front view of scoop irrigating nozzle, and Fig. 33 lateral view. The latter shews slit on the posterior surface.

Fig. 34 represents nozzle cleaners. In case of any irregularity or stoppage of the flow from the nozzles, the nozzle cleaner is to be passed through the slits.

The central flat stems on needles and nozzles are an important feature in the construction of the instrument. The rubber tube to convey the liquid from the flask is passed over the stem on to the cylinder. The stem serves the double purpose of providing a resistant body to grasp through the rubber tube, thus giving steadiness and security, and affording a delicate and efficient means of controlling the flow of the liquid.

The body of the needles and the whole of the nozzles are of silver. The hollow needle ends are of platino-iridium, which material answers admirably because of its hardness, non-liability to rust, and capability of being sterilized by heat without injury.

The needles and nozzles are boiled with the ordinary instruments, and are attached to the rubber tube when required.

How to maintain the Apparatus at a Suitable Temperature.—The temperature of the flask will, of course, in a short time become the same as that of the surrounding atmosphere. It is, therefore, sufficient that the assistant or nurse should have the sterilizing done some time before the operation. The next matter claiming the attention of the surgeon is the maintenance of a fairly uniform temperature during the whole time of the operations. This is important especially when an operation is slow, or when a number of operations must be performed in succession. It is my opinion that a temperature of blood heat, or perhaps a degree or so above it, is the best, and I refer to this point because I am aware that all surgeons do not attach to it as much importance as I do. Any temperature considerably above blood heat or a little below it is disagreeable to the patient, and would be liable to cause more or less involuntary muscular action, but free irrigation with a temperature lower than that of the body would be a dangerous experiment, and one which could hardly fail to injuriously affect the circulation and nutrition of the eye.

The difficulty referred to may be readily overcome by using an incubator the same as those in use in bacteriological laboratories. Fig. 37 represents one which I use at times.* It is large enough to hold four irrigating

* If gas be used as the heating agent for the incubator, it is necessary to put a governor on the pipe giving the gas supply, so as to regulate the pressure of the gas, and consequently the heat of the flame.

bottles, and the temperature can be fixed and kept at the degree at which the operator desires. By having more than one irrigator always ready, when the one in use becomes too cool from exposure to a lower temperature it can be replaced in the incubator and another taken in its place.

The surgeon may not think it necessary to use an incubator, but rather prefer to adopt a simpler method, and to put up with a little inconvenience. His assistant or nurse must then resort to the common expedient of cooling the bottle when it feels too warm by setting it in cold water, and re-warming it over the flame, or placing it in warm water if getting too cold. The water in tube at the beginning of the flow is sometimes relatively cold, and the surgeon must let the water flow on the back of his hand till it reaches what he judges a pleasant temperature. This is the method I have practised for many years, and I have found the hand a sufficiently safe thermometric test. I at one time had a thermometer inserted in the cork, but I have abandoned that long ago.

Different Modes of Using Irrigator.—If there be no obstruction in the tube, needle, or nozzle, the fluid immediately flows on pressure of the rubber ball; if it do not the surgeon must not endeavour to use force. If he do he will either blow out the cork or burst the bottle. He must make the needle or nozzle pervious. The flow having been started there are three actions between which the surgeon must discriminate.

(1.) Syphon action.*

(2.) Jet action.

(3.) Air pressure, or air pressure plus syphon action.

* I have to caution the reader against the dangerous practice of starting syphon action by blowing down the short tube with the mouth, a practice which he might readily adopt from regarding the bad example of using the mouth with Teale's Suction instrument, still in these days of antisepticism referred to without warning in ordinary text-books.

The first is obtained when the nozzle or needle is at a lower level than the flask after syphon action has been started.

The second, when the assistant makes quick intermittent pressure on the tube conveying the liquid as in Fig. 48.

The third, when the ball is pressed and forces out the fluid, when the terminal is at a higher level than the flask, or when the ball is pressed when syphon action is already in operation.

Preparation of Irrigator for Operation.—When the irrigator is required the clamp is taken off the india-rubber tube, and the needle for intra-capsular injection, or the nozzle for irrigation, is inserted in the tube, the long glass tube is pressed down into the bottom of the liquid, and the rubber bellows fixed on the short glass tube (Fig. 38). The nurse holds the bottle by the neck with one hand, keeping the cork in place with the thumb, whilst with the other hand she presses on the rubber ball. When the liquid flows the surgeon seizes the rubber tube where it covers the central pillar of the needle or nozzle and stops the flow. Fig. 38 represents the apparatus ready for use. The surgeon should always observe the force of the liquid before introducing the needle or nozzle into the eye.

Injection and Irrigation, Slight or Free.—Those who use irrigation practise it in various degrees. Some only introduce a few drops into the anterior chamber, whilst others irrigate with a free hand. The instruments used by different surgeons will give almost an idea of their practice. Wecker, with the instrument which he describes, and which resembles a small ear

speculum with the broad end covered with india-rubber, and a fine terminal attached to the small end, pressure being made on the rubber by the tip of the index finger, could not possibly make an injection of more than a few drops. Panas' instrument is of a like kind. The irrigating apparatus of Gayet is large, like what I use, and he irrigates with a free hand, as I have always done.

In relation to operations on the eye, from the smallness of the organ there is an idea, and a proper one too, that everything should be delicate, but there is a confounding of smallness and largeness with delicacy and the want of it.

Whilst instruments to be introduced into the eye must necessarily be fine, it does not follow that the accessories should be small. There is no advantage in having a small receptacle for the liquid, but, on the contrary, a positive disadvantage. It is to be remembered in this instance that the active agent is the liquid, and the instrument merely the channel of conveyance, and that a fine jet with concentrated force is more likely to be injurious than a larger jet with diffused force. I consider it desirable that the surgeon should have an apparatus such as I have described with which he can at his will irrigate, either slightly or freely, either by drops or by a stream.

The Liquid to be Used.—For many years I have used a solution of chloride of sodium in distilled water (4 grs. to the oz.) to approximate to the composition of the aqueous humour, and I have had no evidence of it having been injurious in a single instance. Not only is there vast clinical evidence on the side of the physiological saline solution, but experimental research is very strongly in its favour. The operator would do well to avoid

being led, except for very special reasons, to use any medicated solutions in the pursuit of intra-ocular antisepticism.*

Tenacity of Prejudices.—It would seem rather strange that, whilst surgeons have in the operative

* At an opportune moment, Nuel and Cornil published observations on the action of various agents on the endothelium of the anterior chamber. They found that the contact of even pure water was mortal to the endothelium, that the physiological solution of chloride of sodium is inoffensive, that the solution of mercuric salts kills all the endothelial layer of the cornea even at a dilution which does not kill microbes. Amongst antiseptic solutions, the solution of boracic acid alone does not exercise any action on epithelial cells.—*Archives d'ophthalmologie*, 1890.

It is true that the endothelium destroyed by contact with pure water and by various agents is regenerated, but still it is wiser to avoid even this, for it cannot be beneficial. The solution of boracic acid is a very weak antiseptic, and is useless for antiseptic purposes. But the evil effect of mercuric salts is not limited to the destruction of the epithelial cells referred to by Nuel and Cornil. Clinical experience has shewn that mercuric salts are liable to form combinations with, and to be deposited in the corneal structures, to cause corneal inflammation of a peculiarly obstinate and dangerous character, and to lead to indelible corneal opacities.

The subject of intra-ocular antisepticism in cataract operations is so instructive and full of warning that it is well to refer to it here with a little detail. Shortly after I had made known my method of using irrigation as a mechanical force, Professor Panas, impressed with the idea that iritis, and other inflammations after operations was due to germs which somehow got into the eye during operation, adopted intra-ocular injection for antiseptic purposes. He used a solution of biniodide of mercury, one part in 20,000 of distilled water, to inject into the anterior chamber after the removal of the lens. Panas had many followers, but fortunately the evil effects of the mercuric solutions were soon discovered, and intra-ocular antisepticism, a baneful graft on simple intra-ocular irrigation, has happily almost altogether fallen into disuse. Professor Gayet had a remarkable experience. He states that during the summer of 1885 he had numerous suppurations of the eye after cataract operations, and he naturally thought they were owing to want of rigorous antisepsis. He then used irrigation chiefly in the wound with a solution of perchloride of mercury, one in 6,000, a little of the liquid entering the anterior chamber. The habit of irrigation having been formed, Gayet irrigated more freely, remarking the evacuation of blood and the debris of the lens. With these prolonged irrigations, the inconvenience of the perchloride soon became manifest, a considerable number of the cases at the first dressing shewed a more or less greyish tint in the cornea, which he considered owing to the local action of some irritant. To ascertain whether this greyish tint was owing to the action of the perchloride he made the following experiment. He operated on the same day on 20 patients—in 10 he irrigated the anterior chamber with a mercurial solution, and the other 10 with water which had been boiled; not one of the eyes irrigated with water showed any corneal trouble, whilst all those treated with the mercurial solution had the characteristic tint. An interesting accident occurred at a period after he had abandoned mercurial solutions for intra-ocular irrigation. Four or five patients presented corneal opacities like those observed in previous years, and another series of cases were similarly affected. It was found that a new infirmary attendant had mistaken a bottle of a solution of mercury for one of sterilized water, and had taken the former, and handed it to Gayet, who used it for irrigation. The results were disastrous. The opacities in the substance of the cornea were persistent. Some of the patients who returned two years after presented opacities as dense as at first, and had gained nothing by the operation.

treatment of cataract introduced needles, knives, scoops, curettes, and suction instruments into the eye millions of times, dreadful consequences should have been apprehended from the introduction into the eye of a drop of pure water or of a solution of like constitution to the aqueous humour. I should not refer to this were it not that old and vulgar notions die hard, retaining for a long time their hold against reason and common sense. Since 1884, however, the accumulated experience of surgeons in all parts of the world should be so great as to convince the most timid and doubting that careful irrigation with the physiological saline solution under antiseptic precautions is harmless. Yet within the last few years surgeons of eminence have expressed opinions not in advance of that of Sir David Brewster's critic, quoted in foot-note.*

Exclusive Charge of Irrigator by Experienced Nurse.—It will be obvious that in a matter involving such care, knowledge, and responsibility, the whole charge of the preparation and management of the apparatus should be in the hands of a thoroughly reliable and intelligent person. Here experience counts for so much, that the surgeon should have trained to this duty a nurse in whom he has absolute confidence. Such a nurse, from observation of the course of operations, knows

---

* I have met with an observation on this subject of curious interest. Sir David Brewster, the eminent scientist, thought at one time he suffered from cataract, and in a paper in the *London and Edinburgh Philosophical Magazine* of January, 1838, propounded his views on cataract, and, amongst other things, said: "If the cataract had made greater progress and resisted the simple treatment which was employed, I should not have hesitated to puncture the cornea in the expectation of changing the condition of the aqueous humour by its evacuation, or even of injecting distilled water or an albuminous solution into the aqueous cavity."

A writer, signing himself "J. H.," evidently *au courant* in ophthalmic matters, comments as follows in the *Dublin Journal of Medical Science*, of May, 1838:—"The mere letting out the aqueous humour might possibly have been unattended with any great harm, but from the second plan it is reasonable to suppose that the wound of the cornea, its irritation by the pipe of the syringe, the forcible introduction of a strange fluid among the delicate textures of the eye, would have produced such an inflammation as would have cost Sir David Brewster that precious organ—a dear price to pay for a theory."

exactly what to do without being told. Indeed, any directions, as I have seen, may be dangerous. Suppose the needle or nozzle is in place, and the surgeon is obliged to give even a word of directions to the nurse, the patient may think the observation made to him, and may comply with the supposed directions, with result not desired. For example, if the surgeon direct the nurse to elevate or lower the flask by saying the words "Up" or "Down," the patient may look up or down, as I have seen. With the present arrangement of all the needles and nozzles with the central stem, however, I have now a controlling power over the force which I previously lacked.

CHAPTER VII.

OPERATIONS.

My great object being to extend the field of cataract operations by dealing with the cortex efficiently, it occurred to me at first that I might limit my observations to that single detail, but it has appeared to me evident that such a fragmentary treatment of the subject would be unsatisfactory—for in different stages of various operations the method advocated for the treatment of unripe cataract obtrudes itself for other minor purposes—I therefore, for the sake of brevity, state shortly the modes of operation which I have followed.

I think, for all ordinary cases of cataract, complete and incomplete, the following modes of operation will be sufficient, viz.—1st, The Needle Operation; 2nd, Simple Linear Extraction; 3rd, Wecker's 3 Mm. Flap; 4th, Iridectomy in the Exceptional Cases of Zonular Cataract in which the clear lens area is pretty large, and without signs of the spreading of the opacity.

Before entering on a description of the operations, to avoid repetition I think it well to give full details in relation to the technique of intra-ocular injection and irrigation.

Technique of Intra-capsular Injection by Hollow Needle.—The needle should be secured by the surgeon by holding the rubber tube, covering the central pillar, between his thumb and forefinger, as in Fig. 38. The

water should be pumped through to see that the needle is not obstructed, and to start the syphon action. The needle being so fine, the syphon action is not often so great as to give a stream of sufficient force to escape when the needle is introduced inside the capsule. As a preliminary the surgeon should always observe the force with which the liquid escapes.

Care should be taken to prevent dropping of water from the needle on the eye or on the lids, as involuntary motion of the eye or the lids is, according to my observation, far more likely to occur from this simple cause than from free intra-ocular injection or irrigation. The flow should, therefore, be stopped before introducing the needle by pressing the rubber tube on the central pillar.

Whether the section be made above, below, or vertically, the needle should be placed on a line with and nearly parallel to the incision, and made to glide in by a gentle lateral motion. When in the anterior chamber, and safely guided over the iris, if iridectomy have not been performed, it is to be passed gently inside the capsule of the lens and directed superficially under the capsule, as shown in Fig. 3, Plate I., and not towards the centre of the lens. When there is abundance of soft cortex the needle may be promenaded freely. When in place, the grip on the needle being relaxed, the water may escape through the syphon action of the tube, the force being regulated by the elevation of the flask. Should the flow, however, not take place, as is probable, the fluid should be pumped by the finger and thumb of an assistant, acting on the rubber tube on any convenient part. (See Fig. 48.)

The amount of the injection is perfectly under the control of the operator.

When the lens is sclerosed, it may not be possible to introduce the needle inside the capsule, and when there

is evident resistance the surgeon should desist in the attempt, regarding the difficulty, as elsewhere remarked, as diagnostic of sclerosis.

Technique of Intra-ocular and Intra-capsular Irrigation.—The preliminary steps are just the same as for intra-capsular injection by the fine needle, the nozzle being substituted for the needle. But if both the injection by the fine needle and irrigation by the nozzle be required on the same day, it would be more convenient to have separate bottles and tubes for each.

The same care should be taken to prevent dripping of the fluid on the eyeball or margins of the lids.

The fluid may be introduced in four ways—

(1.) By depressing the sclerotic side of the incision by pressure of the nozzle upon it.

(2.) By introducing the nozzle inside the wound.

(3.) By introducing the nozzle well into the anterior chamber.

(4.) By introducing the nozzle behind cortex, and if the cortex be inside the capsule the surgeon is sure of carrying out perfect *intra-capsular* irrigation.

The varieties of intra-ocular irrigation stand as regards efficiency in the order in which they are specified.

When the scoop nozzle, with the slight ledge on the end, is used for cases of very resistant cortex, a slight to and fro motion of the nozzle when placed behind the cortex, but not in any sense a leverage motion, whilst irrigation is going on, aids materially in removing it.

When extraction is performed without iridectomy, and there is a prolapse of the iris after expulsion of the lens revealing the presence of peripheral cortical

substance, it is well not to return the prolapse immediately, but to introduce the nozzle over the iris into the anterior chamber and irrigate.* In this way irrigation on the exposed cortex has much more effect.

Sometimes when irrigation is going on the iris is pressed backwards, and the anterior chamber becoming apparently very deep, and the cornea assuming its full prominence, the operator may fear some accident. This condition, in case there is no obstruction to the exit of the fluid, only indicates that the space which formerly contained both aqueous humour and lens has resumed its normal relations, and that the iris by the current of water has been pushed back into the position formerly occupied by the posterior capsule of the lens. Whilst the condition of the parts shews that the fluid instead of disarranging the relations has in great measure restored them, it is a hint that further exercise of the same force would not be judicious, and that on the contrary it should be diminished or stopped for the time. Further, the depression of the iris whilst it shews force likewise demonstrates that that force is not exercised in the most effectual way. For if any cortex is imprisoned in the capsule the fluid actually whilst pressing the iris backward likewise presses the anterior capsule on the cortex.

Figs. 7, 8, and 9, Plate II., represent nozzles in different positions.

Needle Operation. — The needle operation is indicated in young children (see Fig. 40). The instruments required are those mentioned in Chapter V. Before operation the pupil should be dilated with atropine. The operation consists in the introduction of the needle through the cornea near the periphery, the passing

* Cataract operation without Iridectomy.—Cant, *The Lancet*, 25th October, 1890.

PLATE V.

Needle Operation and Simple Linear Extraction.

Fig. 40—Needle operation.

The following figures on this plate represent the various stages of the operation of simple linear extraction, with injection and irrigation :—

Fig. 41—1st stage.

Fig. 42—2nd stage—Introduction of fine needle for injection.

A.—Position of needle before introduction, nearly parallel to wound.

B.—Needle through wound and inside capsule of lens.

Fig. 43—3rd stage—Cystotome tearing capsule.

Fig. 44—4th stage—Expulsion of soft lens.

Fig. 45—5th stage—Irrigation with nozzle in wound.

In this operation it will be noted that the speculum is kept in place during all the stages except the 5th stage.

PLATE V.

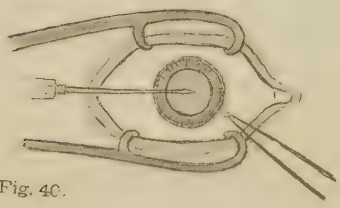

Fig. 40.

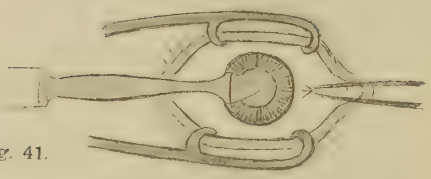

Fig. 41.

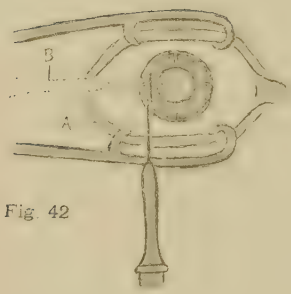

Fig. 42

Fig. 43.

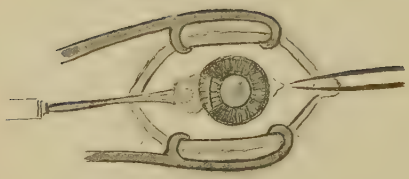

Fig. 44.

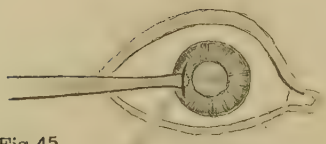

Fig. 45.

of the point into the area of the pupil, and the incision of the capsule to the extent of about a line and a-half, and the repetition of a like operation as circumstances may indicate. The only remark I think it necessary to make is in condemnation of the method of conducting the case in such a manner as to take many months in the process of absorption. For in this way a great and prolonged effort is cast on the absorptive capacity of the eye, and there is liability to the thickening of the capsule, and proliferation of the intra-capsular cells, and formation of a secondary cataract. I am of opinion that except in very young children it is better to run the risk of rather a quick swelling with early extraction by a linear incision, especially now when irrigation may be relied on to free the eye from lens matter in a way which could not be previously done.

There is no precise limit as to the age at which this operation should be done, but when a child reaches an age at which it can be controlled and guided more or less by reason, linear extraction either immediate or following a previous needling should be resorted to.

Simple Linear Extraction.—This operation is applicable to persons up till about 30 years. The instruments required are those elsewhere mentioned.

The speculum having been applied, and the conjunctiva and subconjunctival tissue seized by forceps at the inner part, the knife is introduced through the cornea at a point corresponding to the pupillary margin when the iris is in medium dilatation, and thrust across anterior chamber in front of the iris (see Fig. 41). If the cortex is striated, segmented, or not uniform in appearance, it is well to introduce the fine needle inside the capsule of the lens (Fig. 42), and to inject a little of the physiological saline solution, already described, warm.

The operator, as already hinted, must take care not to use the hollow needle with the view of evacuating the greater part of the lens. For if he did so he might clear out the greater part of the cortex in the area of the pupil only, through an insufficient opening in the capsule, leaving masses unaffected behind the iris. He would find it impossible, in such circumstances, to enlarge the capsular opening by the cystitome (Fig. 43) without great risk of opening the posterior capsule, and thus causing the escape of vitreous. The object of the needle is not really to clear out cortex, but rather to separate the lens from its capsule, and to disintegrate the substance of the lens quietly and slowly by the action of the liquid. After the cystotomy as much of the lens as possible is pressed out in the usual way by the action of the forceps on the inner part of the eyeball, aided by the curette pressed upon the sclerotic side of the valve-like wound, or introduced into it, and turned laterally so as to cause the wound to gape a little (Fig. 44). Should the whole not escape, irrigation may be done by the finest nozzle placed in the wound, and in rare cases a little in the anterior chamber (Fig. 45).

Wecker's Three-Millimetre Flap.—This operation is applicable to persons of 30 years and upwards. The instruments required for this operation have been mentioned in Chapter V.

I assume that the cataract is incomplete, and requiring both intra-capsular injection by fine needle, and, after expulsion of the nucleus, the removal of cortex by one of the various methods already mentioned. The following in such case are the stages of the operation :—

1st Stage—Section above by Graefe's knife at the junction of visible cornea and sclerotic, of three millimetres in depth or thereabouts (see Fig. 46).

PLATE VI.

The figures on this plate represent the various stages of the operation for cataract by Wecker's section, with iridectomy, injection, and irrigation.

FIG. 46—1st stage.

A.—The speculum.

B.—Fingers of assistant holding speculum, so as to prevent patient pressing the speculum against the eyeball.

C.—Graefe's knife, with puncture and counter-puncture at corneal margin.

D.—Holding forceps.

FIG. 47—2nd stage—Typical iridectomy.

FIG. 48—3rd stage—Speculum has been removed.

A.—Forefinger of surgeon pulling up upper eyelid, and securing it by pressing it against orbital margin.

B.—Finger of assistant pulling down lower lid.

C.—Fine needle for injection, introduced inside capsule.

D.—Lens bulged forwards on injection, causing pupil to dilate widely.

E.—Dotted line representing excursions of needle inside capsule in cortical cataract.

FIG. 49—4th stage—Pricker used freely.

FIG. 50—5th stage—Expulsion of body of lens.

FIG. 51—6th stage—Irrigation.

A.—Nozzle in wound and slightly in anterior chamber.

B.—Cortical remains.

C.—Iris contracted under irrigation, causing pupil to return to normal condition, as shewn in Fig. 47.

It will be observed that in the 3rd, 4th, 5th, and 6th stages the speculum is not used, and the eye is not fixed.

PLATE VI.

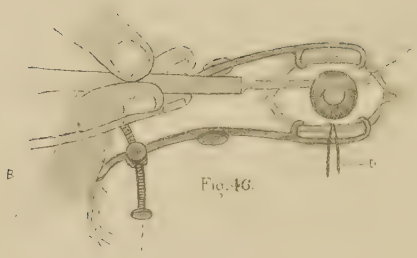

Fig. 46.

Fig. 47

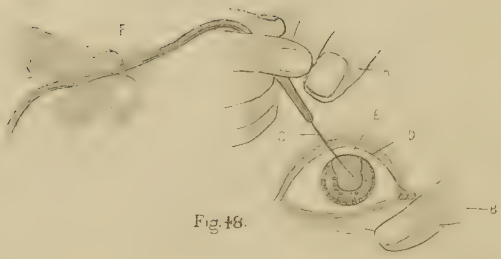

Fig. 48.

Fig. 49.

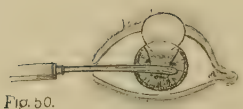

Fig. 50.

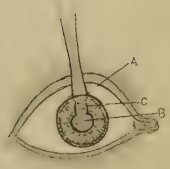

Fig. 51.

2nd Stage—Small iridectomy. As a rule, iridectomy should be performed in incomplete cataract; however there is no advantage, but I think a disadvantage, in a large iridectomy (see Fig. 47).

After iridectomy, but not because of it, but rather from a section too much in the sclerotic, the anterior chamber may be filled with blood. This is a very irritating occurrence, for which various expedients have been tried often without success. The ordinary resources are—Pressure through the cornea, massage, introduction of a curette into the wound to make it gape, the seizure of the conjunctiva by forceps over external rectus to make pressure on the ocular contents. The quickest way, however, to get rid of or diminish the obstacle is to irrigate the anterior chamber and rupture the capsule of the lens as quickly as possible. Once the lens comes forward there is at this stage no more trouble from hæmorrhage in anterior chamber.

3rd Stage—The introduction of the fine needle inside the capsule of the lens. This requires careful attention to the character of the cataract, and a clear understanding of what is intended to be accomplished. If the cataract is the striated, flaky, semi-transparent form, the needle is easily introduced, and the water either flows through syphon action or may be pumped, as already described, by an assistant. If on a little irrigation or pumping, in a case not far from the complete stage, a quick change becomes manifest, then it is better to remain satisfied with a little; but if it is evident that the cortical alterations are very incomplete, it is well for the operator, as noted elsewhere (see p. 59), to sweep the needle round freely just under the capsule, tearing off the capsule widely, whilst the irrigation or pumping are going on all the time (see Fig. 48). I have always regarded this

procedure as perfectly safe, and free from any risk of causing prolapse of the vitreous in the forms of cataract with a large quantity of cortex. Should the cataract be of the nuclear form, however, the surgeon must be on his guard not to mistake a hard sclerosed clear cortex for a soft clear cortex. I have dealt with the various elements to be considered in forming a diagnosis. If the fine needle do not enter readily it must not be forced, but the difficulty of introducing the needle must be regarded as strong evidence in favour of sclerosis and an indication that the lens will be easily and completely extracted.

There are two sorts of cases in which I have regretted not using the needle, and in which I have met with difficulty. They are—1st, Cases of nuclear cataract which have progressed rapidly, involving the cortex to such an extent as to abolish vision, but in which, after iridectomy has been performed, the lens seems more clear than expected. This sort of case is uncertain in its behaviour, and it would be well to try the needle at any rate. 2nd, Cases in which there is a semi-transparent, pretty uniform opacity of the cortex, and of which examples will be found in Table IV. I have been deceived more than once by this sort of cataract. Whilst there is any transparency this sort of lens is sometimes very difficult to extract, and I am satisfied injection by the fine needle would usually separate the cortex from the capsule.

It is an absolute rule never to be forgotten that the needle must be introduced quite superficially and never directed towards the centre of the lens. I have never fixed the eye during the insertion of the needle, and do not separate the lids by the speculum, either during injection by the needle, or subsequent stages of the operation. I myself, with my left forefinger, or fore and

middle fingers together, elevate the upper lid, whilst my assistant depresses the lower lid. I am always ready to withdraw the needle in any wrong movement of the eye. For other reasons than those usually advanced, I think it would be a disadvantage to use a speculum and fix the eye with forceps, as I consider the premature forcing of the lens out of its capsule is to be avoided. I wish, on the other hand, to let it stay in its place for a time that the fluid may take effect, and the lens come out of its capsule more completely. Fixing of the eye would tend to premature escape. In a word, I want to secure, in cases of incomplete cataract, slowness, and not quickness nor apparent brilliance, in performing the operation. The operator may be greatly surprised at the apparent quick opacification of clear cortex in nuclear cataract, but he will find on extracting the lens that it will appear transparent, so that the alteration observed in the lens is superficial.

I have only stated what my practice is in relation to not fixing the eyeball. It is, however, not an essential detail, and other surgeons may find it more advantageous, and more in accordance with what they have been used to, to fix the eyeball during intra-capsular injection.

4th Stage—After waiting a short time I introduce the cystitome to make sure of free separation of the capsule (see Fig. 49).

5th Stage—Pressure is made by Daviel's curette in the usual way to evacuate the lens (see Fig. 50). I do not think the ordinary horn spoon used for expulsion is better than the curette, for the convexity of the curette when pressed upon the cornea more resembles the curve of the posterior surface of the lens.

6th Stage—Cortical substance is evacuated by irrigation in one of the ways described in Chapter IV.

(see Fig. 51). Massage by pressure of the finger through the lids, exercised on the periphery of the cornea, may bring into view a part of the cortex coming from behind the iris. Several times the pupil may seem clear only to be filled up again by cortex previously unperceived.

It is certainly well, if possible, not to leave any cortex at margin of pupil, for what may seem small is probably only part of a larger mass lying behind the iris. There may occasionally be a filmy opacity, most frequently seen after hæmorrhage into the anterior chamber, and the character of which may not be easy to determine. The capsule itself, too, independent of this cause, may appear more or less opaque, and yet have no layers of cortex adherent. The electric or acetylene light thrown on pupil whilst gentle irrigation is going on will commonly let the surgeon see what is the character of the opacity he is dealing with.

Irrigation for Toilette of Wound.—Various methods for effecting the toilette of the wound by curettes, forceps, and spatules are described, but whilst these are at times necessary, irrigation generally effects more than any of them, and more gently. Irrigation has a tonic effect on the iris, and sometimes unaided is effectual in replacing the angles of the iris. It performs the toilette of the wound in a very perfect way, and may reveal imprisoned capsule.

When iridectomy has not been performed, the same course is to be followed.

It must not be forgotten that the surgeon in irrigation should be guided by prudential considerations as well as by ideas as to perfection of operation. For at times the pursuit of perfection may be more hazardous for ultimate results than stopping the operation short of ideal completion.

Whilst very bright artificial light is so valuable it may cause the surgeon to see parts so distinctly as really to give the idea that there is an opacity from cortical substance when there is not any, but only a slight haze from capsule seen under new conditions. Experience is the only safe guide in the decision.

I do not think it necessary to describe any other methods of extraction operations. I have performed various methods of extraction at different times within the last twenty-five years, but am satisfied that Wecker's has given me more satisfaction than any of the others.

Injection and irrigation can be used in every method of extraction save that in which the lens is removed in its capsule.

When Section Downwards should be Made.—The section should be made below in case of Morgagnian cataract, so that the nucleus, which falls down by force of gravity, or may be pressed down, may readily present at the wound, or, if it do not, may be easily scooped out. For obvious reasons, an upper section may entail the fishing out of the lens by a hoop or scoop under difficult circumstances, with probable loss of vitreous.

It is an untoward circumstance at any time to have to extract a cataract of any sort in the case of a patient of extreme nervousness and unsteadiness without general anæsthesia, but those who operate without such aid calculate the advantages and disadvantages. Mere local anæsthesia of the most perfect kind does not surmount the difficulty, for we are confronted with mental apprehension and physical instability, over which local anæsthesia has no influence. It is obvious that the administration of chloroform is the remedy, but, as a rule, when the surgeon makes the discovery in the middle of an operation, he prefers under the circumstances to take the risks

incident to the operation without anæsthesia rather than the excitement, struggling, and loss of control during the administration of the anæsthetic. When, however, an operation is to be performed on the second eye, being forewarned, I make a downward section. In this way the motion of the eye upwards, which is so annoying with the upper section, is really a help in the expulsion of the lens, and irrigation can be readily enough performed through a wound so situate.

Variations of Section.—When the surgeon believes that the lens is very small, and likely to have such relation to the cornea that the vitreous would be opposite the section, it would be well to cut out in the cornea a little from its margin. Likewise, in case of slight luxation, the section should be so made that the lens would be likely to present at the wound.

Iridectomy in Zonular Cataract.—This should be performed downwards and inwards when the cataract is so incomplete, as described, and vision, with the pupil dilated, 1/6th of the normal or more. The iridectomy should be small.

Should Iridectomy, as a rule, be Performed in Cataract Operations.—In incomplete cataracts I consider it should be the rule, as it certainly facilitates the removal of cortical substance. It will be observed in my tables that there are a considerable number of cases of the earlier dates in which it was not performed, but of late years I have practised it, both in complete and incomplete cataract, except in young persons, and for special reasons. I have not, however, made it a rule only because of greater certainty in removing cortex, but because of the frequency of prolapse of the iris

in the simple operation, and the inferiority of the visual results to the normal average when that unfortunate accident takes place. I discuss the question at length in Appendix.

ACCIDENTS AND CIRCUMSTANCES DURING OPERATION.

Difficulty of Introducing Hollow Needle.—This is a circumstance whose diagnostic and prognostic importance have been already discussed.

Prolapse of Vitreous.—The anatomical conditions in incomplete cataract, as a rule, favour injection and irrigation, and it is satisfactory to observe, too, that those cases of incomplete cataract in which injection and irrigation are especially valuable are precisely those in which those methods can be used with the greatest freedom. For, in the cortical cataract, the needle can be introduced into the soft cortex, and free injections made without danger of dislocating the lens or doing any other physical injury. So after the body of the lens has been expelled, free irrigation may be practised confidently in incomplete cataract, the suspensory ligament of the lens being, in such cases, not weakened by degenerative changes.

In the early years of my practice of injection and irrigation I had too frequent prolapses of vitreous; but for several years, owing to greater perfection of the instruments, prolapse is very rare. It may occur at different times. If it occur immediately after making the section, then injection and irrigation are out of the question, and the lens must be scooped out by spoon or vectis in the usual way. If, during an attempt to introduce fine needle inside the capsule, the course is just the

same as if prolapse occurred during the use of the cystitome, the lens must be scooped out. If, during irrigation to remove cortical substance, the irrigation as a rule should be suspended, occasionally it may be attempted with some success. If the surgeon can see his way to fish out cortex with the ordinary scoop, at the expense of little loss of vitreous, he may do so, but I think the interest of the patient will often be best served by closing the eye and waiting events. If irrigation have had any chance before the escape took place, it is improbable that scooping will do any good.

High Tension during Operations.—It seems to draw too much on the faculty of belief to think that such extraordinary congestive or secretory changes as to cause "high tension" should take place immediately after the aqueous humour has been evacuated, much more so if the body of the lens have been extracted. It would mean actually that the remaining contents of the eye should at once assume so much larger dimensions as to more than take the place of both aqueous and lens. I therefore think we will be more near the truth if we regard "high tension" in most instances as simply the expression of muscular action.

It is possible that occasionally irrigation may, like any other detail of the operation, induce the condition described; but the cases which have come under my observation, and which are only a few, point rather to the supposed tension as being a coincidence, and not a result of the irrigation, for I have found that when "high tension" has occurred in one eye with irrigation, the same has occurred in the second eye without irrigation.

Case 62 is an example of apparent high tension, in which I was obliged to desist before complete removal of

the cortex. The other eye was operated on some time afterwards, and the lens was expelled immediately after completion of the corneal section immediately, the vitreous enclosed in its capsule afterwards presenting.

Cases 12 and 31 are cases of actual acute glaucoma before operation, occurring in the same patient at an interval of upwards of three years, and in which irrigation was, notwithstanding, successfully practised.

I cannot say that I have seen a single case in which an apparent increased tension could be attributed clearly to irrigation.

Operations on Traumatic Cataract. — The changes induced by an injury to the lens depend on such a variety of circumstances, and the conditions are so varied that it would be impossible to make a satisfactory classification, or lay down more than very general rules for guidance. The age of the patient, the character of the lens injured, the site and extent of the wound, the nature of the injuring body, the probability of the introduction of septic materials, the concomitant injury of other structures, as for example, the iris, ciliary body, choroid and vitreous, the displacement or swelling of the lens, the lodgment of a foreign body within the eye, the time after the accident at which the patient applies for surgical aid, are all matters requiring careful consideration. Putting aside those cases in which, from the extent of the injury, or from its site, the question is not so much the restoration of vision in some degree as the prevention of sympathetic ophthalmia, there are four sorts of cases as regards the course they take which are seen pretty frequently :—

1. Cases of cataract in young persons, in which the process of softening pro- These may get well without surgical treatment, but it is much better to extract

ceeds rapidly and without pain.

by small linear section. If the wound be small, and caused by a clean instrument, if nothing has been done to inoculate the wound, and especially if the wounds have been properly treated by a germicidal lotion of sufficient strength, say 1 in 4,000 of chinosol, applied for a sufficient time, if the opacification proceed with fair rapidity, and the iris have not been involved, if the pupil be well dilated, and if there be no pain, there is no need for quick interference.

2. In which pain and glaucomatous symptoms demand interference whether opacification has been complete or not.

These must be operated on at once, and when the cataract is sticky and incomplete, irrigation and injection render great aid.

3. In which the process is slow, and perhaps without marked pain, and finally comes to be arrested, leaving thickened tough capsule and a condensed and adherent lens, and this especially so when there has been even a slight injury to the iris and iritic adhesion. These

The complications of this class might have been prevented by more prompt and bold interference. It is certain that the lens could be more perfectly extracted early than after a slow and partial opacification has taken place, with proliferation of the intra-capsular

are the cases in which, from the very mildness of the symptoms, the surgeon has been tempted to adopt the *laissez-faire* policy.

cells and formation of iritic adhesions.

4. In which, after a wound, apparently comparatively trivial, in the course of 48 hours or less the corneal wound becomes unhealthy looking, a little pus appears in anterior chamber, the iris sodden, and the disease taking the course elsewhere described under the heading of septic iritic and choroiditis.

See observations, Chap. VIII.

The frequency of the third and fourth classes gives ground for thinking seriously whether our modes of dealing with traumatic cases should not be carefully reconsidered. Indeed, it is a question whether in many cases the wounds, when there is a strong probability of the wounding instrument or material being septic, the wound should not be enlarged if necessary, the lens immediately extracted, injured iris snipped off, and the anterior chamber and capsular sac thoroughly irrigated. I have now no doubt that in all cases in which the corneal wound is considerable or large, without regard to the nature of the wound or how caused, this would be the proper course to take.

I do not at present, however, report any cases of traumatic cataract.

CHAPTER VIII.

POST-OPERATIVE INCIDENTS AND TREATMENT.

I AM not aware of any incidents or accidents liable to occur after operation on incomplete cataract with the aid of irrigation, or of any special post-operative treatment different from or in addition to what may be met with and required in ordinary operation. To write, therefore, of these matters may seem beyond the main object of this work, but still there are some points which I think it well to emphasize, and which are often not touched upon, or only slightly, in works on cataract.

After the operation is completed, as a matter of routine, I allow a little solution of chinosol (1 in 4,000) to run between the lids, then place lint, wet with a like solution, on the lids, fill the hollows round the eye with cotton wool in the usual way, and apply a bandage. I think it well to bandage both eyes. If the patient be rheumatic or neuralgic I use dry dressing. The lids are sponged with the solution referred to on the second day. On the third day atropine is applied as well, and thereafter once or twice daily according to circumstances. It is a mistake in my opinion, except for very special reasons, to be in a hurry either to let the patient out of bed or remove the bandage. For within a few days, especially if the second eye is blind, there is little gain possible, and risk of accident is certainly increased.

All the advantage may be had by allowing the patient to sit up in bed. So early removal of the bandage causes patients to think they are better than they really are, and rather encourages them to take liberties even though expressly forbidden. If people were always sensible and careful the case would be different. At any rate I know that it is not unusual to be obliged to re-apply the bandage after an early removal.

For many years I have not confined patients in dark rooms. I think moderate light instead of being injurious is beneficial.

No more attention should be given by the surgeon and nurse than is absolutely essential, for apparent want of solicitude or anxiety acts as a powerful mental tonic.

It is of much importance that the patient should be saved from any distracting and disturbing influence. I have seen on several occasions much injury from the conveyance of bad news by indiscreet friends, and hence I am careful, if I have any suspicion, especially in patients of a nervous excitable temperament, to warn visitors against conveying any intelligence of an unfavourable character. Worry and anxiety, the consequent loss of sleep, and loss of appetite, retard very seriously recovery, and even when success seems assured may cause complications.

Suppuration of the Wound.—In suppuration of the cornea, whether after operative or other wound, and whether occurring early or late, I have followed for some years a uniform plan of treatment, viz., hot stuping, the frequent application of a germicidal solution (now it is the chinosol solution, 1 part in 4,000, previously it was of perchloride of mercury, 1 part in 4,000) always applied warm, sometimes the dusting into the

eye of iodoform powder, the occasional instillation of atropine, and the administration of alcoholic stimulants in the form best borne by the patient, and liberal diet of an easily digestible kind. The frequency of the use of the local remedies is regulated according to the severity of each case. In the most critical the hot stuping is used half an hour at a time every hour or two hours night and day, whilst when progress of the disease has been arrested the stuping is reduced according to circumstances. The application of the germicidal solution is carried out very thoroughly and quite differently from what is done at the time of operation. I am not satisfied with mere instillation, but ensure prolonged contact of the solution. I take advantage of the natural conformation of the parts to give the eye a real bath. The head of the patient is turned slightly towards the other side, whilst the chin is elevated and the vertex lowered, causing the eye to be situate in the bottom of a cup. This orbital cup is filled with the solution, and the patient is directed to open the lids, and to keep them open as much as possible. This bath is continued for ten minutes. In this way the wound is saturated with the germicidal agent, which in the strength prescribed is fatal to the ordinary pathogenic germs. Influenced by the remarkable restraining power shewn to be possessed by the merest trace of perchloride of mercury, I would use in these desperate cases the perchloride of mercury solution occasionally instead of the chinosol, notwithstanding the objections to its routine use which I have stated. When iodoform is dusted into the eye it adheres to the wound, and in this way its action, though not germicidal, may prevent fructification of germs, and is very continuous.

The local treatment described may be looked upon as directed towards phagocytosis, and to the destruction and sterilization of germs. The *long continued* application

of the germicidal and antiseptic agents is the essence of the treatment. If contact for a number of minutes with a solution of a certain strength is necessary for the destruction of germs, it is evident that the mere momentary contact obtained by dropping in a solution is useless.

The use of atropine takes only a secondary place, but should not be omitted.

As to the value of stimulants, regulated a good deal by the habits of the patient, I have no doubt. When a patient has been free in the use of them, and when his general condition obviously improves with their administration, they should be comparatively freely given.

If the suppuration occur within 24 or 48 hours in a patient whose health has been good the prognosis is very bad, as it would indicate a rather virulent septic inoculation which will quickly lead to panophthalmitis. If, however, it occur in a person who may have been in indifferent health, or not long recovered from depressing illness, the chances are much more favourable, as the suppuration may be less owing to virulence of the germs than to weakness of tissue vitality, which may to a considerable degree be remedied. I have operated on two or three occasions during the influenza epidemics on persons only a short time recovered from influenza, and of which I had not been informed, and though the symptoms were alarming I had the good fortune to secure good recoveries through the treatment indicated.

Slow Healing of the Wound.—From the usual directions given in books as to the period during which bandaging should be continued it would almost seem that the time could be fixed with arithmetical accuracy, but so far from this being the case the fact

is that the period varies very much, and does not seem to have always any direct relation to the apparent health or age of the patient—for in one case the bandage may be removed in a week, in others not for ten days, a fortnight, three weeks, and occasionally not for five or six weeks. The very slow healing with long continued emptiness of the anterior chamber, though for a time not alarming in appearance, entails the gravest consequences.

The iris in a little time becomes involved, adhesions form to the capsule of the lens and to the wound, the capsule slowly opacifies, the cornea likewise becomes opaque to a variable degree, and the surgeon is in the unhappy position of being an almost resourceless spectator.

I have seen several cases of this kind.

I have met with a record of four similar cases in the Annales d'Oculistique, of September, 1895, by M. le Docteur de Speville, under the description of "L'aplatissement prolongé de la chambre antérieure après l'extraction du cristallin." In three of these cases a late iridectomy was followed with restoration of the anterior chamber, but the explanation is difficult to give. In the fourth case nothing was done, and in six months after the operations the anterior chamber was not restored.

De Speville states the conclusion to which he has come, and as I have no advice to give from my own experience I copy his own words as follows :—

"La conclusion qui découle de ce qui précède est que si, après une opération de cataracte, la chambre antérieure n'est pas retablie an bout de trois semaines à un mois, et si la cornée presente, même avant ce lapse de temps, un léger trouble, il faut sans hésiter faire une iridectomie. Cette opération rétablira immédiatement la chambre antérieure et, faite à temps, mettra a l'abri du processus glaucomateux et du trouble cornéen."

Valude, commenting on the paper of de Speville, says :—

"J'ai eu l'occasion d'obsérver plusieurs de ces cas, ou la chambre antérieure a mis un très long temps à se réformer, et j'ai publié ces faits à plusieurs reprises (*France Medicale*, 1891, 30 Janvier, et *ibid*, 1894, 6 Avril). J'ai noté que ce défaut de cicatrisation coincidait généralement avec le diabète on l'albuminurie, à ce point que, lorsque je n'ai pas examiné l'état des urines d'un malade, le ralentissement dans la formation de l'humeur aqueuse me fait songer a l'existence de l'une de ces dyscrasies. J'ai aussi noté et indiqué comme conclusion a mes obsérvations que le seul moyen de hâter la réformation de la chambre antérieure était de pratiquer l'iridectomie ; ceci se trouve corroboré par les obsérvations ci-jointes."

Total Want of Reparative Power of Cornea.—I have met with one case which can only be described under this heading. It is now many years ago. He was a man about 60 years of age, thin and active. He had suffered like many cataractous patients some privations, but I saw nothing to deter me from operating.

I operated on one eye. Not only did no healing whatever take place, but the cornea just suffered a slow molecular death. Little by little the cornea disappeared, the loss beginning at the margin of the wound and gradually extending without any pain. The vitreous which remained quite normal was more and more exposed, and ultimately it was evacuated. This process went on for upwards of a month. After this the part healed, leaving a small stump. Thinking that this molecular death of the cornea might be owing to his general health I kept him in hospital, and allowed him a liberal diet for some time. I operated on the other eye. This operation was followed by acute suppuration of the cornea, ending quickly in panophthalmitis.

I saw him about ten years afterwards hardly changed in his appearance.

Iritis and Irido-choroiditis.—When the operation has been satisfactorily completed, and especially cortex completely removed, and when healing of the corneal wound follows the normal course, iritis of any gravity is rare.

When the iritis is secondary to abnormal processes in the corneal wound the treatment must be chiefly directed to the treatment of the wound, but when it seems to occur more or less independently special attention must be given to the iritic condition, and not only must the character of the iritis be observed, but attention must be given to the general health and history of the patient.

If the iritis occur in a person of vigorous health within a few days after the operation, there can be no doubt that general blood-letting from the arm is a potent remedy. It is really seldom that the surgeon is called upon to resort to this. I have bled from the arm only three times in twenty-five years, but certainly with great satisfaction.

If the patient is in indifferent health, and the iris shows evidence of a plastic exudation, the stimulating influence of hot stuping and administration of tonics are indicated.

When the inflammation occurs rather late, and shows itself with an irritability out of proportion to any evident changes in the iris or pupillary area, as a rule leeching or wet cupping of the temple is indicated, and usually gives marked relief. It may be repeated from time to time according to circumstances. Leeching is usually troublesome, and sometimes occupies a great deal of time, and, besides, leeches may not be at hand. The surgeon may effect his purpose very simply and expeditiously by making one or more punctures with a Graefe's knife in the temple, and abstract, by the aid of a cupping glass

with a hard rubber top, two or three ounces of blood. The mouth of the cupping glass should be about an inch and a-half in diameter. A small one hurts the patient more, and, besides, obstructs the flow of blood. It may be noted here that this is a much better and simpler method of abstracting blood from the temple than the Heurteloup artificial leech so much used in deep-seated affections of the eye. I have discarded that instrument for many years.

The abstraction of blood sometimes is of guidance in a diagnostic point of view. In cases such as I have just indicated, if, instead of the anticipated relief, there is on the contrary an aggravation of the symptoms, it is a contra-indication to a continuance of that line of treatment, and a pretty sure indication of neurotic temperament. The treatment must be directed accordingly. This leads me to considerations of a general character.

Whilst of course the primary cause of the iritis is the traumatism, the latter must be regarded as capable of starting into activity dormant or latent constitutional taints or tendencies. Indeed, to combat post-operative iritis successfully, it is necessary to bear in mind the aetiology of iritis in general, so we may have any of the types usually met with, such for example as septic, rheumatic, gouty, syphilitic, neurotic, malarial, or cachectic.

As to the septic, it seems to me pushing theory to extremes to look upon post-operative iritis as generally due to micro-organisms, from which idea the preventive intra-ocular antisepticism sprang. The true septic form hardly ever leaves room for doubt, and is so early in its onset, severe in its course, and usually so disastrous in its results, that the surgeon's hopes are soon ended. The picture of the true septic form afforded by injuries to the eye by penetrating wounds is so frequently under observation that it can hardly fail to be recognised. In 24 to 48 hours after such a wound, involving cornea, iris

and lens, the corneal wound becomes dirty greyish in colour, the iris becomes sodden, looking afterwards distinctly yellowish, the aqueous muddy, pus appears in anterior chamber, and the iris steadily becomes more sodden, swollen, and yellowish; the perception of light, which at first was good enough, diminishes rapidly from extension of the septic process in the posterior part of the eye, and finally is usually altogether lost; the conjunctiva is chemotic. The whole process only takes three or four days, and usually resists all treatment. That is a picture of septic inoculation, but it is now happily rare in operations. If it have taken place, then the question of treatment arises. Of course it must be directed, as in the case of corneal suppuration, to promote the vitality and the consequent resistance of the tissues to organisms, and the killing or rendering fruitless the offending germs or their products. Whilst these cases are truly desperate, yet it is satisfactory that occasionally there may be recovery, partial at least. I may note a case in point. Some time since I was called in consultation to see a young man of about 18 years old, for whom simple linear extraction for traumatic cataract had been performed two days previously. I found the corneal section dirty grey, anterior chamber cloudy, iris yellowish, a little hypopyon, intense conjunctival congestion, and the patient complained of much pain in and around the eye. The ordinary strict antiseptic precautions had been taken, and the only thing which the operator could call in question was an old solution of eserine, which he had instilled into the eye after the operation. Indeed, after he had used this it occurred to him that he had acted imprudently, and, accordingly, with a view to prevent possible inoculation, he dropped into the eye a solution of the perchloride of mercury. Hot stuping night and day were resorted to, with the frequent use of the solution of perchloride of mercury, the occasional application of atropine, and the internal

administration of mercury in the form of hydrarg cum creta. Happily, under this treatment, continued for a number of days, the disease was arrested, and the eye recovered with V.=1/3, and has since continued good.

The treatment I would now recommend would be the same as in the case of the young man referred to, with the exception of the use of the chinosol solution in the main instead of the solution of the perchloride of mercury, after the manner described for suppuration of the cornea and possibly the injection of solution of chinosol, one part in 8,000, into the anterior chamber.

Now, whilst there can be little if any doubt of the septic cause of the iritis in cases of the sort just described, the causation of the ordinary forms of iritis by introduction of germs is very hypothetical, and the hypothesis is not sufficiently reasonable to be looked upon as a good basis to work from.

But in addition to the true septic inoculation, leading too often to a panophthalmitis, there may be an iritis tending to suppuration occurring at a late period when all danger is supposed to be over, and without any obvious cause, and which may be owing to a cachectic condition and be of auto-genetic origin, and we know now that there may be suppuration without the presence of germs. I have now before my mind three cases of this class.

The first case was a man about 60 years of age in whom extraction had been performed by corneal section with iridectomy. The operation was perfect in every respect, the course was normal, the bandage had been removed after a week, and I regarded him as practically out of my hands. Iritis with pus in anterior chamber occurred within 24 hours after the removal of the bandage, panophthalmitis was manifest on the following day, and the eye totally lost. This was before the use of intra-ocular irrigation. The only explanation

I could give was that possibly the weather being excessively cold at the time, the eye, perhaps, exposed to cold or draught, and less resistant owing to the operative traumatism, and the health of the patient being below par from previous excessive alcoholic indulgence, an auto-pyogenic process started.

The second case was a man aged 56. He had been a hard liver. I extracted a complete cataract from one eye by Wecker's section above, without iridectomy, and I irrigated. The operation was perfect. I did not open the eye for several days, and I did not apply either mydriatic, myotic or antiseptic during the whole treatment. On the seventh day I operated on the other eye. Both eyes were bandaged for another six days. At the end of this time the bandage was removed from the eye first operated on. I had practically dismissed him from observation, but by chance looked at the uncovered eye the following day when shewing some cases to a professional friend. I found a little redness of the eye, with just a trace of pus at the bottom of the anterior chamber. Indeed it was so slight that it required careful examination to satisfy me that it was pus at all. The vision, which had been 20/20, was only a little reduced. I need not detail the treatment, but the disease steadily advanced from day to day for a week, so that vision was reduced to only good perception of light, and I expected panophthalmitis to ensue. It was difficult to decide on what to do in such desperate straits. I decided, however, to try and prevent panophthalmitis. I made a small corneal section, and injected a solution of perchloride of mercury (1 part in 10,000 of water). The disease was arrested, but the cornea became so opaque from the perchloride that an artificial pupil would be useless—the eye maintains its tension, the anterior chamber is normal, the pupil can be seen, and the perception of light is

very good. There was no ulceration of any part of the cornea at any time, and the opacity can have been owing to nothing else than the perchloride, just as Gayet's cases were.

Speculation as to the cause of this would be fruitless. Did I ever again deem it wise to inject an antiseptic into the anterior chamber I would select the chinosol solution. I have several times irrigated the anterior chamber in cases of severe suppurative keratitis with hypopyon with satisfactory results. It did not cause any opacity of the cornea like the solution of perchloride of mercury.

The third case was a lady about 60, who had complete cataract. I operated on right eye by section above and iridectomy. The operation was in every sense perfect. A little irrigation was used. The course was without incident. She left hospital in fourteen days quite well. I did not see her after leaving hospital for a couple of days. I then found an acute iritis. The only cause to which she could attribute this was great noise and vibration during paving the street at night, causing her to lose her rest and sleep. The disease progressed very slowly but steadily, and became an iridocyclitis with only perception of light. I learned that the eye was afterwards enucleated.

These cases were all examples of easy and perfect operations without a complication of any kind. No remnant of cortex, no incarceration, or iris, or its angles, in fact nothing to account for the disaster.

These cases I think are specially instructive, and warn surgeons against the folly of stating dogmatically that this or that thing is to be done in a certain number of days, and of thinking that even a fortnight without the slightest sign of anything amiss gives any warranty or security. Taught by experience, I like to

keep patients strictly under my eye for a little while after they seem to be well, and never lead anyone to expect under the most favourable circumstances to leave under three weeks.

Nervous Shock from Cataract Operation.—I do not find any special reference to nervous shock in works on cataract, except in relation to more or less mental disturbance in old people, but on close observation it will be found that in a very considerable number of cases the operation is attended with more or less nervous disturbance during the first 24 hours.

Many years ago when, for the sake of the patient, as I thought, I urged strongly, as a rule, operation on the second eye before the patient left the hospital, I found when the patient rather submitted to my will than followed his own inclination and instincts, the recoveries from such second operations were more slow and unsatisfactory than from the first operations. The patients besides, as a rule, bear operations on the second eye worse than on the first, without regard to the fact that after an easy and successful operation one would expect more confidence and courage. I have no doubt that the shock of the first operation, though not appreciated, and the lessening of the general health from confinement, though not prolonged, should be taken into account by the surgeon before advising the second operation. If the first eye recover promptly, and the patient is in good health and spirits, and desires operation, I make it a rule to operate on the second eye in about a week ; if not, it is better to postpone the second operation till the patient has had the advantage of air and exercise.

But besides the slight nervous disturbances referred to, there may be a most aggravated form, fortunately very rare, entailing great and immediate lowering of the

vitality, and compromising the result of the operation. It is in a sense a real nervous storm, as it were. It does not seem to bear any relation to the pain or duration of the operation.

The following is the case No. 141.

D. R., aged 60, M., had cataract on both eyes.

L. completely developed, R. incipient. The left eye was operated on without iridectomy, but a prolapse occurred which rendered recovery slow. A month after operation, the pressure bandage not having caused the prolapse to disappear, I snipped it off. Two weeks afterwards—viz., six weeks after operation on left eye—I operated at his request on the right eye, the condition of which is stated in the table. Shortly after the operation, on the same day, he became affected with the most intense headache, nausea, vomiting, total loss of appetite. Quinine, antipyrine, and other remedies were administered without effect. Stimulants were rejected by the stomach. I examined the eye from day to day for six days, but there was no swelling of the lids, no conjunctival congestion, no discharge, no opacity in the pupillary area, no keratitis, no exudation in the wound, and no healing of the wound. On the seventh day there was a slight exudation in wound. Persistent treatment by hot stuping and instillation of warm solution of perchloride of mercury were begun. Cloudiness extended on the cornea from the wound, iris became involved, and after a considerable period (I have not noted how long) the wound closed, but only after the eye had become irretrievably damaged.

I recognised this as an example of nervous shock, but I was at a loss to understand how such an easy operation should have resulted so gravely, and I did not know how to meet another such calamity should it ever occur again. Much light has been thrown on this

subject by a valuable practical paper by Sir Thornley Stoker, read at the Royal Academy of Medicine in Ireland,* in which he shows that surgical shock is not confined to severe operations, but may occur after the most trivial, and he indicates treatment which seems to me to be rational, viz., heat, stimulants by the rectum, and subcutaneous injection of morphia.

After all cataract operations hot jars are, as a matter of routine, put to the feet, because of the occurrence often of a sensation of cold and sometimes trembling.

SECONDARY CATARACT.

The reports of the operations for the various forms of cataract show a very small proportion of operations for secondary cataract, although the cases were precisely those in which experienced operators would have expected a large number. Of course I attribute this circumstance to the usual very complete removal of cortical substance by irrigation. It was not owing to removal of the anterior capsule, for it was not removed, nor to the performance or non-performance of iridectomy, for both these methods were in use, nor to natural separation of the cortical substance from the capsule, and the non-liability to proliferation of the intra-capsular cells advanced by some surgeons, for the cataracts generally had not reached that stage of evolution. By a process of exclusion there can therefore be only one cause for this relative immunity, viz., usually pretty complete removal of cortex.

Different operations are indicated according to the character of the cataract.

When of the first form, viz., a fine gauze-like folded membrane, the capsule retains its elasticity, and is easily

* "Transactions Royal Academy of Medicine," vol. XIV.

PLATE VII.

Operations for Secondary Cataract.

Fig. 52—Knapp's knife-needle introduced near periphery of cornea above, point reaching to lower margin of dilated pupil, to make section of capsule.

Fig. 53—Operation by two needles.

Fig. 54—Opaque capsule, covering greater part of dilated pupil. Iritic adhesion below, causing irregularity of pupil.

Small linear corneal incision opposite iritic adhesion.

Hook is introduced above opaque part, and through thin part of capsule.

Fig. 55—Opaque capsule is shewn drawn out of wound by hook, to be cut off close to wound.

Fig. 55—a, b, c, and d—Apertures in capsule of various shape after section by Knapp's knife-needle.

PLATE VII.

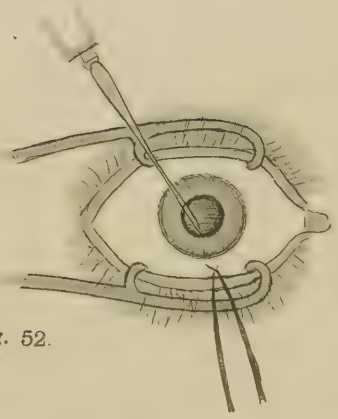

Fig. 52.

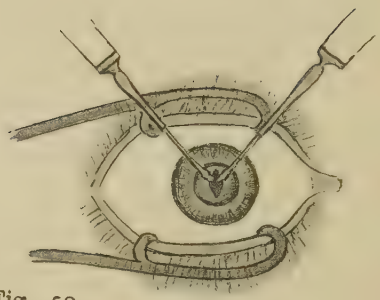

Fig. 53.

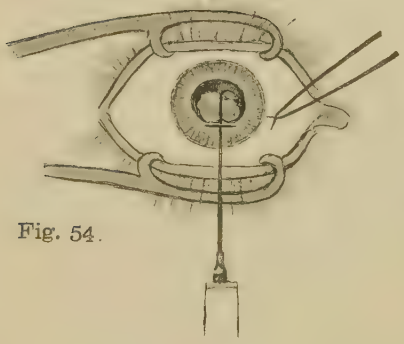

Fig. 54.

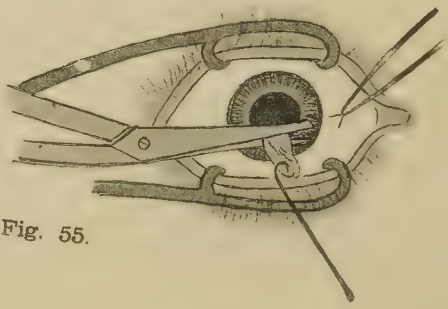

Fig. 55.

Fig. 55a.

Fig. 55b.

Fig. 55c.

Fig. 55d.

cut, and when cut it usually retracts, leaving a good clear gap in the capsule. Figs. 55A, 55B, 55C, and 55D show different forms and sizes of capsular opening without any design on my part. If the membrane have become altered from inflammatory changes the elasticity may be largely lost, and the cut in the capsule may turn out to be of different size and form from that expected at the time of the operation. I much prefer Knapp's knife needle (see Fig. 52) to the ordinary cataract needle, which I have practically put aside for years.

When the membrane is dotted and spotted, thickened at parts and thin at another, it may be possible to enter the Knapp's knife needle at the thin part, and make a sufficient section there. In some of these cases the thickened part, being so wanting in elasticity, may to a considerable degree resume its former position, and in such case, either for æsthetic or visual reason, it may be desirable to make a small corneal section, pull out the thickened capsule with forceps or hook, and snip it off, as in Figs. 54 and 55. These Figs. shew a safe way of removing such a partially thickened capsule even when there is an iritic adhesion.

I have sometimes performed the operation with two needles as in Figure 53, but I am not fond of the method.

In the cases of dense extensive opacity, with extensive iritic adhesions, the operation of iridotomy, which consists after suitable corneal section of cutting through the iris and false membranes with Wecker's iridotomy scissors, offers the best chance of results.

CHAPTER IX.

STATEMENT OF CASES.

THE following statement of cases is arranged in accordance with the plan of Classification in Chapter II.

The tables dealing with the most common and important forms of incomplete cortical cataract begin with the time of the adoption of the method of irrigation described, which I have continued till the present with only some alterations relating to minor details. They include all the cases during that period exclusive of those found to be complicated with deep-seated disease of the eye.

The other tables, some of them embracing cataracts of very rare occurrence, are not similarly limited to time, and include some cases operated on by a method practised by me at an earlier period, and designated injection by scoop syringe.

To show in a practical way the value to be attached to certain views in relation to age as a guide in forming an opinion as to the safety or danger of operations on cataract on persons of certain ages, I have sub-divided the most important classes according to age.

TABLE I.

Incomplete Cortical Cataract, Common Form, in Persons under 30 Years of Age.

There are few cases of this sort of cataract, as the surgeon is seldom required to extract incomplete cataract

at this age. These are incomplete structurally, but complete functionally with one exception.

No.	Age.	Sex.	Description of Cataract and Operation.	Result.
1	25	M	29*th May*, 1889. Striated and greyish. Vertical linear section of cornea without iridectomy. Removed large masses of cortex by irrigation. Cortex could not have been completely removed, as on opening eye a few days after operation there was whitish cortex in pupil which ultimately disappeared. Other eye operated on similarly two years previously. Sees 22/20 and 0·5 Sn. at 18 inches.	25*th July*, 1889. V.=20/60. 0·5 Sn. at 8 inches. This patient can see 0·8 Sn. at about 8 inches without any glass by pressing his lids together.
2	21	M	12*th December*, 1889. Can count fingers. Mother-of-pearl—segmented. Three or four clear spaces separating the segments. Small section of cornea above. No iridectomy. Injection by fine needle breaking up the lens and expelling large quantity. When I put in the pricker to rupture the capsule more freely the whole of the remains of the lens came out.	V.=Perfect result, but exact note not taken.
3	25	F	25*th August*, 1894. Striated. Vertical linear section without iridectomy. Irrigation.	V.=20/60
4	25	F	8*th November*, 1894. (Same patient as No. 3.) L. Striated. Vertical linear section without iridectomy. Irrigation.	V.=20/40. 0·5 at 10 inches.

Table II.

Incomplete Cortical Cataract, Common Form, in Persons from 30 to 60 Years of Age.

The following table embraces the second and third stages of the common form of cortical cataract within the

ages mentioned. They are examples of cataracts incomplete in structure, but almost all complete functionally:—

No.	Age.	Sex.	Description of Cataract and Operation.	Result.
5	30	M	*January*, 1889. Striated and swollen. Small flap section above without iridectomy. Injection by needle. Expelled large quantity of sticky, semi-transparent cortex by irrigation. After removal of cortex, pupil filled with pigment, which I washed out.	V.=15/30. 0·5 Sn. at 6 inches.
6	45	F	9*th April*, 1889. Striated. Section above with iridectomy. Washed blood out of anterior chamber. Injection by needle. Removed masses of cortex by irrigation.	18*th October*, 1889. V.=20/60. 0·5 Sn. at 9 inches.
7	44	F	30*th April*, 1889. Striated and flaky. Section above without iridectomy. Injection by needle. The lens came out very easily, only some cortex being left at upper part of pupil and behind iris above. A single irrigation removed the cortex. The other eye, which had been blind for four years, and in which the cataract was complete, was also operated on with like result.	21*st May*, 1889. V.=20/30. 0·5 Sn. at 18 inches.
8	55	M	24*th July*, 1889. Striated. Section above. Small iridectomy. Irrigation several times from outside. Large masses of cortex came from behind iris. Difficult operation, as patient had hardly any control. The other eye, which had been blind for 18 years, was operated on previously. A large quantity of grumous and gritty cortex was removed. The result was practically the same as in this striated cataract.	22*nd August*, 1889. V.=0·6 Sn. at 6 inches.

No.	Age.	Sex.	Description of Cataract and Operation.	Result.
9	48	M	25*th July*, 1889. R. Striated. Section above without iridectomy. Injection by needle breaking up cortex and tilting the body of the lens out of its capsule towards the wound. Used pricker nevertheless. Irrigation made pupil clear. The other eye was operated on a fortnight previously for a cataract complete in every respect, and with like result.	14*th August*, 1889. V.=20/60. 0·5 Sn. at 9 inches.
10	35	F	16*th October*, 1889. R. Striated. Affection began about six months before operation. Section above without iridectomy. Injection by needle. Very small nucleus expelled, leaving pupil full of cortex. Removed large masses of cortex both from pupil and from behind iris by irrigation. Several times pieces of cortex previously unperceived were brought into view from behind iris.	18*th November*, 1889. V.=20/60. 0·5 Sn. at 9 inches.
11	35	F	26*th October*, 1889. L. Cortex with transparent and mother-of-pearl patches. Section above with iridectomy. Injection by needle three times, breaking up cortex. Irrigation removed large masses of cortex. Electric light showed a film over part of pupil which seemed to be capsule slightly altered from contact with blood in the anterior chamber in early stages of operation, and which irrigation did not alter. Anterior chamber not restored for 14 days.	18*th November*, 1889. V.=20/80. 0·5 at 7 inches.
12	55	M	4*th April*, 1889. L. Striated and flaky. Swollen. Cornea small. Anterior chamber almost nil. Acute glaucoma. Reduced tension by eserine. Corneal section above. The iris coming before knife was cut off. Injection inside capsule by fine needle breaking up lens freely. Nucleus expelled easily. Tension of eye evidently very high. I therefore hesitated to irrigate, but tried to remove cortex by pressure and massage. This	V.=20/60. 6 years after operation.

No.	Age.	Sex.	Description of Cataract and Operation.	Result.
			proving unsatisfactory, I irrigated from the outside with success. The progress of the case was normal. He returned to hospital three weeks after his discharge with an attack of acute glaucoma ; tension high ; haziness of the cornea ; severe pain ; vision reduced to seeing fingers at one foot. Instillation of eserine completely cured the glaucoma. (The other eye, upwards of 3 years afterwards, became affected with cataract and glaucoma in the same manner. *See Case No. 31.*)	
13	45	F	12*th March*, 1890. Striated. Section above. Iridectomy. Injection by needle. Irrigation.	25*th April*, 1890. V.=20/40. 0·5 Sn. at 11 inches.
14	32	M	11*th June*, 1890. L. Flaky. Section above without iridectomy. Injection by needle. (The other eye contained the shrivelled, hard, cretaceous remains of a lens which was very difficult to operate on. That eye had been blind eleven years. The incomplete cataract of the left eye was much more easily extracted.)	1*st July*, 1890. V.=20/30. 0·5 Sn. at 11 inches.
15	32	F	12*th August*, 1890. L. Flaky. Section above. No iridectomy. Injection by needle breaking up lens very much. After expelling as much cortex as possible by pressure, the pupil was still full. Irrigation and massage alternately. On four occasions after irrigation, pupil seemed pretty clear, but was more or less re-filled by massage. Pupil round and clear. Lens was very sticky.	10*th September*, 1890. V.=20/60. 0·5 Sn. at 13 inches.
16	35	M	17*th August*, 1890. R. Striated and flaky. Section above without iridectomy. Injection by needle. After expulsion of nucleus several irrigations inside anterior chamber, but some cortex left.	9*th September*, 1890. V.=20/120.

No.	Age.	Sex.	Description of Cataract and Operation.	Result.
17	32	F	20*th August*, 1890. R. Flaky. Section above. Iridectomy. Injection by needle breaking up cortex. Free capsulotomy. The lens seemed to have been separated from the capsule by the injection. A mass of cortex at upper part of pupil removed by irrigation. Operation very easy when contrasted with a similar operation on the other eye. (Same patient as No. 15).	10*th September*, 1890. V.=20/60.
18	53	M	10*th September*, 1890. R. Flaky and mother-of-pearl. Section above. Iridectomy. Free injection by needle. Removed large masses of cortex by irrigation with nozzle in wound, alternating with massage.	30*th October*, 1890. V.=20/20. 0·5 Sn. at 14 inches.
19	41	F	10*th September*, 1890. L. Flaky, mother-of-pearl at places. Opacities vary much, some places slightly affected. Section above. Iridectomy. Free injection by needle. Irrigation with nozzle well within the cortical masses after the expulsion of the nucleus, removing all easily with the exception of a small shining opaque piece at inner margin of pupil, which was not affected even when nozzle directly behind it.	3*rd August*, 1891. V.=20/80. Requires section of capsule.
20	50	F	15*th January*, 1891. R. Segmented. Section above. Small iridectomy. Several irrigations removed cortex completely.	24*th February*, 1891. V.=20/60. 0·5 Sn. at 8 inches.
21	50	F	27*th January*, 1891. L. Striated. Section above. Iridectomy. Injection by needle. Irrigation by ordinary nozzle failed to remove a considerable amount of cortex. Finally removed it with the ledged irrigating nozzle, introduced behind the cortex. Same patient as No. 22.	24*th February*, 1891. V.=20/40. 0·5 Sn. at 7 inches.

No.	Age.	Sex.	Description of Cataract and Operation.	Result.
22	50	F	10*th February*, 1891. Flaky. Section above. Iridectomy. Injection by needle. Lens expelled easily. A few fragments removed by irrigation. On the third day anterior chamber was re-established; on the fifth day the wound was reopened with a little iris in angle.	10*th March*, 1891. V.=20/60. 1·5 Sn. at 6 inches.
23	40	F	28*th July*, 1891. L. Striated and facetted. Section above without iridectomy. Injection by needle. Irrigation. Great trouble in washing out cortex.	8*th October*, 1891. V.=20/30. 0·5 Sn. at 15 inches.
24	40	F	15*th September*, 1891. Striated. Section above without iridectomy. Irrigation removed large masses of cortex. Very restless after operation, and got out of bed without orders. Prolapse of iris. Discharged 28th September.	28*th September*, 1891. V.=20/80. 1·5 Sn. at 9 inches.
25	50	F	30*th September*, 1891. L. Striated. Section above without iridectomy. Injection by needle. Free irrigation cleared pupil.	2*nd November*, 1891. V.=20/30. 0·5 Sn. at 10 inches.
26	60	F	30*th October*, 1891. L. Striated. Section above without iridectomy. Irrigation.	4*th October*, 1892. V.=20/60. 0·5 Sn. at 6 inches.
27	42	M	6*th February*, 1892. R. Striated. Section above without iridectomy. Free irrigation did not clear pupil completely. Subsequently section of capsule by fine knife.	4*th May*, 1892. V.=20/30. 0·5 Sn. at 12 inches.
28	55	M	1*st March*, 1892. R. Striated. Section above without iridectomy. Large masses of cortex removed by irrigation with nozzle in anterior chamber. A small piece left at inner margin of pupil.	12*th April*, 1892. V.=20/20.

No.	Age.	Sex.	Description of Cataract and Operation.	Result.
29	50	M	*March*, 1892. R. Striated peripherally. In centre, cortex uniform. Section above. Iridectomy. Free irrigation did not clear pupil completely.	V.=20/30. 0·5 Sn. at 12 inches.
30	50	F	1*st September*, 1892. L. Striated. Patient very nervous, and therefore made section below. Iridectomy. Irrigation freely with nozzle in anterior chamber. A little opacity at outer part of pupil not influenced by irrigation.	30*th September*, 1892. V.=20/60. 0·5 Sn. at 8 inches.
31	59	M	2*nd November*, 1892. R. Striated. Swollen. Anterior chamber shallow. Acute glaucoma. Reduced tension by eserine. Section above. Iridectomy. Removed large masses of lens by irrigation. Great care required in irrigation. (Other eye operated on for like condition on the 4th April, 1889. He came to hospital on the 11th October, when he stated his vision had been failing 8 or 9 months, that it had suddenly become worse two days previously. Counted fingers on this occasion at 20 feet.)	V.=20/60.
32	50	M	22*nd November*, 1892. R. Striated. Section above. Iridectomy. Free irrigation did not make pupil perfectly clear.	22*nd December*, 1892. V.=20/30. 0·5 Sn. at 12 inches.
33	55		2*nd May*, 1893. L. Striated. Incipient in R. Section above. Iridectomy. Irrigation from outside removed large masses of cortex, causing a whirling round in anterior chamber before expulsion.	V.=20/60. 0·5 Sn. at 8 inches.
34	52	M	16*th August*, 1894. L. Striated. Section above. Iridectomy. Free irrigation.	V.=20/60.
35	55	M	12*th September*, 1893. R. Striated. Section above. Iridectomy. Irrigation. (Same patient as No. 33).	5*th October*, 1893. V.=20/60. 0·5 Sn. at 6 inches.
36	56	F	15*th September*, 1893. R. Striated. Section above. Iridectomy. Irrigation.	V.=20/60. 0·5 Sn. at 10 inches.

No.	Age.	Sex.	Description of Cataract and Operation.	Result.
37	56	F	*22nd September*, 1893. L. Striated. (Same patient as No. 36). Section above. Iridectomy. Irrigation.	V.=20/120. 0·5 Sn. at 7 inches.
38	51	M	*7th September*, 1893. L. Striated. Section above. Iridectomy. Free irrigation. A little cortex left at lower margin of pupil.	V.=20/20 in 1896.
39	50	M	*26th September*, 1893. R. Striated. Section above. Iridectomy. Removed large mass by irrigation.	*6th November*, 1893. V.=20/40. 0·5 Sn. at 10 inches.
40	55	F	*5th March*, 1894. L. Striated. Section above. Iridectomy. Irrigation.	*20th June, 1895*. V.=20/30. 0·5 Sn. at 9 inches.
41	48	F	*8th May*, 1894. R. Striated. Section above. Iridectomy. Injection by needle. Irrigation.	*5th July*, 1894. V.=20/80. 0·5 Sn. at 8 inches.
42	48	F	*31st May*, 1894. L. Striated. (Same patient as No. 41.) Section above. Iridectomy. Injection by needle. Irrigation.	V.=20/80. 0·5 Sn. at 8 inches.
43	52	M	*17th January*, 1895. L. Striated. Section above. Iridectomy. Free irrigation.	*11th February*, 1895. V.=20/60. 0·5 Sn. at 8 inches.
44	35	F	*18th December*, 1894. Striated. Vertical linear section without iridectomy. Irrigation. The lens difficult to remove.	*8th January*, 1895. V.=Threads fine needle.
45	55	F	*8th January*, 1895. Striated and facetted. Section above. Iridectomy. Irrigation. Second day after operation, exudation in wound followed by iritis. Blood in anterior chamber for upwards of a month. Treated by repeated leeching on the temple.	V.=Counts fingers at 6 feet. Iritic adhesions. Thickening of capsule. Requires section of capsule.
46	40	F	*31st January*, 1895. L. Striated. Counts fingers at 1 foot. Section below. Iridectomy. Injection by needle. Irrigation.	*19th November*, 1895. V.=20/80. 0·5 Sn. at 8 inches.

No.	Age.	Sex.	Description of Cataract and Operation.	Result.
47	54	F	*5th March*, 1895. Striated. Section above. Iridectomy. Removed large masses of cortex by free irrigation. Section of capsule by fine knife some time afterwards.	*7th October*, 1895. V.=20/120 before section of capsule. After section of capsule. V. = 20/40. 0·5 Sn. at 11 inches.
48	55	F	*27th March*, 1895. L. Striated. Coming on 15 years. Section above. Iridectomy. Irrigation. Some ciliary congestion and tenderness to touch two weeks after operation. Temple leeched several times with relief.	V.=20/60.
49	57	F	*31st October*, 1895. R. Striated. Section above. Iridectomy. Irrigation.	*18th March*, 1896. V.=20/60.
50	30	F	*26th April*, 1897. Operated on left eye two years ago, when she could still work with the right. R. Dense opacity occupying pupil. On dilating pupil it was found the dense opacity was only central, whilst the periphery was semi-transparent and to some extent striated. Linear vertical corneal section without iridectomy. Injection by needle, causing lens to swell. Expelled small nucleus. Free irrigation required to expel cortex. Iritis ensued a few days afterwards. Cortex not all expelled. Remains of cortex and the capsule obscured vision. *29th June*, 1897. Section of capsule by fine knife. Tension increased. Treated by eserine.	*13th September*, 1897. V.=20/40.
51	50	M	*6th August*, 1897. Whilst able to go about has not been able to follow his occupation of quay labourer for 12 months. L. Flaky. Mother-of-pearl. Can't see any of fundus. Began 2½ years ago. Section above. Iridectomy. Very free injection by fine needle. Several irrigations alternating with massage. Repeatedly pieces of striated cortex brought from behind iris. Vision not being quite satisfactory, made section of capsule about 2 months afterwards.	*18th October*, 1897. V.=20/60. 8 days after section of capsule.

No.	Age.	Sex.	Description of Cataract and Operation.	Result.
52	50	M	10*th September*, 1897. Same patient as No. 51. R. Central opacity rather deep white. Condition of anterior cortical substance shewn in Fig. 65. The four tongues projecting from behind iris represent the parts of the cortex which are mother-of-pearl, the centre and intervening spaces are clear, but except on close examination the opacity of the nucleus and posterior cortical substance, reflecting through, give a false impression. Began to fail 1½ years ago. A month before operation could see a little red of fundus peripherally, now cannot. Cannot count fingers in bright light. Section above. Iridectomy. Injection by fine needle, which I moved freely about. Did not use cystitome. Marked change in appearance of lens, but no cortical substance escaped by injection. The expelled lens was clear except the centre. Believe whole of lens came out at once. Irrigated slightly. Subsequently made section of capsule as in other eye.	18*th October*, 1897. After section of capsule. V=20/60. 0·5 Sn. at 10 inches.
53	45	F	10*th August*, 1897. Only aware of anything wrong for six months. R. eye shows some cortical peripheral opacities, but sees well. L. Striated. Patches transparent. Cannot count fingers. Section above. Iridectomy. Injection by needle. Whilst injection going on moved needle freely all over area of pupil, and had the point down as far as lower margin of pupil. Irrigation alternating with massage made pupil clear.	31*st August*, 1897. V.=20/80.
54	46	M	7*th October*, 1897. Has been working as a carter, but with great difficulty till a week ago. The left eye began to fail 1½ years ago, and the right eye 6 months. Operated on the left eye, in which the cataract was complete in every respect, on the 27th September, 1897, with success. R. Posterior cortex opaque, and striated with spaces transparent as in	14*th November*, 1897. V.=20/60. 0·5 Sn. at 10 inches.

PLATE VIII.

Various Cortical Opacities, almost all Rare.

Fig. 56—Striation of anterior surface of lens.—Case 98.

Fig. 57—Opacities as seen by transmitted light in case 100, but instead of being represented as dark on a red back-ground, are shewn as white on a black ground. There is a central cloudiness.

Fig. 58—Opacities close to capsule, radiate and dotted.—Case 101.

Fig. 59—Anterior surface of lens as seen by oblique illumination.—Case 102.

Fig. 60—Anterior cortical opacity seen by oblique illumination.—Case 104.

Fig. 61—Anterior cortical in other eye of patient.—Case 104.

Fig. 62—Tri-radiate cortical opacity.—Case 105.

Fig. 63—Anterior cortical opacity of right eye by oblique illumination.—Case 106.

Fig. 64—Anterior cortical opacity of left eye of same patient, as case 106.

Fig. 65—Anterior cortex of left eye.—Case 52.

Fig. 66—Posterior cortex of case 54.

PLATE VIII.



Fig. 56.



Fig. 57.



Fig. 58.



Fig. 59.

Fig. 60.

Fig. 61.



Fig. 62.



Fig. 63.

Fig. 64.

Fig. 65.



Fig. 66.

No.	Age.	Sex.	Description of Cataract and Operation.	Result.
			Fig. 66. Centre of lens clear. Some cortical striae anteriorly. Section above. Iridectomy. Injection by fine needle. Repeated irrigation, leaving pupil clear.	
55	32	F	1*st February*, 1898. L. Lens divided tri-radially. Saw 20/200 a month before operation. (R. Slight cortical opacities). Section above. Iridectomy. Did not use injection needle. Nucleus came out, leaving all the cortex. Free irrigation. At lower part of pupil a slight haziness left. Haziness disappeared in a few days.	V.=20/30.

Table III.

Incomplete Cortical Cataract, Common Form, in Persons 60 years old and upwards.

These cataracts are incomplete structurally, but complete functionally with two exceptions.

No.	Age.	Sex.	Description of Cataract and Operation.	Result.
56	65	M	*October*, 1888. Striated and flaky. Section above. Iridectomy. Free injection inside capsule by needle breaking up cortex extensively. Irrigation from outside.	V.=16/60.
57	66	M	11*th January*, 1889. Striated. Section above without iridectomy. Cortex completely removed by irrigation. On first dressing, prolapse of iris was found. The pupil remained clear and eye quiet for a month. The prolapse was treated by compressive bandage. Irritative symptoms ultimately appeared. Finally electro-cautery was applied. This was followed by rapid increase of the irritative symptoms, and the pupil quickly closed.	Perception of light.

No.	Age.	Sex.	Description of Cataract and Operation.	Result.
58	66	M	*5th March*, 1889. R. Striated. (There is an incipient cataract in the left eye.) Large peripheral corneal section above, embracing nearly one-half of the cornea. No iridectomy. Capsulotomy. Lens very sticky. A large quantity of cortex left, and removed by free irrigation, leaving pupil round and clear. When I had finished the operation I noticed some pigment in the pupil, but I did not wash it out. When I opened the eye for the first time, five days afterwards, I observed that the inner half of the section, and likewise that part of the conjunctiva which had been grasped by forceps, were darkly pigmented. The history of this patient was uneventful till after all danger was supposed to have been past. He was discharged from hospital quite well 24 days after the operation. He returned with some ciliary congestion a week afterwards, and was treated for a short time as an extern patient, when I thought it desirable to re-admit him for more effective treatment, which consisted in repeated cupping of the temple, atropine, mercury, and afterwards tonics. The other eye became affected with iritis, as to the character of which I am not prepared to give an opinion. Instead of following order of operations I think it well to give here the history of the other eye which is of much interest and instruction. It should more properly come under the description of Complicated Cataract.	*May*, 1890. V.= 0·5 Sn. at 10 inches.
59	66	M	*22nd October*, 1889. L. Cortex striated and transparent facets. Cannot count fingers. Extensive iritic adhesions. Large corneal section above. Iridectomy. Injection by needle. Free capsulotomy, capsule rather resistant. Expulsion of nucleus, which was small, leaving large masses of cortex. Irrigated from outside, and at last with nozzle inside anterior chamber and behind opacities.	*May*, 1890. After section of the capsule by fine knife he saw 0·5 Sn. at 9 inches.

No.	Age.	Sex.	Description of Cataract and Operation.	Result.
			Two days after operation I opened eye and found the anterior chamber re-established. There was a little pus in anterior chamber, and a deposit of lymph on the surface of the iris at the inner part. He did not complain of pain, and there was no external evidence of anything being amiss before opening the eye. Treatment. — Atropine, hot stuping, wine and quinine. After a few days the pus disappeared, the iris cleared up, and he saw relatively well. That this iritis was due to germs there is no proof. That the iris was more vulnerable after the old inflammation, and that there was both in this eye and the other some constitutional predisposing cause, is very probable.	
60	66	F	*22nd May*, 1889. Striated. Section above without iridectomy. Large quantity of cortex removed by irrigation. There was a delicate thread-like piece which floated about, but did not come out.	*3rd July*, 1889. V.=16/60. 0·5 Sn. at 7 inches.
61	62	F	*24th November*, 1889. Striated. (Other eye had complete nuclear cataract.) Section above. Iridectomy. Injection freely inside capsule by needle. Free capsulotomy. The nucleus was small. Irrigation from outside cleared pupil. The adherent cortex was whirled round before escaping.	V.=20/200. 0·5 Sn. at 6 inches.
62	65	M	*3rd January*, 1890. Striated. Section above. Iridectomy. Tension so high, stopped irrigation before cortex removed. Plastic cyclitis ensued after several weeks. (In other eye immediately on section being made wound bulged. Iridectomy could not be performed. Lens expelled by high tension, and vitreous enclosed in hyaloid presented in wound. The apparent tension could not be considered as owing to the irrigation, for it occurred in the second eye when irrigation was not, indeed could not be used).	V.=Nil.

No.	Age.	Sex.	Description of Cataract and Operation.	Result.
63	69	F	20*th March*, 1890. L. Striated. Section above, without iridectomy. Injection by needle. Irrigation from both outside and within anterior chamber. A little cortex left because patient so nervous and unsteady. Other eye operated on previously for a complete cataract, with like result.	Illiterate. Threads a fine needle.
64	65	M	17*th July*, 1890. L. Striated. Section above, without iridectomy. Injection by needle. Large masses of cortex removed by repeated irrigation.	V.=20/30.
65	60	M	10*th December*, 1890. L. Flaky and mother-of-pearl. Section above. Iridectomy. Injection by needle. Removed large masses of sticky cortex by irrigation, both from outside and inside, but pupil was not completely clear. Subsequent section of capsule by fine knife.	V. = Result was very good, but I cannot find notes. I learned he continued well.
66	64	M	14*th April*, 1891. L. Mother-of-pearl. Section above, without iridectomy. Irrigation removed a considerable quantity of cortical matter. (Other eye previously operated on for complete cataract). 5*th June*. Section of capsule.	V.=20/30.
67	66	M	9*th September*, 1891. Mother-of-pearl. Section above, without iridectomy. Large quantity of cortex removed by free irrigation with nozzle in anterior chamber.	12*th September*, 1892. V.=20/40. 0·5 Sn. at 8 inches.
68	60	F	30*th October*, 1891. L. Striated. Section above, without iridectomy. Irrigation removed a large fragment.	4*th October*, 1892. V.=20/60. 0·5 Sn. at 6 inches.
69	61	F	20*th September*, 1892. R. Striated. Section above. Iridectomy. Cortex sticky. Removed by irrigation.	4*th October*, 1892. V.=20/80. 0·6 at 6 inches.

No.	Age.	Sex.	Description of Cataract and Operation.	Result.
70	78	M	*28th September*, 1892. R. Striated. Section above. Iridectomy. Injection by needle causing breaking up and escape of cortex. Irrigation after expulsion of nucleus cleared out large mass of cortex. Left a little fragment at inner margin of pupil. On opening eye a few days afterwards found small fragment was only the margin of a much larger piece which covered a considerable part of dilated pupil.	*19th October*, 1892. V.=20/60. 0·5 Sn. at 8 inches.
71	63	F	*22nd May*, 1893. R. Striated. Section above. Iridectomy. Injection by needle. Irrigation leaving pupil perfect. On opening the eye two days after signs of septic iridochoroiditis. Disease progressed rapidly from bad to worse. Had used the same irrigator and liquid on two cases previously same day without any untoward result. No doubt the eye was somehow inoculated. (Other eye operated on previously for a complete cataract.)	Nil.
72	60	M	*4th September*, 1893. R. Striated. Section above. Iridectomy. Free irrigation.	Good, but not noted.
73	65	M	*17th December*, 1893. R. Striated. Section above. Iridectomy. Irrigation.	*15th January*, 1894. V.=20/30.
74	64	F	*January*, 1894. L. Striated. Small nucleus. Section above. Iridectomy. Irrigation. Some cortex left. Severe iritis.	*8th March*, 1894. V.=8/200. Capsule thickened, and requires section. As other eye had been operated on with very good result, she did not wish anything further done.
75	65	M	*3rd April*, 1894. L. Striated. Section above. Iridectomy. Irrigation.	*18th May*, 1894. V.=20/60.
76	65	M	*17th April*, 1894. R. Striated. Section above. Iridectomy. Irrigation.	*18th May*, 1894. V.=20/80.

No.	Age.	Sex.	Description of Cataract and Operation.	Result.
77	72	M	*5th March*, 1895. L. Striated. Patient very nervous, therefore made corneal section below. Iridectomy. Nucleus small. Very free irrigation inside chamber necessary. Cortex very coherent.	V.=20/60. 0·5 Sn. at 9 inches.
78	60	F	*7th May*, 1895. Striated. Section above. Iridectomy. Free irrigation removed large masses of cortex.	*28th May*, 1895. V.=20/40. 0·5 Sn. at 8 inches.
79	65	F	*3rd September*, 1895. L. Cortex mother-of-pearl. Division of cortex by small triangular clear spaces. Section above. Small iridectomy. Nucleus difficult to expel, and found to be small. Whole of cortex left and removed by free irrigation with nozzle at wound. Would have injected by needle in this case, but brow so prominent I could not introduce the needle I had at hand.	*23rd September*, 1895. V.=20/80. 0·5 Sn. at 7 inches.
80	60	M	*11th March*, 1896. R. Cortex striated. Triangles transparent. Fingers at one foot. On dilating with cocaine counts fingers at 6 feet. Following his occupation of postman till three weeks ago. (Other eye blind many years). Section above. Iridectomy. Injection by needle opacified all cortex in pupillary area, but did not cause any to escape. Waited a few minutes before expelling lens. Irrigation.	*4th May*, 1896. V.=20/60. 0·5 Sn. at 8 inches.
81	63	M	*30th March*, 1896. L. Counts fingers at 3 feet. Cortex striated. Parts clear. See red of fundus, but no details. Section above. Iridectomy. Lens came out well, leaving some cortex adherent to capsule. Free irrigation.	*26th May*, 1896. V.=20/60. 0·5 Sn. at 12 inches.
82	75	F	*4th June*, 1896. R. Striated. Swollen. Section above. Iridectomy. Free irrigation. A little cortex left at lower margin of pupil. All went well till 2 weeks after operation, when there appeared pericorneal redness. A little pain. Iritic adhesions.	*25th August*, 1896. V.=Counts fingers at 10 feet. Subsequent section by fine knife, but when she left hospital there was no change.

No.	Age.	Sex.	Description of Cataract and Operation.	Result.
83	70	M	18*th June*, 1896. L. Striated. Cannot count fingers. Section above. Iridectomy. Free irrigation.	17*th July*, 1896. V.=20/40.
84	68	F	7*th July*, 1896. R. Striated. Cannot count fingers. Section above. Iridectomy. Several irrigations removed large masses of cortex.	27*th July*, 1896. V.=20/60.
85	65	F	28*th September*, 1896. R. Striated. Section above. Iridectomy. Irrigation.	3*rd November*, 1896. V.=20/60.
86	68	F	27*th April*, 1897. R. Cortex slightly striated. Anterior chamber shallow. Section above. Small iridectomy. Irrigation removed large masses of cortex.	12*th June*, 1897. V.=20/40.
87	65	M	21*st July*, 1897. R. Cannot count fingers. L. Counts fingers at 10 feet. R. Centre of anterior part of lens clear, but at margin of pupil cortical opacities appear as a fringe or ring of glistening mother-of-pearl tongues jutting from behind iris. No reflex from fundus. Section above. Iridectomy. Injection by fine needle, opacifying whole of lens in pupillary area. Waited a little to facilitate separation of cortex from capsule. Massage through the lid. Expelled nucleus which was very small and faintly amber. Irrigation from outside and within anterior chamber with scoop nozzle behind opaque cortex and massage used freely. Did not succeed in making the whole pupil clear. The capsule on irrigation could be seen flapping. I considered there was only a slight cortical lining. When he left hospital on 13th August pupil was not entirely clear. 15*th June*, 1898. Section of capsule.	16*th May*, 1898. (Comes for operation on left eye). V.=20/120. 20*th June*, 1898. After section of capsule 5 days previously. V.=20/60.
88	69	M	27*th September*, 1897. (L. Operated on for pure dark-brown cataract a week previously.) R. Cortex uniformly finely striated. Very slight reflex of fundus. Counts fingers at two feet. This eye only known to be affected 1½ years.	23*rd November*, 1897. V.=20/40.

No.	Age.	Sex.	Description of Cataract and Operation.	Result.
			Section above. Iridectomy. Injected a little by needle. Nucleus expelled, leaving whole of cortex. Irrigation.	
89	62	M	25*th November*, 1897. (R. Operated on by me 3rd December, 1895, for a nuclear cataract. At that time L. V.=8/60. Has been working since. L. Now cannot count fingers. Lens different from that of other eye at time of operation. Lens swollen. Anterior chamber shallow. Cortex flaky. Transparent spaces. Lens seems splitting up. Section above. Small iridectomy. Introduced injection needle easily, distending and rupturing capsule. By pressure of his lid he shot out the lens. Irrigated a little. Very unsteady patient. A little cortex left at lower margin of pupil. On opening eye two days afterwards flakes were observed in pupillary area, but by 12th December the pupil was perfectly clear.	6*th January*, 1898. V.=20/60.

Table IV.

Uncommon Forms of Cortical Cataract.
First Sub-Division.

Cataracts with Semi-Transparent Cortex, simulating Complete Cataract, but sometimes very difficult to Extract.

These are attended sometimes with such exceptional difficulty that I put them in a separate class. The cortex, as appearing in the undilated pupil, looks to be of such a character as would indicate softness, but when the operation is undertaken it may be found that the lens substance is coherent, of normal consistence, and closely attached to the capsule, so much so that the nucleus may be expelled through the cortex,

leaving the whole of the latter remaining. I have met with a number of these cases of so much unforeseen difficulty that they impress upon me the advisability, in all cases in which there is the possibility of doubt, to dilate the pupil and examine carefully the condition of the cortex, by which means the semi-transparency may be more readily recognised. These cataracts are in certain stages of such a character, they might be regarded at one time as commencing nuclear, and at another time as diffuse cortical. If the character of the cataract be recognised, injection by the fine needle is strongly indicated. These cataracts are incomplete structurally.

No.	Age.	Sex.	Description of Cataract and Operation.	Result.
90	63	M	*4th December*, 1888. L. Cortex semi-transparent. Other particulars not noted. Wecker's section above. Iridectomy. Cornea flaccid. Nucleus came out easily, leaving large mass of cortex. No secretion of aqueous. Irrigation with nozzle, both in wound and anterior chamber. Large masses removed from behind iris. Tone of eyeball much better at end of operation than at the beginning. In other eye, operated on previously, the cortical opacity was complete. Result the same in both operations.	Very good. Illiterate.
91	50	M	*7th October*, 1890. R. Centre of lens opaque. Partial opacity of cortex, but no striation. Could not count fingers with pupil undilated. Anterior chamber deep. Duration of affection not noted. Incipient cataract in left eye. R. Wecker's section above without iridectomy. Lens seemed to come out pretty completely. Irrigation removed a few particles from pupil.	*27th November*, 1890. V.=20/20. 0·5 Sn. at 18 inches.
92	56	F	*9th October*, 1890. Central lens opacity. Irregular, semi-transparent opacity of cortex. Could not count fingers with pupil undilated.	*31st October*, 1890. V.=20/20. 0·5 Sn. at 12 inches.

No.	Age.	Sex.	Description of Cataract and Operation.	Result.
			Wecker's section above without iridectomy. Lens came out very well, the nucleus being followed by a large mass of coherent transparent cortex. Removed fragments of lens by irrigation several times with nozzle in anterior chamber. Some opaque substance, probably capsule, left in pupil, which on irrigation moved about, but did not escape. Pupil perfect.	
93	64	M	17*th July*, 1895. R. Cortex with pupil undilated seemed uniformly opaque. No shadow on lens. Could not count fingers. Section above. Iridectomy. Lens did not seem opaque at periphery, but there was a haziness. Expelled nucleus, which was small, and ploughed its way through cortex. Removed all cortex by several irrigations.	27*th August*, 1895. V.=20/40.
94	50	M	14*th January*, 1896. R. Bluish white and semi-transparent. When pupil dilated with cocaine a little striation. Other eye healthy. Section above. Iridectomy. Lens seemed jelly-like. Very great trouble in irrigation from nervousness of patient. A little cortex left rather than run risk of loss of vitreous. 17*th January*. Small opacities seemed much larger. Subsequently altogether absorbed.	4*th February*, 1896. V.=20/30.
95	56	M	20*th October*, 1897. R. Failing for three years, but vision altogether lost for four months. Could not count fingers. Pupillary opacity seemed uniform, did not dilate pupil. Other eye sound. Section above. Iridectomy. Cortex semi-transparent. Did not inject with needle. Lens extremely sticky. The nucleus, which was small, made its way through the cortex, all of which was left. Very free irrigation required to remove cortex. Piece after piece came from behind iris.	11*th January*, 1898. V.=20/30. 0·5 Sn. at 10 inches.

No.	Age.	Sex.	Description of Cataract and Operation.	Result.
96	40	M	*27th November*, 1897. L. Cortex semi-transparent. No striation. Cannot count fingers. Anterior chamber of normal depth. Other eye sound. Section above. Small iridectomy. Nucleus small. All cortex remained behind. Free irrigation required. Two days afterwards iris found prolapsed at one angle of wound without known cause. *17th December.* Prolapse not diminished, but there is no irritation, and pupil is large and clear. Excised prolapse.	*6th January*, 1898. V.=20/80.
97	51	M	*14th December*, 1897. L. Operated on for complete cataract on 23rd November with success. R. Cortex semi-transparent. Cannot count fingers. Anterior chamber shallow. Section above. Iridectomy. Injection by needle. On expelling lens it was found coherent, and its form was moulded on passing through incision. A little rubbed off and left at wound easily washed out.	*11th January*, 1898. V.=20/60.

Table V.

Uncommon Forms of Cortical Cataract. Second Sub-Division.

Very fine Cortical Opacities of several years' duration and making little progress, associated with Myopia. Incomplete structurally and functionally.

No.	Age.	Sex.	Description of Cataract and Operation.	Result.
98	61	M	*2nd March*, 1887. Fine superficial opacities of lens anteriorly close to the capsule, more or less striated. At outer part of pupil, lens more clear than elsewhere. Can see disc, which is rather pale, but not cupped. Atrophy of choroid around disc. He can read No. 3 Sn. at 4 inches. An iridectomy had been performed some years previous by another surgeon for some reason not	1·75 Sn. at 4 inches. As the mediæ were quite clear, the defect remaining was probably owing to the affection for which the iridectomy had been performed.

No.	Age.	Sex.	Description of Cataract and Operation.	Result.
			evident. The vision being so much below what might be expected from the clearness of the media, as shown by ophthalmoscopic examination, I thought possibly a good deal of the defect might be owing to irregular refraction. He had been unable to work for four years, and as there seemed no prospect of a quick advance of the cataract, advised operation, warning him of the risk. (See Fig. 56, which shows sketch of anterior surface of the lens.) Wecker's section above. Nucleus small and clear. Could not judge how much clear cortex was left. Introduced nozzle of scoop syringe, and injected distilled water, removing large masses of clear cortex. Quick recovery.	
99	55	M	*12th April*, 1887. Compositor. Came to hospital on the 18th March, 1887. Said he had been there four years before, and that he was then told he had cataract. Had not been able to do any work for a year, and then he could only do one-fourth of his ordinary work. With his glasses, which were very powerful concaves, could read 1·75 Sn. at 6 inches with each eye. Right eye. Can see disc clouded. Opacities very fine striated, adjacent to capsule, and chiefly at outer part of lens anteriorly. Lens towards inner part of pupil clear. Wecker's section above with iridectomy. The lens looked more opaque peripherally and superficially than I expected. It looked as if capsule and cortical substance adjacent were opaque. Lens appeared small, and this appearance was so marked I feared vitreous might present instead of the margin of the lens. Found capsule tough and difficult to cut. On extraction, lens was found to be small and firm, and without any soft or sticky cortex. Pupil clear. Injected a little distilled water, but nothing apparently was removed. Third day pain, pupil cloudy. Inflammatory symptoms quickly subsided.	*1st August.* 0·8 Sn. at 4 inches. *1st September.* 0·8 Sn. at 8 inches. *21st October.* 0·5 Sn. at 9 inches, with + 3 D.S.

No	Age.	Sex.	Description of Cataract and Operation.	Result.
100	55	M	*7th September*, 1887. (Same patient). L. Reads 0·5 Sn. quite close to eye without any glass. Slight central cloudiness of lens by transmitted light. Can see disc clouded. Large atrophic crescent at inner and upper part reversed image. By oblique illumination radiate structure of lens apparent, and opacities are mainly at posterior capsule, and look as if they covered the whole surface, whilst by transmitted light the opacities are as shewn in Fig. No. 57. Wecker's section above. Iridectomy. After expulsion of nucleus a large quantity of cortex left, filling pupil and clearly shewn by electric light. Two injections by scoop syringe made pupil clear. In this case there was a little serous chemosis for a few days, but pupil was clear and iris normal. No special treatment. The reader will note the very different course of the operation in the two eyes. In the right the lens came out *en masse*, in the left a large portion of cortex was removed by injection.	*7th October.* 0·5 Sn. at 6 inches, with + 6 D.S.
101	45	M	*19th April*, 1887. Draper's assistant. Had not been able to work for 3 years. R. Fine linear isolated opacities anteriorly close to capsule with small dots. Peripheral fringe of opacities well marked. Figure 58 represents the anterior opacities seen by oblique illumination with pupil dilated. Can see disc with trouble. Counts fingers at 3 feet. Preliminary needle operation. It seemed as if opacities were lifted up by the needle, showing that they were intimately connected with the capsule. I would not now recommend or do this.	*4th April*, 1888. V.=15/40. 0·5 Sn. at 9 inches.

No.	Age.	Sex.	Description of Cataract and Operation.	Result.
			3rd May, 1887. Very little change in lens. Wecker's section above. Iridectomy. Lens small. Injection by scoop syringe to remove fragments. Pupil clear. Injection was difficult because of prominence of eye, and the tense stretching of the lids. A little escape of vitreous.	
102	45	M	*8th October*, 1887. (Same patient). L. Fine radiate peripheral opacities, both anterior and posterior, close to capsule, with well-defined spots and lines. A haziness also. Counts fingers at 5 feet. Can see red of fundus all over, but cannot see disc or vessels. Fig. 59 represents the anterior surface of the lens as seen by oblique illumination. Wecker's section above. Iridectomy. Capsule rather tough. Opacities are moved about with the cystitome, shewing that they are quite close to capsule. A mass of muddy cortex shewn by the electric light removed by one injection, leaving pupil clear.	*4th April*, 1888. 0·5 Sn. at 10 inches. V.=15/30.
103	80	F	*17th July*, 1890. R. Always myopic. Deep striae on anterior and posterior surface of lens close to capsule and mainly peripheral. Some encroachment on the pupillary area anteriorly in two narrow stripes. By oblique light lens nucleus not yellow. Can see fundus, but not details. Wecker's section. Iridectomy. Injection by fine needle inside capsule, which was lifted up and moved with the opacities. Expelled lens easily. Irrigation at once removed transparent and semi-transparent fragments. This case is interesting from the fact that even at such an advanced age the capsule was pierced by the fine needle, shewing the relative softness of the cortical substance.	0·6 Sn. at 6 inches, with + 6 D.S. Found extensive choroidal atrophy.

Table VI.

Uncommon Forms of Cortical Cataract. Third Sub-Division.

Characterised by White Opacities like "Bars" of varying size, close to Capsule, with intervening clear spaces, and very slow in progress.

The first three cases are incomplete structurally and functionally; the fourth incomplete structurally, but complete functionally.

No.	Age.	Sex.	Description of Cataract and Operation.	Result.
104	64	M	*20th March*, 1889. Linenlapper. L. A peculiar opacity opposite the pupil of an angular shape (see Fig. 60), adjacent to capsule, and appearing to involve it, and many small linear opacities adjacent to capsule peripherally. Could count fingers at 3 feet, and read No. 4 Sn. with + 3 D.S. Disc and vessels could be seen. A patch of choroidal atrophy beside disc. Duration of affection not noted. Wecker's section above. Iridectomy. Injection inside capsule by needle, causing opacity of lens. Lens sticky and resistant. After expulsion of nucleus, pupil full of opaque cortex. Irrigated three times, leaving pupil clear, but bounded by opaque capsule, which floated about on irrigation. *3rd May*, 1889. Details of fundus not seen distinctly, although pupil seems clear. Some adhesion of iris. Counts fingers at upwards of 20 feet, and sees 1·75 at 5 inches. Figure 61 represents the cataract in the other eye (R.), on which I did not operate, and with which he could see 1·75 Sn. at 4 inches.	*14th June*, 1889. 0·5 Sn. at 8 inches. V.=20/120.
105	36	F	*3rd April*, 1889. Dressmaker. L. Tri-radiate cortical opacity, with steel-grey nucleus. Counts fingers at 2 feet. No note of ophthalmoscopic examination. (See Fig. 62.)	*24th May*, 1889. V.=16/40. 0·5 Sn. at 9 inches.

No.	Age.	Sex.	Description of Cataract and Operation.	Result.
			Wecker's section above with iridectomy. Injected inside capsule by needle. Lens came out easily and perfectly. Irrigated.	
106	65	F	*10th September*, 1895. Needlewoman. Came to me in September, 1895. She stated that until 6 weeks ago she had been able to do the very finest sewing with each eye. Broad bars close to capsule in each eye, with intervening clear space. Pupils small. Could not see fundus in either eye with pupil undilated. On dilatation, disc and vessels visible. R. Counts fingers at 6 feet, and reads No. 4 Sn. Surprised she did not see better. Fig. 63 represents the anterior cortex of the right eye, and Fig. 64 that of the left eye. R. Wecker's section above. Small iridectomy. Introduced hollow needle in opaque part, and pumped freely. Particles of lens escaped. Whole of area of lens exposed became opaque. Nucleus found to be small and clear. Cortex nearly all remained. Irrigated with nozzle outside wound, but, finding this ineffectual, introduced it into anterior chamber behind cortical masses, and cleared a good deal away. Then used scoop nozzle in anterior chamber, and, whilst irrigating, moved it gently up and down, removing large masses of cortex. A slight haziness allowed to remain at lower part of pupil, as I did not deem it prudent to prolong the irrigation. On examining eye a few days afterwards it was found that the capsule had been ruptured horizontally, that there was some cortex inside capsule, and that the iris was adherent to the capsule at the cut margin of sphincter. *December.* Tried to make section of capsule by fine knife, but it only punctured and did not cut; this was followed on the evening of the operation by glaucomatous symptoms, which were relieved by eserine. *17th July*, 1896. Section of capsule by fine scissors.	*24th January*, 1896. V.=20/40. 0·5 Sn. at 10 inches.

No.	Age.	Sex.	Description of Cataract and Operation.	Result.
107	54	F	*23rd September*, 1895. R. Three deep white bars running into pupillary area with spaces intervening of slightly greyish tint. No yellowish colour in nucleus. She had divergent squint of this eye as long as she remembers. Field of vision good. Wecker's section above. Iridectomy. Injection by hollow needle. Some cortex of semi-fluid character came away on puncture, and a good deal of coherent cortex on injection. Nucleus very small. Free irrigation necessary.	Fingers at 6 feet. *6th March*, 1896. Mediae clear, disc appears small. Large crescent round disc. Patches of old choroiditis. One at macula. Retinoscopy shewed still myopia equal to—5· D.S., but a myopic glass made no appreciable difference. The poor result was of course owing to the excessive myopia and choroiditis.

Table VII.

Uncommon Forms of Cortical Cataract.

Fourth Sub-Division, commonly known as "Posterior Polar."

No.	Age.	Sex.	Description of Cataract and Operation.	Result.
108	30	M	Posterior polar cataract. Counted fingers at 6 inches. Needled lens on two occasions. *4th June*, 1888. As lens swelled and pressed on iris below, resolved to extract. Vertical corneal section without iridectomy, but obliged to perform iridectomy afterwards because of tendency to prolapse. Free irrigation. Could not make pupil perfectly clear. A little cortex left, which was absorbed.	*March*, 1889. V.=20/60. 0·5 Sn. at 11 inches.
109	30	M	(Same patient as No. 108.) Posterior polar. Sees No. 4 Sn. at 6 inches. Slight haze on fundus, but see disc and vessels. *18th September*, 1888. Iridectomy above. Forster's artificial method, but without effect. Subsequently needled twice. Hoped that absorption would proceed, but it did not.	*15th October*, 1890. V.=6/36. 1·25 Sn. at 6 inches.

No.	Age.	Sex.	Description of Cataract and Operation.	Result.
			23rd September, 1890. Whole of remains of lens opaque, and filling pupil. Capsule thickened. Section below. Iridectomy. Free section of capsule, and moved capsulotome through lens substance. Pressure and irrigation inside capsule had little effect. Removed thickened capsule with forceps. Then a mass of lens substance removed by irrigation.	
110	35	F	(Sister of Nos. 108 and 109.) Posterior polar cataract. Counts fingers at 4 feet. *12th June*, 1888. Section above. Iridectomy. Was going to have extracted lens at once, but patient so nervous I postponed it. *31st October*, 1888. Section above. Free capsulotomy. Lens extremely sticky. Noticed that the posterior opacity escaped, and was quite distinct in appearance from rest of lens, showing opacity was not capsular. It was soft. Irrigation. Slight opacity skirting pupillary margin. Progress satisfactory for two weeks. Pupil clear. Then slight redness appeared at wound, and a thickening and whiteness began there, and gradually extended till whole of capsule opaque, and the cornea for some distance from the wound cloudy. The iris became adherent to the capsule, and the vision, which had been good, steadily diminished, and finally there came to be a defect of sensibility in lower part of retina. I cannot explain the cause of the untoward result, which was quite unexpected. It may have been one of the sort of cases described by Abadie. The foregoing three operations are all that I have done for posterior polar cataract.	Nil.

Table VIII.

Uncommon Form of Cortical Cataract, known as Zonular—with Nucleus*—Sixth Sub-division.

I note these following five cases not because they all fall within the scope of this work, but because they emphasize the fact that there are exceptions to the general rule that a nucleus is not met with before 30 years of age.

No.	Age.	Sex.	Description of Cataract and Operation.	Result.
111	3	M	*17th August*, 1887. R. Complete cataract with a nucleus floating. Parents noticed the condition for a year, no doubt this had been a zonular cataract as in other eye (case 112). Vertical linear section—easy escape of nucleus.	Good.
112	3	M	L. Zonular cataract. Incomplete structurally.	Good.
			23rd September, 1887. Free needle operation. *10th October*. A little oval nucleus, which has been projecting into anterior chamber for a week, has fallen into the chamber. The nucleus was absorbed, and eye made a perfect recovery.	Good.
113	14	F	*1st November*, 1892. Says that she saw well enough until a year ago. Zonular cataract in both eyes, extending peripherally, so that she can only count fingers at 1 foot. Did not diagnose presence of sclerosed nucleus. R. Free needle operation. Large nucleus in anterior chamber two months afterwards, which was ultimately absorbed.	V.=20/40.

* It has been supposed that the occasional existence of a nucleus in zonular cataracts is a modern discovery. St. Yves was certainly aware of the fact, from operation in such cases. He writes :—"Sometimes the centre of a cataract from the birth is petrified; there is something in the middle of the body of the cataract, about the bigness of a pin's head, hard and concrete like a stone. A noise is even heard when the needle in the couching touches that place, as if rubbed against a small pebble stone. This does not hinder the patient to recover his sight after the cataract has been couched"

No.	Age.	Sex.	Description of Cataract and Operation	Result.
114	14	F	19*th October*, 1893.	
			States she has been blind since beginning of summer, but vision has been bad all her life. Opacity of cortex now uniform, but from history I believe she has had a zonular cataract.	
			R. Small linear vertical section without iridectomy. Cortex liquid. Found large firm nucleus, which was very difficult to extract. Enlarged incision and extracted. Irrigated.	V.=20/30.
115	14	F	L. Large linear vertical section. Found cortex soft, but containing a hard nucleus, which I extracted by pressure. Irrigated.	V.=20/30.

Table IX.

Incomplete Nuclear Cataract in Persons under 60 Years.

These are incomplete structurally and functionally. The ages range from 40 to 57 years. The cortex was clear, partially or totally. The patients were able to count fingers at varying distances.

No.	Age.	Sex.	Description of Cataract and Operation.	Result.
116	55	F	10*th July*, 1889.	26*th August*, 1889.
			Vision failing for 6 years. Some opacities close to capsule. Counts fingers at 4 feet. Reads No. 4 Sn. with difficulty.	0·5 Sn. at 8 inches.
			Wecker's section above. Iridectomy. Intra-capsular injection by fine needle. Nucleus small. Irrigated at first by nozzle in wound, but at last in anterior chamber, removing cortex. Could not make pupil quite clear. When irrigating the eye looked clear, but when I stopped there was some haziness or apparent opacity, which I considered was owing to capsule.	

No.	Age.	Sex.	Description of Cataract and Operation.	Result.
117	55	F	*7th August*, 1889. R. Nuclear opacity. Periphery clear. Counts fingers at 4 feet. Wecker's section above. Iridectomy. Evidence of tension. Free intra-capsular injection. Large mass of cortex left after expulsion of nucleus. Free irrigation by nozzle in anterior chamber. There was a little opacity at outer and lower part of pupil, but irrigation showed it to be capsule.	*26th August*, 1889. 0·5 Sn. at 8 inches.
118	52	F	*14th June*, 1892. Counts fingers at 6 inches, with pupil undilated. Cortex not striated. Periphery clear. Section above. Iridectomy. Free injection by hollow needle. Lens, which was small, came out easily. Irrigation did not remove anything.	Left hospital 28th June, quite well. Was to come back to be tested for glasses, but she went away to America without seeing me.
119	56	M	*6th December*, 1892. L. Counts fingers at 3 feet. Periphery clear. Vision failing 4 years. Section above without iridectomy. After expulsion of nucleus, considerable part of cortex left in eye. Repeated irrigation with nozzle in pupil, alternating with massage. Massage brought, from time to time, fresh cortex from behind iris into area of pupil.	V.=20/60. 0·5 Sn. at 13 inches.
120	40	F	*6th December*, 1892. R. Counts fingers at 2 feet. Periphery clear. Lens of other eye, which was striated and facetted, operated on previously. Section above. Iridectomy. Injected inside capsule by hollow needle. Lens expelled easily. Did not observe that anything was removed by irrigation. Pupil clear.	*20th August*, 1894. V.=20/60.
121	44	F	*5th December*, 1892. R. Counts fingers at 1 foot. Clear peripherally. Failing 3 years. Section above. Iridectomy. Lens came away easily. Irrigation removed little.	V.=20/40.

No.	Age.	Sex.	Description of Cataract and Operation.	Result.
122	44	F	*12th December*, 1892. (Same patient as No. 121.) L. Fingers at 4 feet. Cortex clear. Failing 3 years. Section above. Iridectomy. Tried to introduce fine needle inside capsule, but resistance so great I desisted. Lens seemed to come away completely. Did not observe that irrigation removed anything.	V.=20/40.
123	57	M	*3rd December*, 1895. R. Counts fingers at 4 feet. Cannot see any red of fundus with pupil undilated. Wecker's section above. Knife removed peripheral piece of iris. Lens came out easily and perfectly.	V.=20/80. 0·5 Sn. at 9 inches.
124	50	M	*14th January*, 1896. R. Central opacity bluish white. A little striation when pupil dilated with cocaine. Wecker's section above. Iridectomy. Lens jelly-like. Great trouble in irrigation from patient's nervousness. Left a little cortex, which subsequently swelled, and was absorbed, leaving clear pupil.	V.=20/30.
125	50	M	*28th June*, 1897. R. Central opacity. Periphery clear. Counts fingers at 4 feet. Other eye slightly affected. With difficulty can follow his occupation of attending an engine. Section above. Iridectomy. Injection by hollow needle. Lens expelled easily. Little irrigation.	*5th August*, 1897. V.=20/60. Followed his occupation till May, 1898, when he visited me. The cataract had meantime progressed much in left eye.
126	49	F	*10th August*, 1897. L. Central opacity. See a little red of fundus peripherally. Anterior chamber deep. Counts fingers at 2 feet. Failing 3 years. Section above. Iridectomy. When lens well in wound she shot it out. A little cortex left. Patient so nervous, irrigation very difficult.	*30th September*, 1897. V.=20/40. 0·5 Sn. at 10 inches.

No.	Age.	Sex.	Description of Cataract and Operation.	Result.
127	49	F	*11th September*, 1897. R. (Same patient as No. 126.) Central opacity. Can see red of fundus in greater part of its extent. Counts fingers at 6 feet with pupil undilated. Failing 2 years. Section below, cutting out about half a line within corneal margin, because of patient's nervousness. Iridectomy. Found central opacity well defined, and no cortical opacity. Tried to inject by fine needle, but not satisfactory because of patient's unsteadiness. Capsulotomy. Lens, which seemed to come out entire, was small and flat, with edges well defined, and the cortex was clear and hard. Slight irrigation.	*30th September*, 1897. V.=20/80. 0·5 Sn. at 8 inches.
128	50	M	*2nd November*, 1897. Has been working at his occupation of engine-driver on railway till his visit to hospital in October, 1897. R. Central opacity. No cortical striation. Counts fingers at 1 foot. Section above. Small iridectomy. Did not use injection by needle. Irrigation removed any cortex remaining at once. Stuck his finger in eye on night after operation, causing prolapse of iris, which I excised on 17th December.	*14th March*, 1898. V.=20/80.
129	50	M	*17th January*, 1898. L. (Same patient as No. 128.) Central opacity. A little cortical opacity, chiefly posterior. Almost all anterior surface of lens clear. Can see red of fundus and details obscurely. Counts fingers at 20 feet. Section above. Iridectomy. Injection by needle, moving it inside capsule freely. Lens was coherent and moulded in its form on coming through wound. Slight irrigation.	*14th March*, 1898. V.=20/30.

Table X.

Incomplete Nuclear Cataract in Persons 60 Years and Upwards.

The following cases are incomplete both structurally and functionally. The cortical substance was to a great extent transparent, the patients able to count fingers from 1 foot to 15 feet, and the fundus usually visible.

No.	Age.	Sex.	Description of Cataract and Operation.	Result.
130	63	M	10*th October*, 1885. Counts fingers at 2 feet in dull light. Can see large part of fundus. Wecker's section above. Iridectomy. Removed cortex by injection by scoop syringe. Operation quite as easy as that on other eye, which had complete cataract.	0·5 Sn. at 5 inches.
131	65	F	7*th April*, 1886. Counts fingers at 2 feet. Cortex clear. Wecker's section above. Iridectomy. After expulsion of lens, which seemed to have come away completely, she could not count fingers. Injection by scoop syringe cleared vision. The operation on this eye as easy as that on other eye in which the lens was perfectly opaque.	0·5 Sn. at 8 inches.
132	63	M	17*th June*, 1886. Counts fingers at 1 foot. Cortex transparent. Can see great part of fundus when pupil dilated. Wecker's section above. Iridectomy. Injection by scoop syringe removed transparent cortex easily. Operation was as easy as that on other eye, which had a complete cataract.	V.=0·8 Sn. at 8 inches.
133	70	M	17*th September*, 1886. Counts fingers at 15 feet. Perinuclear opacity at inner and lower part. Can see great part of fundus. Wecker's section above. Iridectomy. Injection by scoop syringe removed	V.=0·5 Sn. at 7 inches.

No.	Age.	Sex	Description of Cataract and Operation.	Result.
			cortex easily. Other eye had been operated on by me previously for a cataract with brown nucleus and opaque cortex. (This incomplete cataract was more easily extracted than the complete one.)	
134	66	F	12*th October*, 1887. R. Counts fingers at 4 feet with pupil undilated. Can see red of fundus peripherally. Wecker's section above. Iridectomy. Cornea collapsed. No secretion of aqueous. Cortex sticky. Removed perfectly by syringe, but with some trouble.	10*th December*, 1887. V.=20/60. 0·5 Sn. at 7 inches.
135	66	F	19*th October*, 1887. L. Counts fingers at 1 foot with pupil undilated. Areas of cortex transparent. Wecker's section above. Iridectomy. Washed out cortex easily.	16*th December*, 1887. V.=20/80. 0·8 Sn. at 6 inches.
136	70	M	17*th April*, 1888. Central cloudiness of lens. Periphery clear. Counts fingers at 4 feet. Can see disc obscurely. Always short-sighted. Says he saw me four years previously when I told him he had cataract. Section above. Iridectomy. Lens seemed to come out perfectly. A film of blood interfered with judging with certainty as to whether cortex completely removed. Injected several times with scoop syringe. Pupil as seen by electric light never perfectly clear.	6*th March*, 1889. V.=0·5 Sn. at 12 inches.
137	60	M	8*th May*, 1888. Counts fingers at 4 feet. Can see red of fundus, but no details. Section above, with iridectomy. Injection inside capsule with hollow needle. Removed piece of capsule with Forster's forceps. Lens was large and easily extracted. Irrigated only a little. (The other eye had a dark-brown cataract.)	V.=0·5 Sn. at 12 inches.

No.	Age.	Sex.	Description of Cataract and Operation.	Result
138	68	F	*4th September*, 1888. R. Counts fingers at 4 feet. Can see red of fundus peripherally. One small spot of opacity in cortex. (The other eye had been affected with an old brown cataract which I extracted.) Section above, with iridectomy. Removed capsule by forceps. Lens large and easily extracted. A little cortex removed by irrigation. The operation on this eye was as easy as that on the other eye with a complete cataract.	*21st September*, 1888. V.=18/60. 0·5 Sn. at 8 inches.
139	66	M	*December*, 1889. Fingers at 4 feet. Can see red of fundus. Vision failing one year. Periphery clear. Section above. Iridectomy. Intracapsular injection. Lens seemed to come out whole, and was firm, but pupil contained small fragments. Irrigation cleared pupil, save as regards a film, owing to capsule changed in my opinion by contact with blood at early stage of operation.	*7th May*, 1890. V.=20/60. 0·5 Sn. at 8 inches.
140	61	F	*12th April*, 1892. L. Counts fingers at 2 feet. Can see red of fundus everywhere, but no details. Cortex clear. Failing 3 years. Section above. Iridectomy. Lens came out whole. Little irrigation.	V.=20/80.
141	60	M	*October*, 1892. Counts fingers at 6 feet. Can see red of fundus and vessels indistinctly. Rather diffuse spots central and on surface. Section above. Iridectomy. Intracapsular injection by fine needle. Whole of lens came out easily. Irrigation did not seem to remove anything. This was a remarkable case of extreme nervous shock, which I refer to in Chapter VIII., and on which I subsequently performed iridectomy.	*22nd March*, 1893. Fingers at 12 feet.

No.	Age.	Sex.	Description of Cataract and Operation.	Result.
142	65	M	12*th November*, 1892. Counts fingers at 2 feet. Can see red of fundus, but no details. Cortex partially opaque. Section above. Iridectomy. Lens came out at once completely. Irrigated, but nothing was removed. Same patient as No. 143.	22*nd December*, 1892. V.=20/30.
143	65	M	19*th November*, 1892. Counts fingers at 3 feet. Same appearance as other eye, No. 142, but less advanced. Section above. Iridectomy. After expulsion of nucleus pupil full of broken up cortex, which was removed by irrigation.	22*nd December*, 1892. V.=20/30.
144	64	M	*July*, 1895. R. Periphery hazy. No striation. Shadow on lens. Section above. Iridectomy. Nucleus small and difficult of expulsion. Cortex all left. Free irrigation required.	V.=20/40.
145	64	M	*July*, 1895. Counts fingers at 3 feet with pupil dilated. Deep shadow on lens. Nucleus small and sharply defined. Haziness around nucleus. Can see red of fundus, but no details. Section above. Iridectomy. Attempt to introduce fine needle well inside capsule ineffectual. Lens came away easily and completely. Irrigation removed nothing. The ease of this operation contrasts with the difficulty of operation on the other eye (No. 144), in which the opacity was much more advanced.	V.=20/40.
146	60		*August*, 1895. Counts fingers at 3 feet. Can only see a little red of fundus. Cortex clear. Section above. Iridectomy. Some cortex removed by irrigation.	V.=20/40.

No.	Age.	Sex.	Description of Cataract and Operation.	Result.
147	63		31*st March*, 1896. L. Counts fingers at 3 feet. Can see red of fundus, but no details. Cortex partly opaque. L. Section above. Iridectomy. Lens came out well. Some cortex adherent to capsule removed by free irrigation.	V.=20/60.
148	70	F	25*th March*, 1897. Can go about. R. Failing several years. L. Not so long. R. Fingers at 3 feet. Anterior chamber deeper than that of other eye. Can see red of fundus, but no details. Cortex clear. Nucleus amber-brown. Section above. Iridectomy. Lens was small, flat, and cortex clear, and seemed to come out whole. Little irrigation.	21*st May*, 1897. V.=20/80. 0·5 Sn. at 10 inches.
149	66	F	17*th May*, 1897. R. Fingers at 10 feet. Pupil undilated. L. Fingers at 20 feet. R. Central cloudiness. No striæ. Large shadow on lens. See all the red of fundus, but no details. Section above. Iridectomy. Introduced needle for injection with difficulty, and made little impression. Lens was small and slightly amber. No soft cortex. Irrigated little.	16*th November*, 1897. V.=20/30.
150	66	F	29*th June*, 1897. (Same patient as No. 149.) L. Counts fingers at 12 feet. Description same as for right eye. Section above. Iridectomy. Injection by needle difficult. Lens slightly amber, and nearly altogether transparent. Free irrigation.	16*th November*, 1897. V.=20/30.
151	65	F	20*th July*, 1897. R. Failing 5 years. L. Not so long. Can go about. R. Fingers at 2 feet. Can see no details of fundus. Did not dilate pupil.	V.=20/60.

No.	Age.	Sex.	Description of Cataract and Operation.	Result.
			Anterior chamber rather deep. Cortex clear. No striation. Section above. Iridectomy. Did not inject by fine needle. Lens was small, with cortex transparent and firm. Could not count fingers. Irrigated, but could not say what was removed. Slight opacity of filmy character in pupil. On waiting a little the opacity did not increase.	
152	69	M	*20th September*, 1897. L. Failing 5 years. Dark-brown cataract, but so transparent can see red of fundus. Counts fingers at 2 to 4 feet, according to the light. Section above, and iridectomy. Lens came out whole. Did not inject or irrigate. (Operated on other eye on 27th Sept., 1897. See Case 88. The character of the cortex was different.)	*23rd November*, 1897. V.=20/60.

OPERATIONS ON CATARACTS PAST THE STAGE OF COMPLETE DEVELOPMENT.

I might extend the scope of this book very much were I to enter into details of actual operative work in cases of so-called regressive cataract in young and old, shewing the great disadvantages of delay. But all surgeons of experience must have ample knowledge of the subject, though not prominently noticed in statistics. I would hope that the actual records I have given should be convincing that the average results of early operation are, to put the matter moderately, much superior to those obtained after waiting till extensive degenerative changes have taken place.

In a large number of these cases irrigation will be found to clear out grumous and gritty irritating particles in a way which cannot be attained by any other method. But in certain cases the difficulties of removing coherent cortex is so great, even with the aid of free irrigation, that an operator inexperienced in the method would fear he had gone too far.

Table XI.

Complicated Cataract.

Anomalous Sclerosis of Lens secondary to Inflammatory Conditions.

Condensation of lens and intimate union of lens and capsule, associated with iritic adhesions or deep-seated disease, are sometimes met with.

In such cases, even when the adhesions are slight and the alterations in the capsule by no means of a gross character, the surgeon may find unexpected difficulties in extraction. The capsule may not be incised readily, but even when it is incised or a part of it removed by forceps the lens may be found so firmly fixed in its capsular socket that it cannot be dislodged by ordinary pressure. This condensation and close attachment of capsule to the body of the lens is not limited by age.

Irrigation, whilst perhaps desirable for the ordinary toilet of the operative field, is not of very obvious utility in these cases.

I subjoin notes of three remarkable cases showing complete hardening of the lens in young people.

I undertook the operation in cases Nos. 153 and 154, relying upon intra-capsular injection and irrigation, but found, from the unexpected hardening of the whole lens, that method useless.

No.	Age.	Sex.	Description of Cataract and Operation.	Result.
153	32	F	Had iridectomy performed by me ten years ago on the right eye for a glaucoma with complete circular synechia, and on the left eye eight years ago for complete circular synechia with threatened glaucoma. Both eyes recovered perfectly, and she followed her occupation of dress-making till five years ago. She was then in America, and obliged to give up her occupation. She came to me a year after the failure, *i.e.*, four years ago, when I found opacities close to capsule, and the capsule seemed involved. Thinking the disease,	30*th August*, 1895. Progress normal. V.=7/120. No. 4 Sn. at 6 inches. *October*. Section of capsule by fine knife. V.=20/40. 0·5 Sn. at 10 inches.

No.	Age.	Sex.	Description of Cataract and Operation	Result
			being of inflammatory origin, might be influenced by general medical treatment, I prescribed a course of subcutaneous injection of pilocarpine, with internal administration of iodide of potassium, but this did not seem to have any effect. The opacification made very slow progress, and I resolved at last, not without some misgivings, to extract the lens from both eyes. *31st July*, 1895. R. Counts fingers at 1 foot. The margin of the lens is seen above where the iridectomy had been performed, and there is a clear circumlental space. Central yellowish nuclear opacity, and a haze over whole of the lens. No striation anywhere. Pupillary margin adherent to lens. Can see red of fundus peripherally above. Large section below in cornea, the points of puncture and counter-puncture being at sclero-corneal margin, the centre of the section being about half a line from the corneal margin. Iridectomy. Thinking the capsule might be resistant, I made a small cut in it peripherally with Graefe's knife. Tried to introduce fine needle inside capsule, but lens so resistant and moved so much I desisted. Tore capsule with pricker, but found it very tough. The lens was expelled easily, and found to be large and hard throughout. There was no soft cortex whatever. The pupil was covered with a fine greyish opacity, owing to change in the capsule, which irrigation did not alter.	
154	32	F	*10th September*, 1895. (Same as No. 153.) L. Counts figures at 3 feet. No amber-coloured centre, as in right eye. No striæ anywhere. A myrly opacity at or in capsule anteriorly and posteriorly. Circumlental space seen above. Can see red of fundus all over, but no details. Same section as in right eye. Iridectomy. Had no difficulty in introducing fine needle inside capsule, and injected freely, but the injection did not cause any increase in opacity except in its own track. Capsulotomy. Lens seemed to	V.=20/40 and 0·5 Sn. at 10 inches. She has remained quite well ever since, and followed the occupation of shop assistant in a drapery establishment.

No.	Age.	Sex.	Description of Cataract and Operation.	Result.
			come out entirely. Irrigated freely, however, with nozzle well inside capsule, but whether any cortex removed not apparent. She saw more clearly after irrigation. I purposely took time over this operation to see whether the irrigation would cause any opacity, but it did not. The myrly greyish opacity remained without change. Some pain in eye and tenderness to touch followed the operation, but disappeared on cupping the temple a few times. I thought I would be obliged to cut capsule, as in the other eye, but further interference was found to be unnecessary.	
155	16	M	Came to me on 28th April, 1896. Stated he had been blind of right eye for years. Capsule thickened over more than whole pupillary area. Field for light was good, but still I gave a very cautious prognosis, thinking there was deep-seated disease not revealed by light test. Linear vertical section. Small iridectomy. Cut round thickened capsule and removed with forceps. The thickened capsule removed was of such size that I thought the whole lens would escape. Found unexpectedly lens hard, horny, and adherent to remaining capsule. Irrigation and pressure without any effect. Removed piecemeal by small scoop.	*9th June*, 1896. Counts fingers at 8 feet without a glass. Cataract glass makes little difference. Could not determine exact character of deep-seated disease.

REMARKS.

The foregoing statement of cases may be analysed in regard—

(1.) To the Efficiency of the Methods of Removing Cortex.

(2.) To Accidents during Operation.

(3.) To Post-operative Incidents, immediate and remote, in how far they relate—

(*a*) To the methods of removing the cortex, and

(*b*) To other stages of the operation.

(*c*) To secondary operations.

(4.) To the confirmation or disproof of certain notions—

(*a*) That in operating on incomplete cataract the intra-capsular cells are specially active in the production of secondary cataract.

(*b*) That there is any special danger in operating on incomplete cortical cataract between 30 and 60, and

(*c*) That there is any security in extracting any cataract in persons 60 years and upwards, regardless of the character of the cataract.

(1.) *The Efficiency of the Methods of Dealing with and Removing Cortex.*

(*a*) The injection inside the capsule has been made or attempted to be made in 61 cases out of the whole.

In 55 of the cases it was successfully accomplished—Nos. 2, 5, 6, 7, 9, 10, 11, 12, 13, 14, 15, 16, 17, 18, 19, 21, 22, 23, 25, 41, 42, 46, 50, 51, 52, 53, 54, 56, 59, 61, 63, 64, 65, 70, 71, 80, 87, 88, 89, 97, 103, 104, 105, 106, 107, 116, 117, 118, 120, 125, 129, 137, 139, 141, 154.

In 6—Nos. 122, 127, 145, 149, 150, 153—it was attempted, but either found impossible of safe accomplishment or had no appreciable effect, and was only of value in diagnosing the sclerosis of the cortex, and in all these cases the diagnosis was proven to be correct by the easy extraction of the lens.

The great field, therefore, for intra-capsular injection is in cortical cataract.

(*b*) Irrigation in various ways was performed in 146 cases.

In 123 the pupil was left perfectly clear.

In 23 some cortex was left at the time of the operation, or appeared in the pupil at the first dressing (cases 1, 19, 27, 28, 29, 30, 32, 38, 50, 62, 63, 65, 70, 74, 82, 87, 89, 94, 106, 108, 109, 124, 126). In the great

majority the cortex left was in very small quantity, and no injury followed, as shewn by the results :—

In 14, excellent results, without any secondary operation.

In 5, excellent results, after section of capsule.

In 2, section of capsule required.

In 1, section of capsule made without known improvement.

In 1, lost from iridocyclitis.

The facts recorded are noted with minuteness to warn the surgeon that he is not to expect the attainment of absolute perfection in every case, but that for special reasons it may be prudent to stop irrigation short of what may be desired. At the same time what a small proportion the cases in which cortical substance remains after painstaking injection and irrigation bear to the whole will be apparent.

(2.) *Accidents during Operation.*

The only accidents to be considered are really dislocation of the lens, or escape of vitreous humour at some stage of the operation.

There is singular freedom from either of these accidents, and for the following reasons :—

(*a*) In incomplete cataract the zonule of Zinn is strong.

(*b*) In cortical cataract the needle enters the capsule easily, and there is no danger of dislocation, and the rupture of the capsule which takes place always takes place anteriorly.

(*c*) If in nuclear cataract the needle does not readily enter, the attempt is stopped and hence danger is averted.

(*d*) In irrigation, after expulsion of the nucleus, escape of vitreous is rare.

(3.) *Post-operative Incidents.*

Those which have proved of an irremediable character are five in number :—

Cause.

Case 57. Prolapse of iris.
,, 62. Iridocyclitis following incomplete removal of cortex because of high tension.
,, 71. Septic.
,, 110. Late iridochoroiditis, but cause of it not known.

Case 141—that of nervous shock—I treat of in detail in Chapter VIII. This was a case of poor result.

It is worthy of remark that in these cases, with the exception of case 62, the operation was finished most perfectly. In case 62 it was impossible to remove cortex safely by irrigation or by any other means.

(*a*) In not one of these could the misfortune be shewn to be owing to injection or irrigation.

(*b*) On the other hand, cases 57, 62, and 71 were owing to other known and sufficient causes, whilst the cause in case 110 is not known.

(*c*) Secondary operations are few, and embrace—

Sections of capsule by fine knife, cases 27, 47, 50, 51, 59, 65, 66, 82, 153.
Section of capsule by intra-ocular scissors, case 106.
Iridectomy, case 141.
Sections of capsule noted as required, cases 16, 19, 45, 74.
Cauterization of prolapsed iris, case 57.
Of course an increase of visual acuity might be obtained by capsulotomy in many cases.

(4.) *The Confirmation or Disproof of Certain Notions.*

(*a*) My statistics absolutely disprove the statement, so often repeated, that a great objection to operating on incomplete cataract is the tendency of the intra-capsular

cells at that stage to proliferate, and thus produce secondary cataract. The statement has no basis in fact, but is a surmise—an erroneous explanation of a common result of the ordinary imperfect operation.

(*b*) Whilst the opinion commonly entertained* that operation by the ordinary methods on cataracts of the forms embraced in Table II. (incomplete cortical in persons from 30 to 60 years) is dangerous is well founded, the cases recorded prove that such cataracts can, by the methods described, be extracted with results quite as good as those obtained in operations on cataracts which have reached the stage of complete development. I consider that period of life more favourable for operation than a later period.

Further, it will be surely a matter for reflection to those who practise two or more operations at different times on such cataracts whether the operation here described is not preferable from every point of view.

An examination of the details of the 51 cases in Table II. brings into prominence some facts of importance, viz., that there were only four secondary operations

---

* Dr. Noyes, speaking on Forster's method of trituration at the Ophthalmological Congress in Edinburgh in 1894, said that "there was a field for the proceeding of trituration of cataract he fully conceded, and he also made the remark that it was entirely unnecessary to perform iridectomy in order to accomplish the purpose required, namely, the securing of such opacity of the lens as would make it suitable for extraction. This has been shown by Dr. Pooley, of New York. But the cases to which in his judgment, and according to his experience during the last twelve years, such a proceeding was admissible, were those cases which were usually found in subjects under 45, in whom the lens was comparatively soft, having broad striæ, and in which no sclerosis of the nucleus appeared, and in which, were they to attempt extraction without any other proceeding, or without iridectomy, they would be greatly annoyed by a large amount of cortex."—*Transactions Eighth International Ophthalmological Congress*, 1894.

Schweigger says that towards 40 years the centre of the crystalline is hard, but the cortical layers soft and adherent to the capsule; that when one operates the nucleus only is removed, the debris of the cortical layers remaining in place; that the cortex may be transparent, but on the contact of the aqueous humour it swells and causes an irido-choroiditis, and even a keratitis if the debris passes into the anterior chamber. These accidents occur especially in the case of patients aged between 40 and 55 years. In infants and young persons they generally do not occur. The period of 40 to 55 years is therefore the most dangerous. He asks what is to be done for these patients. Before 40 he advises discission, followed by extraction, and after 40 the nucleus presenting a certain hardness, he counsels Forster's method of trituration.—*Annales d'Oculistique*, 1890.

performed, and three secondary operations noted as indicated; that in 15 cases iridectomy was not performed, and that in these 15 cases there was only one prolapse of the iris, or about 7 per cent., and in a very restless patient; that there was no loss of vitreous; that there was no loss of an eye; and that the visual results were on a high average, viz. :—

V. = 1 Normal	3
V. = ⅔	9
V. = ½	6
V. = ⅓	21
V. = ¼	8
V. = ⅙	2
V. = Fingers at 6 feet	1
V. = Illiterate; threads fine needle ...	1
	51

(*c*) In relation to the bearing of age on the question of operation for cataract, Table III. (Incomplete Cortical Cataract in Persons 60 years and upwards), Table IX. (Incomplete Nuclear Cataract in Persons under 60 years), and Table X. (Incomplete Nuclear Cataract in persons 60 years and upwards), are particularly suggestive and instructive. Table III., embracing 34 cases, shews that 60 years gives no security in striated, flaky, cortical cataract. Indeed, some of these cases were difficult, and my misfortunes and imperfect results were almost confined to this class. Tables IX. and X., embracing 37 cases of incomplete nuclear cataract, some so little developed that most surgeons would regard them as incipient, shew the remarkable fact that in at least 29 the operation was very easy; and in the whole 37 there were only two secondary operations, one an iridectomy in the unfortunate case of nervous shock described in Chapter VIII., and the other an excision of prolapse of the iris through injury caused by the patient himself.

The two latter tables give strong support to the views expressed by Noyes,* and also to those of Schweigger,† in relation to the easy removal of lenses whose cortex has undergone physiological hardening by age. Table III. is altogether against the idea of safety in operating

* Dr. Noyes, at the same meeting of the Ophthalmological Congress referred to, made the following remarks:—"The tendency at the present time, of which he had been a very careful and very conservative student, was to deal with cataract at that period of time when it began so far to impair the vision of the patient that he could no longer perform his duties in life. And from step to step, trembling, and with a sense of his responsibility, and acting as conscientiously towards his patients as he would have another act towards himself, he had gradually gone from point to point in dealing with cataracts which were very far from mature, so long as he could perceive that these cataracts were hard, that they had a sclerosed nucleus, and with the sclerosed nucleus he accordingly came to the conclusion that the cortex was hard. Then he conducted the operation by the simple method which meant a large incision, almost the half of the cornea, and without iridectomy. He had for the last five years, from time to time, operated upon cataracts through which the patient could count fingers at varying distances of one to five feet, in which he could trace the nerve and its vessels by the ophthalmoscope, and in which the patient had a central nuclear opacity, frequently upon the posterior pole, sometimes only in the nucleus, of irregular type, but which precluded him from reading or writing, though he might perhaps feel his way about the street. Those cases he had taken and had operated on by the simple method, without iridectomy, and had from them just as satisfactory results as if the lens had been like ground glass. He claimed, and he believed the experience of a certain number of men would go to show, that in this class of cases the patient might be 50 years of age. He had seen that occur. They might be as young as 50, and the lens sufficiently sclerosed, but if they were over 60 years of age he could assure the Congress that the probability was that the lens was already so hard that it would come out with a large incision, and without iridectomy, and leave a pupil just as clean and with as little tendency to secondary cataract as in any case in which they could operate by maturation of the lens. Irrigation of the anterior chamber by the physiological saline solution, 0·6, and warm, without putting the point within the wound, would easily bring out any fragment of cortex which might linger."

† Schweigger says that the true response to the question of ripeness of cataract is the following:—A cataract is ripe when it can be removed totally without leaving debris of lens, capable of giving trouble at a later period. In fact, a cataract in which the opacity is incomplete is sufficiently ripe if, after the operation, the opacities cannot be reproduced. But how can we recognise this? It is almost exclusively the age of the patient which will guide us. The faculty of accommodation, very great in early life, is lost progressively; towards 50 or 60 years it has almost completely disappeared. This applies to the normal modifications which the lens undergoes under the influence of age. In fact, the lens undergoes a process of induration which begins at the centre, and which extends by degrees to the cortical layers. At 60 years of age the lens is hardened in its entirety, whether cataractous or not, and whether the cataract is complete or not. The cataract and the induration are phenomena absolutely different; the one is pathologic, the other physiologic. Thus, in the case of persons of 60 years who have lost the faculty of accommodation, a cataract even incompletely developed may be removed without the opacities being reproduced; for it is certain that the lens can be removed entirely. The surgeon can operate on them consequently, as soon as the visual trouble is sufficient to make them seek surgical relief."—*Extracted from Report of Schweigger's Paper in Annales d'Oculistique*, 1890.

on incomplete cortical cataract by the ordinary methods. I think the real state of the case may be summarized as follows :—

A non-cataractous lens, at a time when the power of accommodation has been altogether lost, which occurs at a variable period, but usually about 60, may possibly, with a sufficient section, be completely extracted. (The surgeon, for obvious reasons, is never likely to acquire that experience.) A lens with central nuclear opacity, but with the cortex clear, about and after that period of life, is almost always easily extracted. A lens, on the contrary, showing signs of breaking up of the cortex, as indicated by striated, flaky, unequal opacity, offers just the same resistance to complete removal as a lens with cortex of a like character would at an earlier period of life.

I may note here that it appears clear on a careful inspection of Tables IX. and X. how seldom the hollow needle was used in all these cases, and how often it could not be introduced inside the capsule in persons 60 years old and upwards. It is evident how small a role the needle plays in operation on persons of this age and on this form of cataract, and with what caution it must be used.

Analysis of Results in Tables IX. and X.

The almost perfect safety of the operations on incomplete nuclear cataract will be apparent on an analysis of the results disclosed by these tables. As I have not in every case noted distant vision, I can only give an approximation :—

Visual Acuity.	No. of Cases.
V. = 2/3	9
V. = 1/2	5
V. = 2/5	4
V. = 1/3	10
V. = 1/4	7
V. = Very good, but not tested ...	1
V. = Fingers at 12 feet	1
	37

Estimation of the Value of some Diagnostic Points.—Although, in my operations on incomplete cataract, I have not been guided materially by any niceties in diagnosis of consistence, but have been influenced by my belief in, and consequent reliance on, injection and irrigation to overcome difficulties, foreseen and unforeseen, it occurs to me that it may be useful nevertheless to discuss some of the factors already referred to in actual application. I refer to the structural character of the lens, the degree of vision, the age of the patient, and the age of the cataract. For this purpose I shall select a few of the most recent typical cases recorded in the foregoing statement of cases, and amplify the description to make the points clearly understood.

Case 87.—J. M., male, aged 65, miller. Stated his vision had been failing for two years, and that he had not been able to work for three months. I found a cortical cataract in the right eye, the posterior cortex being chiefly affected. Anteriorly the centre of pupillary area pretty clear, but periphery of pupil encroached on by tongues of opaque mother-of-pearl cortex jutting from behind iris. No yellowness of nucleus of lens. The anterior chamber was rather shallow. He could not count fingers, and no red reflex of fundus could be seen. He could count fingers at 10 feet with the other eye, and go about. I considered it would probably be a difficult operation. Of all the factors the structural character of the lens is the only one in this case which determines the opinion. Here the age of the patient, the age of the cataract, and the loss of vision could never be seriously considered as indicating an easy operation. This was a cortical cataract of the common form, and of about the second stage of development, as described in the Classification. It was incomplete structurally, but complete functionally.

I performed the operation, and I found it both tedious and difficult. The hollow needle was used freely. As was afterwards seen, some cortical substance was left, and covered the lower part of the pupil, but there was no irritation. When he came back, after about 10 months, found V. = 20/120, and that there was very slight capsular opacity, which I cut with Knapp's knife needle, increasing vision as noted to 20/60 in a few days.

I need not repeat cases like 87, for they all would illustrate the fact that in ordinary incomplete cortical cataract the judgment as to how the lens would behave on operation depends on the structural character of the cortex alone, and that the other factors are of no value whatever.

Case 125.—C., aged 59, stated that up till the present he had been working at his occupation of engineer, but at considerable disadvantage from failing vision. His right eye was affected for about a year, and was getting worse. He counted fingers with it at 12 feet, and the other eye saw pretty well. There was a nuclear opacity in the right eye, but the cortex was clear, and I could see red of fundus. No notable difference in the depth of the anterior chambers of the two eyes.

I advised, in order to secure himself against the consequence of probable further loss of vision of the left eye, to have an operation performed on the right, to which he agreed.

In this case the absence of any appearance of softening, the nuclear character of the opacity, and the age of the patient, were in favour of the operation, which I thought would be easy. Though he saw fairly with the other eye, and was still able to work, but not to his satisfaction, the material interests of the patient, I thought, would probably be served by early operation, and he was of the same opinion. The extraction was

performed in the usual way by Wecker's section above with iridectomy. The hollow needle was introduced inside the capsule and injection made, shewing that the cortical substance was not perfectly sclerosed. The lens was easily expelled, and the after-course was without incident. He came to me recently with a cataract developed in the other eye, and informed me he had been at work ever since.

V. = 20/60.

Cases 149 and 150.—Mrs. C., aged 65, housewife, stated that her vision was failing upwards of a year. She counted fingers with the right eye at 10 feet, and with the left eye at 20 feet, in ordinary light, and with pupils undilated. The anterior chamber in each eye was relatively deep. Large shadow on lens by oblique light. By direct illumination with the ophthalmoscope there was a central cloudiness of the lens in each eye, more marked in the right than in the left; the cortex was clear, and all the red of the fundus of each eye was seen, but no details were visible. The whole of the factors had to be balanced in this case.

The structural appearance and the depth of the anterior chamber indicated that the cortex had not softened, and that the lenses would probably be found to come out complete. The vision being so good raised the question of prudence of operating on eyes seeing so well, but the other factors controlled the opinion.

The age of the patient, in the absence of any structural cortical changes in the direction of softening, supported the opinion formed on other grounds, that the cortex, though clear, was probably condensed through ordinary senile physiological changes incident to that period of life, and that the lenses would be expelled

completely through a sufficient section. The cataracts were incomplete structurally and functionally.

Both eyes were operated on at a short interval, and the operations proved the correctness of the opinion. The hollow needle confirmed the opinion as it had no appreciable effect on either lens. Both the lenses were small, slightly amber, and nearly altogether transparent, and extraction was complete.

R.—V. = 20/30.

L.—V. = 20/30.

Case 151.—Mrs. B., aged 65, a widow lady, very active and intelligent, and apparently in excellent health, stated that the right eye had been failing for five years, and the left not so long, and that she had not been able to read for some time. With her right eye she counted fingers at 2 feet, and with her left at 10 feet. There was nuclear opacity in both eyes, but the cortex was clear, and the amber tinting of the nucleus was only slight. The anterior chambers were deep.

I could see fundus in each eye far better than I expected from her vision, but still no details in the right.

The cataracts were incomplete structurally and functionally.

Here the whole of the factors were of service.

The slight opacity and slight tinting of the nucleus raised a doubt, whilst the evidence of smallness of the lens pointed to sclerosis. The age of the patient and the age of the cataract both likewise indicated sclerosis, and were strongly in favour of ease of operation. I did not think it necessary or advisable to try to inject by the hollow needle. The lens was small, hard, and clear. The result confirmed the opinion.

V. = 20/60.

Early Operation in relation to the Material Well-being of the Patient.—I have become more and more deeply impressed by other than the purely surgical side of the question, viz., by the material well-being and prospects of the sufferers and their friends.

In the foregoing tables I only embrace incomplete cataracts, and deal with surgical results, but I shall take a short review of my whole work in all sorts of cataracts for the last year, and show how it contrasts with the ordinary practice of surgeons who only operate on "ripe" cataract, and hesitate or refuse to operate on monocular cataract.

The total extraction operations in hospital on all sorts of idiopathic cataracts, complete and incomplete, for the year 1897 were 41 on 29 patients.

Six out of the 29 were altogether monocular, or second eye not appreciably affected. These have all had vision restored, and are relieved from dread of failure of the second eye. Two of these cataracts had passed the stage of complete development, and should have been operated on earlier. They had been all attending to their ordinary work.

Nine, although both eyes affected, were either able to attend to work or to go about alone until time of operation, and of these 8 had incomplete cataract in both eyes, and the results have all been successful.

Three had been operated on previously by me, and had been attending to their work since. They came for operation on the second eye, and were only off work the time necessary for each operation and the ordinary subsequent care.

Eleven only of the 29 (three having previously lost an eye from some cause) were led to me blind, some of them being blind from two or three up to nine years. The loss of time to these persons, in the aggregate,

amounted to many years, and entailed very heavy and, to my mind, needless loss in earnings. If an average of three years for each be taken, it would amount to 33 years, and estimating earnings lost at even 15s. per week, it would reach the large sum of £1,287. Surely it would be a great thing for surgery to lessen such misery and loss.

The 18 cases in which I have had an opportunity of carrying my views into effect have had a happier fate than the 11 who were allowed to become blind. They have been saved many years in time, and the money value would be, even at labourer's rates, a large sum.

CHAPTER X.

CONCLUSIONS.

It was open to me, instead of giving detailed reports of cases, to publish summarized results; but I think, though there may seem a considerable uniformity in many of the cases, there are so many different points of view from which they may be regarded that the reader in search of definite information will be more instructed by details than by summary, and by each case being so reported as to be complete in itself.

It is fitting, however, now to consider and state the main conclusions which are to be drawn from the tables and the facts which I publish. They are—

(1.) That the introduction within the eye of the sterilized saline solution is harmless.

(2.) That injection or irrigation by the fine needle inside the capsule of the lens in incomplete cortical cataract is a safe proceeding.

(3.) That the removal of cortex is a mechanical process, and regulated by ordinary physical laws.

(4.) That, from the anatomical structure of the eye, and the conditions existing during the operation, irrigation is more efficient in removing cortex than any other method.

(5.) That just as irrigation removes cortex, so it removes blood and bubbles of air. It also shows the condition of the capsule, gives tone to and replaces the iris, and is effectual in making the toilette of the wound.

(6.) That it restores tone to a collapsed cornea, and supplies the want of aqueous when that humour is not re-secreted.

(7.) That, by attention to the cautions I have given, very free irrigation by the nozzles may be practised without fear.

(8.) That striated, flaky, mother-of-pearl cortical cataract in persons under 30 may be extracted by simple linear section; but as a rule, from the relatively quick progress of cataract at this period of life, it is seldom necessary to interfere before complete development.

(9.) That the cataracts with like striated, flaky, mother-of-pearl cortex in persons from 30 to 60 may be extracted with as good results as cataracts at any other period of life or of any form.

(10.) That cortical cataracts in persons of 60 years and over behave in no respect differently from cortical cataracts of an earlier period of life; and the fixing of this age, or indeed any age, in this form of cataract, as an indication of safety in operating by ordinary methods is not warranted by actual practice.

(11.) That nuclear cataract with transparent sclerosed cortex may be found relatively early, and, long before 60 years of age, may, failing other conclusive signs, be diagnosed by the fine needle, and may be extracted completely and easily.

(12.) That incomplete nuclear cataracts at a later age are commonly easily and completely extracted.

(13.) That whilst the age of the patient and the age of the cataract may be of some advantage in determining whether an operation is easy or the reverse on a nuclear cataract, they are of no use when the cortex is involved in a softening process and becoming striated, flaky, and mother-of-pearl.

(14.) That in what I describe as the uncommon forms of cataract the operator may have excellent results, but he must be prepared occasionally for difficulties.

(15.) That in case of an inflammation of the iris, even slight, when attended with adhesions, the operation may be difficult, from (1) thickening of the capsule; (2) from close adherence of capsule to lens, and condensation of lens even in early life.

(16.) That in incomplete cortical cataract the zonule of Zinn being usually strong, the conditions are particularly favourable for safe irrigation.

(17.) That irrigation does not tend to cause prolapse of vitreous.

(18.) That it does not tend to cause suppuration of the cornea, iritis, and iridochoroiditis.

(19.) That the secondary operations form a small percentage.

(20.) That, considering the condensation of cortical substance and proliferation of the intra-capsular cells in slowly developing traumatic cataract, prompt interference might be generally advisable.

(21.) That when the wound of the cornea is large, and especially when there is ground for suspecting septic inoculation, it would be well to extract the lens at once, and irrigate the interior of the eye by a weak solution of chinosol, say, one part in 8,000 of water.

(22.) That it is unwise to allow a cataract to reach the so-called regressive stage.

(23.) That it is in the interest of patients, for the sake of security, comfort, and material advantages, when one eye only is affected, to operate on that eye when the cataract is complete.

(24.) That for a like reason a patient with double cataract should never, if possible, be allowed to become blind.

APPENDIX A.

CONSIDERATION OF THE QUESTION OF IRIDECTOMY IN CATARACT OPERATIONS.

As will be seen in my reports of cases, I have as a rule performed iridectomy, but in some instances I have not. For some years, however, except in young persons, I have practically abandoned the simple operation for cataracts, whether incomplete or complete, and for what I consider good reasons. As this subject has been under discussion for many years without apparently any approach to decision, it is desirable to make at least an attempt to ascertain on which side the balance of evidence lies.

It is well to understand that those engaged in this discussion only refer to operation on cataracts which have become complete.

The issue as between the two methods is really reduced to narrow limits. The questions of the relative ease of the extraction, the danger of iritis from bruising or stretching of the iris, or the inconvenience caused occasionally by hæmorrhage from the iridectomy, are too paltry to be seriously considered. The real questions are—(1.) The percentages of prolapse, and the influence of the prolapse on the ultimate result. (2.) Whether, in the cases in which prolapse does not take place, the general visual acuity is so much better as to be considered as a set-off to the unfortunate cases of prolapse, and to warrant the adoption of the simple method as the standard operation. (3.) Whether, by persistence of the practice of the simple method, there is reasonable probability of finding any method of preventing prolapse. (4.) The disadvantages of iridectomy. (5.) Advantages of iridectomy.

(1.) *The Percentages of Prolapse, and the Influence of Prolapse on the Ultimate Result.*—The cases reported by different operators are cases, it must be understood, which leave the hands of the operator with the iris in its normal position, so that any prolapse which occurs is owing to something altogether outside of the mere operation. What may happen then is owing, it may be, to want of skill or care on the part of the nurse, or to unmanageableness of the patient, or to some cause which no skill or care can prevent. The personal element of the operator, then, is removed

as to the actual prolapse, without regard to the percentage of prolapses.

The prolapses of those who have made a sort of speciality of the simple extraction vary much. Panas states that his mean annual prolapses do not exceed 5 per cent.* Knapp in 891 operations had 9·1 per cent. prolapses.† Webster‡ gives detailed reports of 113 simple extractions, shewing 15 prolapses and 2 incarcerations, with the results, which are as follows:—

2	..	..	V. = Perception of light.
1	..	..	V. = Counts fingers.
2	..	..	V. = 16/200 and 15/200.
5	..	..	V. = 20/200.
2	..	..	V. = 20/100.
2	..	..	V. = 20/70.
2	..	..	V. = 20/30.
1	..	..	V. = 20/20.

What prolapse and incarceration meant to the patients may be seen on comparison of the results in the cases in which prolapse did not take place with those in which it did.

In a total of 96 cases in which prolapse did not occur there were 74 cases, or at the rate of 77 per cent., in which the vision was upwards of 20/70; whilst in the 17 prolapses only 3, or 17·6 per cent., had like vision. In other words, the percentage of very good results was upwards of four times as great when prolapse did not occur.

Only 22 of the 96, or about 23 per cent., had vision so low as 20/70 or under; whereas 14 out of 17, or about 82 per cent., had such poor results where prolapse took place. It is to be noted, also, that in two cases out of the 14 there was total loss, and in another case the patient could only count fingers.

Knapp, in a paper read at the International Ophthalmological Congress § in Edinburgh, stated that he had 55 cases of prolapse and incarceration in 548 successive simple extractions, with the following bad results amongst the prolapses:—

1 V. = 5/200.
1 V. = 3/200.
2 V. = 0.
2 V. = 0, and loss of the second eye in each of these cases.

---

* Panas—"Maladies des yeux," 1894. † *Ophthalmic Record*, July, 1897.
‡ Manhattan Eye and Ear Hospital Reports, January, 1895.
§ "Transactions of the Eighth International Ophthalmological Congress," 1894.

He only performed a secondary operation in 14 cases out of the 55; and of the bad results noted above, which must be reckoned at 8, they all, with the exception of two, occurred in the cases submitted to the secondary operation. I must regard the statistics of Knapp, one of the ablest and most ardent advocates of simple extraction, as strongly against it.

Schweigger,* who only reckons as prolapses those which he abscisses, had 26 prolapses in 208 operations, with the following results:—

3	Lost.
2	Imperfect observation.
1	Complicated case.
2	V. = $^1/_{15}$ to $^1/_{7\cdot5}$
5	V. = $^1/_{7\cdot5}$ to ¼
9	V. = ¼ to ½
4	V. = ½ to 1

As I have said, I have had some experience of the simple operation, and I abandoned it some years ago because of prolapse. Up till that time I had notes of 99 operations by Wecker's section without iridectomy, with 14 prolapses. I shall now analyse my 14 prolapses. The treatment was as follows:—

8 times I excised the prolapse, but always after lapse of some time.
Once I applied electro-cautery.
5 times I applied compressive bandage.

The results were:—

1 ..	V. = P.l.—lost. Electro-cautery applied late.
1 ..	V. = Counts fingers at 6 feet.
2 ..	V. = 20/200.
1 ..	V. = 20/120.
2 ..	V. = 20/80.
1 ..	V. = 20/60.
2 ..	V. = 15/40.
2 ..	V. = 20/40.
1 ..	V. = Threads fine needle.
1 ..	V. = Marked "Good."

Adding together the prolapses of Webster, Knapp, Schweigger, and myself, noted above, we have a total of 112, with the admitted total loss of 10 eyes from the prolapse and 2 additional from sympathetic ophthalmia. Ten per cent. of

* "Archives of Ophthalmology," Vol. xxvii., 1898.

losses in cases of prolapse, and because of the prolapse, must be regarded as a serious indictment against the simple method.

(2.) *Whether, in the cases in which Prolapse does not take place, the general Visual Acuity is so much better as to be considered a set-off to the unfortunate cases of Prolapse, and a compensation for the increased risk, anxiety, and confinement.*—Judging from my personal experience of the two methods, my opinion is that the visual acuity is somewhat better in the simple operation than in the combined. The statistics of some operators do not show any striking difference in the actual visual results, whilst those of others vary considerably. Schweigger, comparing 208 simple extractions with 194 extractions with iridectomy, all performed by himself, shows much better visual results by the former than by the latter method. Swanzy,* however, shows, on an analysis of 100 cases of the combined operation performed by him, better results than those obtained by Schweigger by the simple extraction.

But it would take a great difference—if there be a difference—capable of easy demonstration, and not mere opinions, to warrant the subjection of all patients, without previously consulting them, to the close confinement and to the continuous and exacting care proven by universal experience to be ineffectual in about ten cases out of every hundred in preventing the accident so much dreaded.

Still greater advantage would be required to compensate if what the accident really means to the ten victims of ill-fortune and disappointment be fairly weighed. It entails secondary operation or prolonged bandaging, or both, and yields results much below the average. The operation I speak of is abscission, and I regard it as of much more gravity than the original operation. If it be spoken of lightly to the patient, and an attempt be made to remove the prolapse without general anæsthesia, if the prolapse be considerable there is very great risk indeed of escape of the vitreous; but if advised that for safe operation chloroform should be administered the patient commonly regards the matter with the gravest apprehension, and indeed I have met with patients who absolutely refused to undergo a second operation.

But, though the mere abscission or cutting off is a grave matter, the abscission combined with the dissection out of the iris which has formed an organic connection with the wound is still more so, and is indeed one of the most difficult and

* "Transactions of Royal Academy of Medicine of Ireland," 1890.

dangerous in ophthalmic surgery. The reader can judge for himself from Knapp's description of the operative procedure recommended by him, which is as follows:—"In 14 cases 22 per cent. of the prolapse, 2·5 per cent. of the simple extraction, an operation was performed. This consisted in an iridectomy, when the prolapse was fresh and the edges of the wound could be freed from the incarcerated iris; or in an abscission, when the prolapse projected like a cyst or a staphyloma. In the latter case I have been careful to remove all iris, not only outside, but also in the canal of the wound, lest a relapse occur, which is not rare at the edges of the wound. Of late I had the privilege to witness such an operation done by Professor Panas. He not only removed all the tissue lying outside and in the wound canal, but raised the flap and excised the fibrous tissue which passed from the scar into the vitreous."

I will assume, for the purpose of argument, that the better general acuity of vision is undoubted, and look at the question from another point of view. The operation may present different aspects to the operator and to the patient. The operator may aim at attaining to the highest style and finish in his operation, and securing the highest visual acuity, regardless of inherent difficulties and unavoidable risks. The patient, above all things, wishes to secure sufficient vision with the minimum of difficulty and risk.

I am confident that hardly any person of intelligence, comparing the actual visual results obtained by the two methods of operation, if informed beforehand that by one method he would have ten chances in the hundred of having a prolapse of the iris, and by the other method he would be practically saved from that risk, would submit to the simple operation.

One thing is evident—the accident of prolapse is almost altogether of the surgeon's making, and is in a large measure avoidable. The formidable secondary operations, which require such care and dexterity, and are sometimes so disastrous, are provided by himself, and are the consequences of his own action. It is perhaps reasonable to suggest, and is certainly right, that in all cases the person most concerned—viz., the patient—should be consulted before the simple operation is undertaken.

(3.) *Whether, by persistence in the practice of the Simple Method, there is reasonable probability of finding any method of preventing Prolapse.*—There being no doubt that the simple operation is the ideal one, it is only natural that surgeons should endeavour to find out

some method of so performing it and so conducting the after-management as to make it successful.

I cannot see any ground for thinking that anyone could hope, by following the methods of the distinguished surgeons who practise simple extraction, to secure more perfect results than they have attained.

To form an opinion as to the probability of preventing prolapse, the causes of this accident must be definitely ascertained, that we may judge whether they are capable of being counteracted.

The surgeon who could dream of preventing prolapse by any new form of section would shew himself ignorant or forgetful of the history of the operation. Assuming that the operation has been successfully performed, there are certain causes of subsequent prolapse of such a commonplace character as to be easily understood, and many of which the surgeon may foresee, but cannot prevent. They include injury to the eye by the patient's hand or by a rash movement, motions of the eye under the bandage from whatever cause, coughing, sneezing, mastication, startling noises, disturbing dreams, want of sufficient caution in opening eye for inspection, and sudden exposure to light. General restlessness and nervousness, low or weakened intelligence or power of control leading to disregard of instructions, the weariness and irksomeness of close confinement, are also causes contributory, and are all more likely to be met with in old people.

But whilst the above causes are recognised as sufficient to account for the prolapses which we commonly meet, and are no doubt the usual causes, occasionally the accident happens in cases in which the operation was perfect, and every single circumstance to favour or account for a prolapse is wanting.

Panas rather attempts to discredit the causes referred to, and to attribute prolapse to others of a character not so easily investigated. Indeed, he suggests as causes an agitation or shaking of the vitreous, or perhaps an exaggeration of the intra-ocular tension.* The shaking of the vitreous is, and will always be, common to all methods of extraction. The increase of intra-ocular tension noted by Panas is far more likely to be the result of the prolapse than the cause of it. The general absence of increased tension in the combined operation favours the view that the increased tension is the result of the prolapse. If Panas'

* Panas—"Traité des maladies des yeux," 1894.

view were correct one might hope that a new therapeutic agent might be found to diminish tension and to produce greater myotic action than any drug now known, and so remove intra-ocular tension as a cause.

Schweigger* has recently proposed a method of preventing prolapse which consists in pulling forward the iris with fine forceps after the extraction of the lens, then pushing a broad needle as peripherally as possible through the iris and widening the incision towards each side extensively. Anæsthesia of the iris is first induced by tropo-cocaine introduced into the anterior chamber. Dr. Bell Taylor practised a similar method a quarter of a century ago, except that he made the section of the iris before the expulsion of the lens. I have no personal experience of Dr. Taylor's plan, and no information as to the results.

Putting aside mere theories, let us look to the facts. There is a large wound with a movable structure lying behind it, often tending to come out, or liable to be forced out. When it comes out from whatever cause, there it remains. The iridectomist prevents this by removing the structure in whole or in part. The anti-iridectomist tries to prevent this by the most rigid care after operation, and always fails in a certain percentage. If the wound, or in other words the open door through which the iris passes, could be safely sealed or closed until union took place, the question would be solved. It is clear that on the old lines on which so many surgeons of great resource have worked, there is nothing to be hoped for. Meantime, till some efficient means is discovered, the radical measure of the iridectomist is most to be trusted.

(4.) *The Chief Disadvantages of Iridectomy.*—The chief disadvantages of iridectomy are the occasional adhesion of the capsule of the lens to the wound, and the adhesion of the iris to and incarceration of it in the angles of the wound. The opponents of the combined operation dwell on this fact in rather an emphatic way, and would make it appear that if there are blots in the simple operation, there are the same in the combined operation. To allege that they are to anything like the same extent is unwarrantable.

That iridectomy, and especially a large one, renders possible these adhesions is true, but still the cases in which it leads to disaster are rare. A smooth section, quick restoration of the anterior chamber, and smallness of the iridectomy are the best protection against this occurrence.

---

* "Archives of Ophthalmology," 1898.

Too much importance has been given to the change of the shape of the pupil (which may be largely concealed by the upper lid), and to the circles of diffusion.

(5.) *Advantages of Iridectomy.*—The advantages of iridectomy commonly recognised are the diminution of prolapses of the iris, and the facility of removing cortical substance, but for old people there is an advantage not fully recognised—the little confinement and care necessary. Whilst a patient is better in bed for a number of days, yet the restraint may be very small. Were there no other advantage, it is a very precious one, for I have little doubt that the common practice of iridectomy has done as much as anything else to remove the apprehension of the public in relation to cataract operations, and make patients seek advice and submit readily to operation in a way unknown in the days of flap extraction. With the re-introduction of the simple operation there is a return to the irksome and deterrent after-treatment of past times.

SUMMING UP.

To sum up, then. A method entailing so much unavoidable risk, requiring nurses of exceptional experience, ability, and care (not always to be had), necessitating such constant supervision, enforcing longer confinement to bed, imperilling the results of the most perfect operation through the most trifling occurrence, and having in its favour no advantages of a major character, is not one which, with our present knowledge and resources, should be generally adopted, but rather reserved for special cases and for those persons who knowingly prefer it.

APPENDIX B.

THE following are extracts from an address by the Author as President of the Ophthalmological Section of the British Medical Association at Belfast, in July, 1884. The present work is only a development of the views at that time expressed but to some extent modified by larger experience:—

I propose to ask you to consider with me some points relating to the extraction of cataract. One of the fundamental rules regarding that operation is that we should wait until the cataract is mature. This rule is seldom departed from, and then with a considerable amount of misgiving. Patients are kept waiting for an indefinite period—it may be for many years—while the process of ripening is going on: a period of gradually failing vision, perhaps of anxiety and failing health, of possible penury or destitution. Among ophthalmic surgeons there will be unanimity on this point—that if we could only remove this barrier of immaturity, and devise some method of operating with success on all cataracts, no matter what may be their condition of maturity, we would confer a great boon upon the community, and add considerably to the *prestige* of ophthalmic science. I hope that ere long the experience of my brethren will enable them to share with me the opinion that all lenses, whether cataractous or not, and, if cataractous, whether wholly or partially so, may be extracted with as much success as the most mature cataract may be at present. I shall state, very shortly, the grounds upon which I base my opinion, and upon which I venture to ask you to give a trial to the procedure which has given me very promising results. That method I may designate as intra-capsular or intra-lenticular injection.

The chain of observation and reasoning by which I came to practise this method is very simple. We have all noticed how tedious it is at times to remove cortical substance, and the necessity for frequently waiting for the re-secretion of the aqueous humour. Why, I thought, should this process not be shortened by injecting inside the capsule a little water, of about

the temperature of the body, to wash out the cortex, or at any rate to facilitate its removal? A little pure water differs so little from the aqueous humour, that it could hardly be regarded as a foreign body. Besides, were it necessary to have a fluid for injection of about the same composition as the aqueous humour, that could be easily prepared. The introduction of water into the eye was less likely to do harm to the structures than gold, silver, or steel instruments used as scoops. Besides, the water would exercise a certain force on parts which could not be safely reached by any instrument, and which too often contained fragments of the lens, the cause of destructive inflammation. Unless the temperature were too high or too low, or the injection were made with too much force, no reasonable fear of injury could be entertained.

On looking up the question of the relation of the capsule to the lens, with a view to find support or opposition to my views, I found in a small book of lectures, published in 1849 by our distinguished countryman, Sir William (then Mr.) Bowman, a very interesting observation. In speaking of the elasticity of the capsule he stated that on one occasion, when making some observations on this subject, he allowed a lens to remain in water for some time, and found that the fluid had by endosmosis passed within the capsule, and that the lens was detached from the capsule completely by a layer of fluid. On pricking the capsule with a needle, its elasticity was so great as to eject the water with considerable force. In this I found strong evidence in favour of my intra-capsular injection method for very immature cataracts and clear lenses. When such a separation of the lens from its capsule took place in a short time by endosmosis, why should not the lens be separated at once or quickly from the capsule by injection? Sir William Bowman's observation showed me that the connection between the lens and its capsule was easily severed, and left no doubt on my mind that, by a properly constructed needle, introduced immediately beneath the capsule, water injected would find its way rather towards the surface than into the body of the lens. In fact, assuming the point of puncture sufficiently occluded to prevent the water from coming back, the elastic capsule would inevitably be distended.

The first case in which I used the intra-capsular injection was one of senile cataract. The progress of the case was normal. The injection had no injurious influence. I used the water of a temperature of about 100° Fahr. Since that time I have used it in almost every case in which I have operated, and in various

ways; and this I can say, that in no case does it seem to have given rise to any tendency to a suppurative process. I have used it in various cases of immature idiopathic cataract in which the periphery of the lens was clear, and of immature traumatic cataract, and I need not point out that such cases afford a good test of the capability of the method.

The methods of injection which I have used are:—(1.) The introduction within the capsule of a needle attached to an ordinary hypodermic syringe. If there be any part of the lens substance easily disturbed, the injection usually ruptures the capsule a little at the point of puncture, and washes out a good deal of cortex. It is certain that it clears out masses quite easily that could not readily be removed even by a scoop. This mode of injection is perfectly safe. (2.) After removal of the nucleus, the introduction of water inside the capsule by gravitation from a bottle fitted with a tube. (3.) The introduction of a similar terminal to that attached to the bottle, but fixed to the syringe. The latter two methods require a good deal of care, and involve the question of the force allowable, and the time during which the flow of water and the syringing can be safely continued. It is difficult to regulate the temperature with precision, because the syringe and bottle, when removed from the vessel in which they are immersed, lose temperature quickly. I have had, however, instruments constructed which I think obviate the difficulty experienced in my first operations, and which I now have pleasure in submitting for your inspection.

I had an opportunity last week of trying the effect of intra-capsular injection in a perfectly clear lens in a healthy eye. The patient was aged sixty years, and was affected with a cancer of the orbit, which necessitated the excision of all the orbital contents. Before performing the operation I punctured the eye, and injected water beneath the capsule. The capsule was immediately distended. On opening the eye afterwards I found the capsule ruptured anteriorly, one segment retracted, and the other lying on, but separated from, the lens.

The relative harmlessness of intra-ocular injection being once recognised, other applications of it will suggest themselves, as, for example, in the case of certain affections attended with hypopyon. I have used it already in some such cases, I think with advantage.

In any new operative procedure the most minute particulars are of consequence. These I should have given you, but this is neither the time nor place. I purpose shortly publishing all my cases in full.

Before bringing the question before the profession, I should have preferred to wait and introduce it in a more complete way; but when I found I had to address you I selected the subject which was engrossing my attention, and which I was sure would be most interesting to you. In addition, my experience of the method, although not great, extending only over a period of three months, was sufficient to enable me to give you an idea of its value and of its relative innocuousness, and to warrant me in asking you to assist in determining its capabilities and its place (which I expect will be a high one) in the ophthalmic surgery of the future. To summarize, it shortens operations, it puts aside scoops, spoons, and curettes, does away largely with the tedious process of friction through the lids to remove cortex, and enables me to undertake operations of which previously I should not have dreamt.—*British Medical Journal*, August, 1894.

PLATE IX.



FIGS. 67 AND 68.—The above plate is made from a recent photo, and is meant to be substituted for figs. 22 and 23 on Plate III. It shows the form of the electric lamp I at present use. There is no change in the acetylene lamp.

INDEX.

PAGE

Abscission of iris after prolapse ... 188
Accidents during operation ... 170
Accommodation, faculty of, in relation to extraction of the lens 59, 74, 175
Acetylene lamp for operations ... 80
Acuity of vision 44
" " after the simple operation 188
" " after the combined operation ... 188
Age of the cataract ... 51, 176, 183
" " patient ... 50, 176, 183
" " " in relation to operation 172 *et seq.* 183
" " " in relation to operation—Noyes on 172, 174
" " " in relation to operation—Schweigger on ... 172, 174
Alcohol 71
Anterior chamber, diagnostic value of depth of 34, 35, 53
" " endothelium of ... 90
" " action of various agents on—Nuel and Cornil on 90
Antisepticism in ophthalmic surgery 66 *et seq.*
" efficient, how to secure in suppuration of wound 112
" intra-ocular, chinosol for 72
" " evil results of ... 90
" " Gayet's experience of 90
" " Nuel and Cornil on 90
" " Panas' method of 90
Antiseptic agents ... ... 67 *et seq.*
" methods, explanation of success attending ... 73
" solutions and dressings ... 81
Apparatus for intra-ocular injection and irrigation ... ... 82 *et seq.*
Artificial maturation of cataract 19, 54, 172
Asepticism in ophthalmic surgery ... 66
Assistants 80

AGE

Blood-letting, general 116
Boiling temperature, germicidal power of 68
Boracic acid 70
Bottle, sterilizing and irrigating ... 82
Bowman on the elasticity of the capsule of the lens 194
Brailey on development of cataract... 27
Brewster, Sir David—views on treatment of cataract ... 91
" " observations of a critic on the views of 91
Capsular cataract 36
Capsule, elasticity of—Bowman on 194
Capsulo-lenticular cataract 37
Cases of cataract, tabular statement of ... 127 *et seq.*
" " complicated, tabular statement of 166 *et seq.*
" " incomplete cortical, common form, tabular statement of 127 *et seq.*
" " incomplete cortical, uncommon and special forms, tabular statement of ... 144 *et seq.*
" " incomplete nuclear, tabular statement of ... 156 *et seq.*
" " remarks on tabular statement of 168 *et seq.*
Cataract, age of 51
" anterior polar 36
" artificial maturation of 19, 54, 172
" behaviour of various descriptions of, on operation 62 *et seq.*
" capsular 29, 36
" capsulo-lenticular ... 29, 37
" classification of 22
" classification of, developmental 30
" classification of, essentials of good 23

PAGE

Cataract, classification of, functional 28, 31
,, ,, ,, Llandolt's proposition as to ... 24
,, classification of, objections to various modes of ... 23
,, classification of, structural 27, 29, 33, 34, 35, 36, 37
,, classification of, surgical ... 32
,, complete, definition of ... 30
,, complicated 38
,, ,, cases of 166, 167, 168
,, congenital 26
,, consistence of, diagnosis of, by hollow needle 60 *et seq.*
,, consistence of, estimation of value of some diagnostic points in determining ... ... 176 *et seq.*
,, cortical 29, 33
,, ,, barred 34
,, ,, ,, cases of ... 151
,, ,, common forms of ... 33
,, ,, ,, ,, ,, cases of ... 126 *et seq.*
,, ,, complete 34
,, ,, disseminated ... 35
,, ,, distinction of, from nuclear 30
,, ,, incomplete ... 42
,, ,, ,, cases of 126 *et seq.*
,, ,, ,, definition of ... 30
,, ,, ,, Noyes on 172
,, ,, ,, results of operations on ... 173
,, ,, ,, Schweigger on ... 172
,, ,, myopia with rare ... 34
,, ,, ,, ,, cases of 147 *et seq.*
,, ,, posterior 35
,, ,, posterior polar ... 34
,, ,, ,, ,, cases of 153 *et seq.*
,, ,, semi-transparent ... 34
,, ,, ,, cases of 144
,, ,, uncommon and special forms of 34, 35
,, ,, ,, cases of 144 *et seq.*
,, ,, zonular ... 35, 42
,, ,, ,, with nucleus 35
,, ,, ,, ,, ,, cases of 155
,, ,, ,, with nucleus —St. Yves on 155
,, development of—Brailey on 27
,, discission of ... 76, 96
,, double 184
,, early operation for ... 16
,, extraction of, in its capsule 19
,, ,, simple linear 97

PAGE

Cataract, extraction of, Wecker's 3 mm. flap 98 *et seq.*
,, incomplete 30, 31, 32, 33, 34, 35
,, ,, Critchett on ... 21
,, ,, definition of ... 30
,, ,, Sichel on ... 21
,, ,, slow operation on 22
,, ,, Tweedy on .. 21
,, lenticular 29
,, liquid 36
,, monocular ... 184
,, Morgagnian 37
,, nuclear 29, 35
,, ,, complete, definition of .. 30, 31
,, ,, diagnosis of sclerosis of, by hollow needle 61
,, ,, distinction of, from cortical 30
,, ,, incipient 42
,, ,, incomplete, definition of .. 30, 31
,, ,, incomplete, statement of cases of 156 *et seq.*
,, ,, Noyes on 174
,, ,, Panas on 61
,, ,, Schweigger on ... 174
,, ,, St. Yves on ... 61
,, nucleo-cortical ... 29, 36
,, operation for, artificial light for 79 *et seq.*
,, ,, artificial maturation ... 19
,, ,, discission 76, 96
,, ,, linear extraction, simple 76, 97
,, ,, preliminary needle ... 19
,, ,, Wecker's 3 mm. flap 76, 98
,, pyramidal 36
,, range of operation for ... 18
,, ,, ,, circumstances limiting 18
,, ripe 14, 34
,, ,, objection to term ... 24
,, safe early operation on, importance of 16
,, secondary 37, 124
,, ,, operations for 124, 125
,, statement of cases of 126 *et seq.*
,, surgery of, chief questions in the ... 15
,, ,, non-progressive character of the 17
,, ,, present position of the ... 13
,, traumatic 37, 107
,, ,, different classes of 107 *et seq.*
,, unripe 14
,, ,, Critchett on .. 21

PAGE

Cataract unripe, extraction of, in its capsule ... 19
" " insufficient surgical resources in . 20
" " Noyes on .. 172, 174
" " objection to term "unripe" ... 24
" " Schweigger on 172, 174
" " Sichel on 21
" " Tweedy on 21
" " uncertainty of diagnosis of 20
Chalky degeneration of lens ... 37
Chinosol .. 71, 75, 81, 110, 111
" a substitute for mercuric preparations 72
" germicidal power of ... 72
" intra-ocular injection of solution of 73
Chloresterine deposits in lens ... 36
Classification of cataract ... 23 *et seq.*
" " developmental 30
" " functional ... 28
" " inferential, objections to 23
" " Llandolt's proposition for 24
" " objections to various methods of ... 22
" " objective ... 23
" " structural 27, 29, 33 *et seq.*
" " surgical 28, 32
Cocaine 81
Complete cataract, definition of ... 30
Combination of injection by fine hollow needle and massage 58
" irrigation with massage .. 59, 60
" scooping with irrigation 59
Complicated cataract 38
" " cases of 166 *et seq.*
Conclusions ... ... 182 *et seq.*
Conjunctiva, microbes of the ... 74
Cornea, slow healing of 113
" suppuration of 111
" total want of reparative power of 115
Cortical cataract 29, 33
" " common form of ... 33
" " " " cases of ... 126 *et seq.*
" " distinction of, from nuclear 30
" " incomplete 33
" " " cases of 126 *et seq.*
" " uncommon forms of 34, 35
" " " " cases of ... 144 *et seq.*
" substance 15
" " diagnosis of hard, by hollow needle 61

PAGE

Cortical substance, diagnosis of soft, by needle 55, 61, 62
" " methods of dealing with ... 54 *et seq.*
" " " efficiency of 169, 170
" " transparent, sclerosis of ... 61, 174
Critchett on incomplete cataract ... 21
Cupping, wet, simple method of ... 117

Diagnosis of consistence of cataract 18
" hollow needle in " ... " 60 *et seq.*
Diagnosis of consistence of cataract, uncertainty of 20
Discission 76, 96
" preliminary ... 19, 54

Elasticity of capsule of lens—Bowman on 194
Electric light for operations 79
Endothelium of anterior chamber, action of various agents on the ... 90
Examination of patient 39
" " objective ... 39
" " " oblique illumination in 40
Examination of patient, objective, ophthalmoscope in ... 40 *et seq.*
Examination of patient, objective, simple inspection in 39
Examination of patient, subjective ... 44
" phosphenes 49
Extraction of lens in its capsule . 19
" simple linear ... 76, 97
" Wecker's 3 mm. flap 76, 98
" " " " variations of 103, 104

Financial results of early operation 180 *et seq.*
Flame of spirit lamp 69
Floating nucleus 37
Foster's artificial maturation of cataract 19, 54
Foster's artificial maturation of cataract, Noyes on... 172
Foster's artificial maturation of cataract, Schweigger on 172
Functional classification of cataract 31

Gayet's intra-ocular antisepticism by mercurial solutions 90
Germicidal agents ... ... 67 *et seq.*
Glaucoma, acute, before operation ... 107
Gravitation bottle 195

Heating to kill spores 69
Hollow needle for intra-capsular injection 54, 55
Hollow needle for intra-capsular injection, physical action of ... 54, 55

PAGE

Hospital, operations for cataract for year 1897 in 180
Hospital, operations for cataract for year 1897 in, review of results of 180 *et seq.*

Hydro-naphthol 71

Immediate extraction of incomplete cataract 20
Incidents, post-operative 110 *et seq.* 171
Incomplete cataract (see "Cataract")
Inferential terms for classification, objection to... ... ... 23, 24
Incubator 86
Injection, intra-capsular, by hollow needle 54
Injection, intra-capsular, by hollow needle, combination of massage with 58
Injection, intra-capsular, by hollow needle, diagnostic and prognostic value of ... . 60 *et seq.*
Injection, intra-capsular, by hollow needle, physical action of ... 54, 55
Injection, intra-capsular, by hollow needle, technique of 93
Instruments for discission 76
" " intra-capsular injection ... 82 *et seq.*
" " intra-ocular irrigation ... 82 *et seq.*
" " secondary operation 78
" " simple linear extraction ... 76
" " Wecker's 3 mm. flap operation ... 76
" preparation of . 75 *et seq.*
Iodoform 71, 112
Iridectomy in cataract extraction, advantages of 191
Iridectomy in cataract extraction, disadvantages of 192
Iridectomy in cataract extraction, discussion of the question of 185 *et seq.*
Iridectomy in zonular cataract ... 104
Irido-choroiditis .. ... 116 *et seq.*
Iris, prolapse of ... ... 185 *et seq.*
" " Knapp on ... 186
" " Panas on 190
" " Schweigger on .. 187
" " Taylor on 191
" " Webster on 186
Iritis, aetiology of, in general ... 117
" post-operative ... 116 *et seq.*
" septic 117
" treatment of ... ... 116 *et seq.*
Irrigation, intra-ocular ... 55, 57, 58
" " combination of massage with 59
" " combination of scooping with 59
" " hypopyon treated by ... 195

PAGE

Irrigation, intra-ocular, liquid to be used for ... 89
" " physical action of 58
" " slight or free 88
" " technique of 95
" " toilette of wound by 102
Irrigator, modes of using 87
" preparation of 82 *et seq.*
" temperature of 86

Jet, form of, from irrigating nozzle ... 60

Knapp—abscission of prolapse of iris 189
" knife needle 125
" statistics of prolapse of iris 186

Lamp for operations, acetylene ... 80
" " " electric ... 79
Leech, Heurteloup's artificial ... 117
" " " substitute for 117
Leeching 116
Lens, typical conditions of 53
Light suitable for operations ... 79
" perception of, amount of ... 44
" " sudden diminution of ... 46
" " " case of 46
" " temporary diminution of ... 47
" " " case of 48
" sensibility to, central peripheral 45
Linear extraction 76, 97
Llandolt on operability of cataract 24, 25

Massage 55, 56, 58, 59
" physical action of 56
Mercury, perchloride of 70
" " germicidal power of 70, 71
" biniodide of 71
" " Panas' solution of, for intra-ocular antisepticism ... 90
Mercuric preparations, objections to 72
" " action of, on endothelium of anterior chamber ... 90
" " action of, on cornea ... 90
Micro-organisms to be killed ... 67
Microbes of conjunctiva, Gayet on ... 74
Monocular cataract 180, 184
Mydriatic for examination ... 41 *et seq.*

Needle operation 76, 96
" " preliminary 19, 54
" hollow 85

PAGE

Needle, hollow, difficulty of introducing inside capsule 61, 105, 175
" " ease of introducing inside capsule 61, 62
" " injection by 54
Noyes on Foster's artificial maturation 172
" " incomplete cortical cataract 172
" " " nuclear " 174
Nozzle, common irrigating 85
" scoop " 85
Nuclear cataract 29, 30, 31, 35, 61, 156 *et seq.*, 173, 174, 175
Nucleo-cortical 29, 36
Nuel and Cornil on endothelium of anterior chamber 90
" " intra-ocular antisepticism ... 90

Oblique illumination 40
Objective terms for classification ... 23
Onset of cataract 49
Operable cataract—Llandolt's proposition of term 24
Operability of cataract, diversity of views of surgeons as to ... 24, 25
Operability of cataract, Llandolt on 25
Operation—
artificial maturation 19
behaviour of various descriptions of cataract on operation ... 62 *et seq.*
needle 96
nervous shock from, case of 122, 123
secondary ... 124 *et seq.*, 188, 189
simple linear extraction 97
Wecker's 3 mm. flap 98

Panas' method of intra-ocular antisepticism 90
" on prolapse of iris ... 186, 189
" " sclerosis of transparent cortex 61
Panophthalmitis 186
Patient, age of 50
" general history and condition of 51
" material well-being of, early operation for 179
" preparation of 74
" story of 52
Phosphenes, examination of ... 49
Physical action of intra-capsular injection ... 54, 55
" " irrigation 57, 58
" " massage 56
" " scooping ... 56
Prejudices, tenacity of 90
Preliminary needle operation for incomplete cataract 19, 54
Pressure in removal of cortical substance 55, 56
Prolapse of iris in simple extraction 18, 185 *et seq.*

PAGE

Prolapse of iris in simple extraction, causes of ... ... 190 *et seq.*
Prolapse of iris in simple extraction, causes of, Panas on 190
Prolapse of iris in simple extraction, percentages of ... ... 185 *et seq.*
Prolapse of iris in simple extraction, prevention of ... ... 189 *et seq.*
Prolapse of iris in simple extraction, prevention of, Taylor's method of 191
Prolapse of iris in simple extraction, prevention of, Schweigger's method of 191
Prolapse of iris in simple extraction, results of ... ... 185 *et seq.*
Prolapse of vitreous ... 105 *et seq.* 184

Remarks on tabular statement of cases ... ... 168 *et seq.*
Reparative power, total want of ... 115
Results of operations 173, 175, 179 *et seq.*
" " " for year 1897 179 *et seq.*
Ripeness of cataract 174

Saline solution for intra-ocular injection 182
Schweigger on cortical cataract ... 172
" " nuclear cataract ... 174
" " prolapse of iris 187 *et seq.*
" " sclerosis of lens ... 174
Sclerosis of lens 174
" " Noyes on 173
" " Schweigger on ... 174
Scooping out cortex ... ... 55 *et seq.*
" combination of, with irrigation 59
Secondary cataract ... 37, 124 *et seq.*
" operations 124 *et seq.* 188, 189
Senile cataract 26
Shock from cataract operation ... 122
Shrivelled lens 36
Sichel on incomplete cataract ... 21
Simple extraction 174
Simple inspection 39
Speville, Dr. de, on slow healing of the wound 114
Spirit lamp, flame of 69
Steam in motion 69
Structural classification ... 27, 29
St. Yves on incomplete nuclear cataract 61
" " cataract in young persons with nucleus 155
Suppuration of wound 111
" " efficient antisepticism in ... 112
" " hot stuping in 112
" " iodoform in ... 112
" " prognosis in ... 113
" " stimulants in 112, 113
Swanzy on the combined operation 188

PAGE

Tables of cases of cataract—
complicated ... 166 *et seq.*
cortical, incomplete, common form, in persons under 30 years 126, 127
cortical, incomplete, common form, in persons from 30 to 60 127 *et seq.*
cortical, incomplete, common form, in persons 60 years and upwards 137 *et seq.*
cortical, incomplete, uncommon and special forms, barred 151 *et seq.*
cortical, incomplete, uncommon and special forms, in myopia 147 *et seq.*
cortical, incomplete, uncommon and special forms, posterior polar ... ... 153 *et seq.*
cortical, incomplete, uncommon and special forms, semi-transparent cortex ... ... 144 *et seq.*
nuclear, incomplete, in persons under 60 years ... ... 156 *et seq.*
nuclear, incomplete, in persons 60 years and upwards ... 160 *et seq.*
zonular, with nucleus ... 155, 156
Tables shewing behaviour of different forms of cataract ... .. 62 *et seq.*
Taylor's method of preventing prolapse of iris 191

PAGE

Temperature, how to maintain irrigating apparatus at suitable ... 86
Tension, high 106
Terms, inferential, objection to ... 23
" objections to various 23, 24
Toilette of wound 102
Traumatic cataract 37, 184
" " four different classes of ... 107
" " operations on ... 107
Tweedy on incomplete cataract ... 21
Tyndall's discontinuous heating ... 69

Valude on slow healing of the wound 115
Vision, degree of 44
Vitreous, prolapse of ... 105 *et seq.* 184

Wecker's 3 mm. flap 98
Well-being of patient, early operation in relation to 180
Wound, slow healing of 113
" " " Dr. de Speville on ... 114
" " " Valude on ... 115
" suppuration of 111

Zonule of Zinn in incomplete cataract 184

THE END.

CATALOGUE OF WORKS

PUBLISHED BY

H. K. LEWIS

136 GOWER STREET, LONDON, W.C.

Established 1844.

A. C. ABBOTT, M.D.
First Assistant, Laboratory of Hygiene, Univers ty of Pennsylvania.

THE PRINCIPLES OF BACTERIOLOGY: A Practical Manual for Students and Physicians. With Illustrations, post 8vo, 7s. 6d.

H. ALDER-SMITH, M.B. LOND., F.R.C.S.
Resident Medical Officer, Christ's Hospital, London.

RINGWORM: Its Diagnosis and Treatment. Third Edition, enlarged, with Illustrations, fcap. 8vo, 5s. 6d.

HARRISON ALLEN, M.D.
Consulting Physician to Rush Hospital for Consumption.

A HANDBOOK OF LOCAL THERAPEUTICS. General Surgery by R. H. HARTE, M.D., Surgeon to the Episcopal and St. Mary's Hospitals; Diseases of the Skin by A. VAN HARLINGEN, M.D., Professor of Diseases of the Skin in the Philadelphia Polyclinic; Diseases of the Ear and Air Passages by H. ALLEN, M.D.; Diseases of the Eye by G. C. HARLAN, M.D., Surgeon to Wills Eye Hospital. Edited by H. ALLEN, M.D. Large 8vo, 14s. *nett.*

E. CRESSWELL BABER, M.B. LOND.
Surgeon to the Brighton and Sussex Throat and Ear Hospital.

A GUIDE TO THE EXAMINATION OF THE NOSE, WITH REMARKS ON THE DIAGNOSIS OF DISEASES OF THE NASAL CAVITIES. With Illustrations, small 8vo, 5s. 6d.

JAMES B. BALL, M.D. LOND., M.R.C.P.
Physician to the Department for Diseases of the Throat and Nose, and Senior Assistant Physician, West London Hospital.

I.

A HANDBOOK OF DISEASES OF THE NOSE AND NASO-PHARYNX. With Illustrations, large post 8vo, 6s.

II.

INTUBATION OF THE LARYNX. With Illustrations, demy 8vo, 2s. 6d.

G. GRANVILLE BANTOCK, M.D., F.R.C.S. EDIN.
Surgeon to the Samaritan Free Hospital for Women and Children.

I.

ON THE USE AND ABUSE OF PESSARIES. Second Edition, with Illustrations, 8vo, 5s.

II.

ON THE TREATMENT OF RUPTURE OF THE FEMALE PERINEUM IMMEDIATE AND REMOTE. Second Edition, with Illustrations, 8vo, 3s. 6d.

III.

A PLEA FOR EARLY OVARIOTOMY. Demy 8vo, 2s.

ARTHUR E. J. BARKER, F.R.C.S.
Hunterian Professor of Surgery and Pathology; Surgeon to University College Hospital.

HUNTERIAN LECTURES ON INTRA-CRANIAL INFLAMMATIONS STARTING IN THE TEMPORAL BONE, THEIR COMPLICATIONS AND TREATMENT. 8vo, 3s. *nett.*

FANCOURT BARNES, M.D., M.R.C.P.
Physician to the Chelsea Hospital for Women; Obstetric Physician to the Great Northern Hospital, &c.

A GERMAN-ENGLISH DICTIONARY OF WORDS AND TERMS USED IN MEDICINE AND ITS COGNATE SCIENCES. Square 12mo, Roxburgh binding, 9s.

JAMES BARR, M.D.
Physician to the Northern Hospital, Liverpool; Medical Officer of Her Majesty's Prison, Kirkdale, &c.

THE TREATMENT OF TYPHOID FEVER, and reports of fifty-five consecutive cases with only one death. With Introduction by W. T. GAIRDNER, M.D., LL.D., Professor of Medicine in the University of Glasgow. With Illustrations, demy 8vo, 6s.

ASHLEY W. BARRETT, M.B. LOND., M.R.C.S., L.D.S.E.
Dental Surgeon to, and Lecturer on Dental Surgery in the Medical School of, the London Hospital.

DENTAL SURGERY FOR MEDICAL PRACTITIONERS AND STUDENTS OF MEDICINE. Second edition, with Illustrations, cr. 8vo, 3s. 6d. [*Now ready.*

[LEWIS'S PRACTICAL SERIES.]

ROBERTS BARTHOLOW, M.A., M.D., LL.D.
Professor of Materia Medica and Therapeutics in the Jefferson Medical College of Philadelphia, &c., &c.

A TREATISE ON THE PRACTICE OF MEDICINE, FOR THE USE OF STUDENTS AND PRACTITIONERS. Fifth Edition, with Illustrations, large 8vo, 21s.

H. CHARLTON BASTIAN, M.A., M.D., F.R.S., F.R.C.P.
Professor of the Principles and Practice of Medicine in University College, London; Physician to University College Hospital, &c.

I.

PARALYSES: CEREBRAL, BULBAR, AND SPINAL. A MANUAL OF DIAGNOSIS FOR STUDENTS AND PRACTITIONERS. With numerous Illustrations, 8vo, 12s. 6d.

II.

VARIOUS FORMS OF HYSTERICAL OR FUNCTIONAL PARALYSIS. Demy 8vo, 7s. 6d.

GEO. M. BEARD, A.M., M.D.
AND
A. D. ROCKWELL, A.M., M.D.
Formerly Professor of Electro-Therapeutics in the New York Post Graduate Medical School; Fellow of the New York Academy of Medicine, &c.

I.

ON THE MEDICAL AND SURGICAL USES OF ELECTRICITY. Eighth Edition. With over 200 Illustrations, roy. 8vo, 28s. [*Just published.*

II.

NERVOUS EXHAUSTION (NEURASTHENIA) ITS HYGIENE, CAUSES, SYMPTOMS AND TREATMENT. Second edition, 8vo, 7s. 6d.

W. M. BEAUMONT.
Surgeon to the Bath Eye Infirmary.

THE SHADOW-TEST IN THE DIAGNOSIS AND ESTIMATION OF AMETROPIA. Post 8vo, 2s. 6d.

E. H. BENNETT, M.D., F.R.C.S.I.
Professor of Surgery, University of Dublin,
AND
D. J. CUNNINGHAM, M.D., F.R.C.S.I.
Professor of Anatomy and Chirurgery, University of Dublin.

THE SECTIONAL ANATOMY OF CONGENITAL CŒCAL HERNIA. With coloured plates, sm. folio, 5s. 6d.

A. HUGHES BENNETT, M.D., M.R.C.P.
Physician to the Hospital for Epilepsy and Paralysis, Regent's Park, and Assistant Physician to the Westminster Hospital.

I.

A PRACTICAL TREATISE ON ELECTRO-DIAGNOSIS IN DISEASES OF THE NERVOUS-SYSTEM. With Illustrations, 8vo, 8s. 6d.

II.

ILLUSTRATIONS OF THE SUPERFICIAL NERVES AND MUSCLES, WITH THEIR MOTOR POINTS; a knowledge of which is essential in the Art of Electro-Diagnosis. 8vo, cloth, 2s.

HORATIO R. BIGELOW, M.D.
Permanent Member of the American Medical Association; Fellow of the British Gynæcological Society, &c.

I.

GYNÆCOLOGICAL ELECTRO-THERAPEUTICS. With an Introduction by Dr. Georges Apostoli. With Illustrations, demy 8vo, 8s. 6d.

II.

PLAIN TALKS ON ELECTRICITY AND BATTERIES, WITH THERAPEUTIC INDEX, FOR GENERAL PRACTITIONERS AND STUDENTS OF MEDICINE. With Illustrations, crown 8vo, 4s. 6d.

DR. THEODOR BILLROTH.
Professor of Surgery in Vienna.

GENERAL SURGICAL PATHOLOGY AND THERAPEUTICS. With additions by Dr. Alexander von Winiwarter, Professor of Surgery in Luttich. Translated from the Fourth German edition, and revised from the Tenth edition, by C. E. Hackley, A.M., M.D. 8vo, 18s.

DRS. BOURNEVILLE AND BRICON.

MANUAL OF HYPODERMIC MEDICATION. Translated from the Second Edition, and Edited, with Therapeutic Index of Diseases, by ANDREW S. CURRIE, M.D. Edin., &c. With Illustrations, crown 8vo, 3s. 6d.

RUBERT BOYCE, M.B., M.R.C.S.
Assistant Professor of Pathology in University College, London.

A TEXT-BOOK OF MORBID HISTOLOGY for Students and Practitioners. With 130 coloured Illustrations, royal 8vo, 31s. 6d. [*Now ready.*

GURDON BUCK, M.D.

CONTRIBUTIONS TO REPARATIVE SURGERY: Showing its Application to the Treatment of Deformities, produced by Destructive Disease or Injury; Congenital Defects from Arrest or Excess of Development; and Cicatricial Contractions from Burns. Large 8vo, 9s.

MARY BULLAR & J. F. BULLAR, M.B. CANTAB., F.R.C.S.

RECEIPTS FOR FLUID FOODS. 16mo, 1s.

CHARLES H. BURNETT, A.M., M.D.
Emeritus Professor in the Philadelphia Polyclinic College for Graduates in Medicine; Clinical Professor of Otology in the Woman's Medical College of Pennsylvania; Aurist to the Presbyterian Hospital, Philadelphia.

SYSTEM OF DISEASES OF THE EAR, NOSE AND THROAT. By 45 Eminent American, British, Canadian and Spanish Authors. Edited by CHARLES H. BURNETT. With Illustrations, in two mperial 8vo vols., 48s. *nett.* [*Nearly ready.*

STEPHEN SMITH BURT, M.D.
Professor of Clinical Medicine and Physical Diagnosis in the New York Post-graduate School and Hospital.

EXPLORATION OF THE CHEST IN HEALTH AND DISEASE. With Illustrations, crown 8vo, 6s.

DUDLEY W. BUXTON, M.D., B.S., M.R.C.P.
Administrator of Anæsthetics and Lecturer in University College Hospital, the National Hospital for Paralysis and Epilepsy, Queen's Square, and the Dental Hospital of London.

ANÆSTHETICS THEIR USES AND ADMINISTRA-TION. Second edition, with illustrations, crown 8vo, 5s. [*Now ready.*
[LEWIS'S PRACTICAL SERIES.]

HARRY CAMPBELL, M.D., B.S. LOND., M.R.C.P.
Assistant Physician and Pathologist to the North-West London Hospital.

THE CAUSATION OF DISEASE: An exposition of the ultimate factors which induce it. Demy 8vo, 12s. 6d.

II.

FLUSHING AND MORBID BLUSHING: THEIR PATHOLOGY AND TREATMENT. With plates and wood engravings, royal 8vo, 10s. 6d. [*Now ready.*

III.

DIFFERENCES IN THE NERVOUS ORGANISA-TION OF MAN AND WOMAN, PHYSIOLOGICAL AND PATHOLOGICAL. Royal 8vo, 15s. [*Now ready.*

R. E. CARRINGTON, M.D., F.R.C.P.
Late Assistant Physician and Senior Demonstrator of Morbid Anatomy at Guy's Hospital.

NOTES ON PATHOLOGY. With an Introductory Chapter by J. F. GOODHART, M.D. (ABERD.), F.R.C.P., Physician to Guy's Hospital, Edited by H. EVELYN CROOK, M.D. LOND., F.R.C.S. ENG., and GUY MACKESON, L.R.C.P., M.R.C.S. Crown 8vo, 3s. 6d. [*Now ready.*

ALFRED H. CARTER, M.D. LOND.
Fellow of the Royal College of Physicians; Physician to the Queen's Hospital, Birmingham; Professor of Therapeutics in Queen's College, Birmingham.

ELEMENTS OF PRACTICAL MEDICINE. Sixth Edition, crown 8vo, 9s. [*Just published.*

F. H. CHAMPNEYS, M.A., M.D. OXON., F.R.C.P.
Physician-Accoucheur and Lecturer on Obstetric Medicine at St. Bartholomew's Hospital: Examiner in Obstetric Medicine in the University of Oxford, &c.

I.

LECTURES ON PAINFUL MENSTRUATION. THE HARVEIAN LECTURES, 1890. Roy. 8vo, 7s. 6d. [*Just published.*

II.

EXPERIMENTAL RESEARCHES IN ARTIFICIAL RESPIRATION IN STILLBORN CHILDREN, AND ALLIED SUBJECTS. Crown 8vo, 3s. 6d.

W. BRUCE CLARKE, M.A., M.B. OXON., F.R.C.S.
Assistant Surgeon to, and Senior Demonstrator of Anatomy and Operative Surgery at, St. Bartholomew's Hospital; Surgeon to the West London Hospital, &c.

THE DIAGNOSIS AND TREATMENT OF DISEASES OF THE KIDNEY AMENABLE TO DIRECT SURGICAL INTERFERENCE. With Illustrations, demy 8vo, 7s. 6d.

JOHN COCKLE, M.A., M.D.
Physician to the Royal Free Hospital.

ON INTRA-THORACIC CANCER. 8vo, 4s. 6d.

ALEXANDER COLLIE, M.D. ABERD., M.R.C.P. LOND.
Secretary of the Epidemiological Society for Germany and Russia, &c.

ON FEVERS: THEIR HISTORY, ETIOLOGY, DIAGNOSIS, PROGNOSIS, AND TREATMENT. Illustrated with Coloured Plates, crown 8vo, 8s. 6d. [LEWIS'S PRACTICAL SERIES.]

M. P. MAYO COLLIER, M.B., M.S. LOND., F.R.C.S. ENG.
Professor of Comparative Anatomy and Physiology at the Royal College of Surgeons, England, &c.

THE PHYSIOLOGY OF THE VASCULAR SYSTEM. Illustrations, 8vo, 3s. 6d.

WALTER S. COLMAN, M.B., M.R.C.P. LOND.
Pathologist and Registrar to the National Hospital for the Paralysed and Epileptic;

SECTION CUTTING AND STAINING: A Practical Guide to the Preparation of Normal and Morbid Histological Specimens. Crown 8vo, 3s. [*Now ready.*

W. H. CORFIELD, M.A., M.D. OXON.
Professor of Hygiene and Public Health in University College, London.

DWELLING HOUSES: their Sanitary Construction and Arrangements. Third Edition, with Illustrations. Crown 8vo. [*In preparation.*

J. LEONARD CORNING, M.A., M.D.
Consultant in Nervous Diseases to St. Francis Hospital.

A PRACTICAL TREATISE ON HEADACHE, NEU-RALGIA, SLEEP AND ITS DERANGEMENTS, AND SPINAL IRRITATION. With an Appendix—Eye Strain, a Cause of Headache. By DAVID WEBSTER, M.D. Second edition, Demy 8vo, 7s. 6d.

EDWARD COTTERELL, F.R.C.S. ENG., L.R.C.P. LOND.
Late House Surgeon, University College Hospital.

ON SOME COMMON INJURIES TO LIMBS; their Treatment and After-treatment, including Bone-setting (so-called). With Illustrations, small 8vo, 3s. 6d.

SIDNEY COUPLAND, M.D., F.R.C.P.
Physician to the Middlesex Hospital, and Lecturer on Practical Medicine in the Medical School; late Examiner in Medicine at the Examining Board for England.

NOTES ON THE CLINICAL EXAMINATION OF THE BLOOD AND EXCRETA. Third edition, 12mo, 1s. 6d.
[*Just ready.*

CHARLES CREIGHTON, M.D.

I.

ILLUSTRATIONS OF UNCONSCIOUS MEMORY IN DISEASE, including a Theory of Alteratives. Post 8vo, 6s.

II.

CONTRIBUTIONS TO THE PHYSIOLOGY AND PATHOLOGY OF THE BREAST AND LYMPHATIC GLANDS. New Edition with additional chapter, with wood-cuts and plate, 8vo, 9s.

III.

BOVINE TUBERCULOSIS IN MAN: An Account of the Pathology of Suspected Cases. With Chromo-lithographs and other Illustrations, 8vo, 8s. 6d.

H. RADCLIFFE CROCKER, M.D. LOND., B.S., F.R.C.P.
Physician for Diseases of the Skin in University College Hospital, &c.

DISEASES OF THE SKIN; THEIR DESCRIPTION, PATHOLOGY, DIAGNOSIS, AND TREATMENT. Second Edition, with 92 Illustrations, 8vo, 24s. [*Just published.*

EDGAR M. CROOKSHANK, M.B. LOND., F.R.M.S.
Professor of Comparative Pathology and Bacteriology in, and Fellow of King's College London.

I.

MANUAL OF BACTERIOLOGY: Illustrated with Coloured Plates from original drawings, and with other Illustrations in the text. Third Edition, 8vo, 21s. [*Now ready.*

II.

HISTORY AND PATHOLOGY OF VACCINATION. Vol. I., A Critical Inquiry. Vol. II., Selected Essays, (Edited) including works by Jenner, Pearson, Woodville, Henry Jenner, Loy, Rogers, Birch, Bousquet, Estlin, Ceely, Badcock, Auzias-Turenne, Dubreuilh and Layet. Two volumes, illustrated with 22 coloured plates, including reproductions of the plates illustrating Jenner's Inquiry, of selected plates from the work of Ceely and others, and with a reduced facsimile of an engraving of Mr. Jesty, a facsimile of the first folio of the manuscript of Jenner's original paper, a facsimile of an unpublished letter from Jenner to Mr. Head. Royal 8vo, 36s.

J. BRENDON CURGENVEN, M.R.C.S., L.S.A.
Formerly House Surgeon to the Royal Free Hospital; Honorary Secretary of the Harveian Society, the Infant Life Protection Society, &c.

THE DISINFECTION OF SCARLET FEVER AND OTHER DISEASES BY ANTISEPTIC INUNCTION. 8vo, 1s. 6d.

RIDLEY DALE, M.D., L.R.C.P. EDIN., M.R.C.S. ENG.

EPITOME OF SURGERY, being a complete compendium of the Science and Art of Surgery. Large 8vo, 10s. 6d.

HERBERT DAVIES, M.D., F.R.C.P.
Late Consulting Physician to the London Hospital.

THE MECHANISM OF THE CIRCULATION OF THE BLOOD THROUGH ORGANICALLY DISEASED HEARTS. Edited by ARTHUR TEMPLER DAVIES, B.A. (Nat. Science Honours), M.D. Cantab., M.R.C.P.; Physician to the Royal Hospital for Diseases of the Chest. Crown 8vo, 3s. 6d.

HENRY DAVIS, M.R.C.S.
Teacher and Administrator of Anæsthetics at St. Mary's Hospital, and Assistant Anæsthetist to the Dental Hospital of London.

GUIDE TO THE ADMINISTRATION OF ANÆSTHE-TICS. Second edition, fcap. 8vo, 2s. 6d. [*Now ready.*

J. THOMPSON DICKSON, M.A., M.B. CANTAB.
Late Lecturer on Mental Diseases at Guy's Hospital.

THE SCIENCE AND PRACTICE OF MEDICINE IN RELATION TO MIND, the Pathology of the Nerve Centres, and the Jurisprudence of Insanity being a course of Lectures delivered at Guy's Hospital. Illustrated by Chromo-lithographic Drawings and Physiological Portraits. 8vo, 14s.

F. A. DIXEY, M.A., D.M.
Fellow of Wadham College, Oxford.

EPIDEMIC INFLUENZA: A Study in Comparative Statistics. With Diagrams and Tables. 8vo, 7s. 6d. [*Now ready.*

HORACE DOBELL, M.D.
Consulting Physician to the Royal Hospital for Diseases of the Chest, &c.

I.

ON DIET AND REGIMEN IN SICKNESS AND Health and on the Interdependence and Prevention of Diseases and the Diminution of their Fatality. Seventh Edition, 8vo, 5s. *nett.*

II.

AFFECTIONS OF THE HEART AND IN ITS NEIGH-BOURHOOD. Cases, Aphorisms, and Commentaries. Illustrated by the heliotype process. 8vo, 6s. 6d.

CHARLES W. DULLES, M.D.
Fellow of the College of Physicians of Philadelphia and of the Academy of Surgery; Physician to the Rush Hospital.

ACCIDENTS AND EMERGENCIES: A Manual of the Treatment of Surgical and Medical Emergencies in the absence of a Physician. Fourth Edition, with Illustrations, post 8vo, 3s. *nett.*
[*Now ready.*

JOHN EAGLE.
Member of the Pharmaceutical Society.

A NOTE-BOOK OF SOLUBILITIES. Arranged chiefly for the use of Prescribers and Dispensers. 12mo, 2s. 6d.

ARTHUR W. EDIS, M.D. LOND., F.R.C.P.
Senior Physician to the Chelsea Hospital for Women; Late Obstetric Physician to the Middlesex Hospital.

STERILITY IN WOMEN: including its Causation and Treatment. With 33 Illustrations, demy 8vo, 6s. [*Just published.*

DR. FERBER.

MODEL DIAGRAM OF THE ORGANS IN THE THORAX AND UPPER PART OF THE ABDOMEN. With Letter-press Description. In 4to, coloured, 5s.

J. MAGEE FINNY, M.D. DUBL.
King's Professor of Practice of Medicine in School of Physic, Ireland, &c.

NOTES ON THE PHYSICAL DIAGNOSIS OF LUNG DISEASES. 32mo, 1s. 6d. [*Now ready.*

AUSTIN FLINT, M.D., LL.D.
Professor of Physiology and Physiological Anatomy in the Bellevue Hospital Medical College, New York, visiting Physician to the Bellevue Hospital, &c.

A TEXT-BOOK OF HUMAN PHYSIOLOGY. Fourth edition, Illustrated by plates, and 316 wood engravings, large 8vo, 25s.

W. H. RUSSELL FORSBROOK, M.D. LOND., M.R.C.S.
Consulting Medical Officer to the Government of the Cape of Good Hope; formerly Surgical Registrar to Westminster Hospital

A DISSERTATION ON OSTEO-ARTHRITIS. Demy 8vo, 5s.

J. MILNER FOTHERGILL, M.D., M.R.C.P.
Late Physician to the City of London Hospital for Diseases of the Chest, Victoria Park, &c.

I.

A MANUAL OF DIETETICS. Large 8vo, 10s. 6d.

II.

INDIGESTION AND BILIOUSNESS. Second Edition, post 8vo, 7s. 6d.

III.

GOUT IN ITS PROTEAN ASPECTS. Post 8vo, 7s. 6d.

IV.

THE TOWN DWELLER: His Needs and His Wants. With an Introduction by SIR B. W. RICHARDSON, M.D., LL.D., F.R.S. Post 8vo, 3s. 6d.

FORTESCUE FOX, M.D. LOND.
Fellow of the Medical Society of London.

STRATHPEFFER SPA: Its Climate and Waters. With OBSERVATIONS HISTORICAL, MEDICAL, AND GENERAL, DESCRIPTIVE OF THE VICINITY. With Map and Illustrations, crown 8vo, 2s. 6d. *nett.*

PROFESSOR E. FUCHS.
Professor of Ophthalmology in the University of Vienna.

TEXTBOOK OF OPHTHALMOLOGY.
Translated from the German by A. DUANE, M.D., Assistant Surgeon, Ophthalmic and Aural Institute, New York. Second Edition, with 190 Illustrations, large octavo, 21s. [*Now ready.*

JOHN HENRY GARRETT, M.D.
Licentiate in Sanitary Science and Diplomate in Public Health, Universities of Durham and Cambridge, &c.

THE ACTION OF WATER ON LEAD; being an inquiry into the Cause and Mode of the Action and its Prevention. Crown 8vo, 4s. 6d.

ALFRED W. GERRARD, F.C.S.
Examiner to the Pharmaceutical Society; Teacher of Materia Medica and Pharmacy at University College Hospital.

I.

ELEMENTS OF MATERIA MEDICA AND PHARMACY. Crown 8vo, 8s. 6d.

II.

NEW OFFICIAL REMEDIES, B.P., 1890. Supplement to the above. Crown 8vo, 1s.

HENEAGE GIBBES, M.D.
Lecturer on Physiology and on Normal and Morbid Histology in the Medical School of Westminster Hospital; etc.

PRACTICAL HISTOLOGY AND PATHOLOGY. Third Edition, revised and enlarged, crown 8vo, 6s.

JAMES F. GOODHART, M.D. ABERD., F.R.C.P.
Physician to Guy's Hospital, and Consulting Physician to the Evelina Hospital for Sick Children.

ON COMMON NEUROSES: or the Neurotic Element in Disease and its Rational Treatment. The Harveian Lectures for 1891. Crown 8vo, 2s. 6d. [*Just published.*

C. A. GORDON, M.D., C.B.
Deputy Inspector General of Hospitals, Army Medical Department.

REMARKS ON ARMY SURGEONS AND THEIR WORKS. Demy 8vo, 5s.

JOHN GORHAM, M.R.C.S.

TOOTH EXTRACTION: a Manual on the proper mode of extracting Teeth. Fourth Edition, fcap. 8vo, 1s. 6d. [*Now ready.*

GEORGE M. GOULD, A.M., M.D.
Ophthalmic Surgeon to the Philadelphia Hospital, etc.

I.

A NEW MEDICAL DICTIONARY: including all the words and phrases used in Medicine, with their proper pronunciation and definitions. 8vo, 12s. 6d.

II.

A POCKET MEDICAL DICTIONARY, Giving the Pronunciation and Definition of about 12000 of the Principal Words used in Medicine and the Collateral Sciences. 32mo, 4s. *nett.*

W. R. GOWERS, M.D., F.R.C.P., M.R.C.S.
Physician to University College Hospital, &c.

DIAGRAMS FOR THE RECORD OF PHYSICAL SIGNS. In books of 12 sets of figures, 1s.

LANDON C. GRAY, M.D.
Professor of Nervous and Mental Diseases in the New York Polyclinic; Visiting Physician to St. Mary's Hospital, &c.

A TREATISE ON NERVOUS AND MENTAL DISEASES FOR STUDENTS AND PRACTITIONERS OF MEDICINE. With 168 Illustrations, 8vo, 21s.

J. B. GRESSWELL, M.R.C.V.S.
Provincial Veterinary Surgeon to the Royal Agricultural Society.

VETERINARY PHARMACOLOGY AND THERAPEUTICS. With an Index of Diseases and Remedies. Fcap. 8vo, 5s.

A. HILL GRIFFITH, M.D.
Surgeon, Manchester Royal Eye Hospital.

THE DIAGNOSIS OF INTRA-OCULAR GROWTHS. With 8 woodcuts, 8vo, 1s. 6d.

SAMUEL D. GROSS, M.D., LL.D., D.C.L. OXON.
Professor of Surgery in the Jefferson Medical College of Philadelphia.

A PRACTICAL TREATISE ON THE DISEASES, INJURIES, AND MALFORMATIONS OF THE URINARY BLADDER, THE PROSTATE GLAND, AND THE URETHRA. Third Edition, revised and edited by S. W. GROSS, A.M., M.D., Surgeon to the Philadelphia Hospital. Illustrated by 170 engravings, 8vo, 18s.

SAMUEL W. GROSS, A.M., M.D.
Surgeon to, and Lecturer on Clinical Surgery in, the Jefferson Medical College Hospital and the Philadelphia Hospital, &c.

A PRACTICAL TREATISE ON TUMOURS OF THE MAMMARY GLAND: embracing their Histology, Pathology Diagnosis, and Treatment. With Illustrations, 8vo, 10s. 6d.

PROF. JOSEF GRUBER.
Professor of Otology in the Imperial Royal University of Vienna, etc.

A TEXT-BOOK OF THE DISEASES OF THE EAR. Translated from the second German edition by special permission of the Author, and Edited by EDWARD LAW, M.D., C.M. EDIN., M.R.C.S. ENG., Surgeon to the London Throat Hospital for Diseases of the Throat, Nose and Ear; and by COLEMAN JEWELL, M.B. LOND., M.R.C.S. ENG., late Physician and Pathologist to the London Throat Hospital. Second Edition, with over 150 Illustrations, and 70 coloured figures on 2 lithographic plates, royal 8vo, 28s. [*Just ready.*

ALLAN McLANE HAMILTON, M.D.

THE MODERN TREATMENT OF HEADACHES. Square 16mo, 2s. 6d.

WILLIAM A. HAMMOND, M.D.
Professor of Mental and Nervous Diseases in the Medical Department of the University of the City of New York, &c.

SPIRITUALISM AND ALLIED CAUSES AND CONDITIONS OF NERVOUS DERANGEMENT. With Illustrations, post 8vo, 8s. 6d.

ALEXANDER HARVEY, M.D.
Late Emeritus Professor of Materia Medica in the University of Aberdeen, &c.,

AND

ALEXANDER DYCE DAVIDSON, M.D., F.R.S. EDIN.
Late Regius Professor of Materia Medica in the University of Aberdeen.

SYLLABUS OF MATERIA MEDICA FOR THE USE OF STUDENTS, TEACHERS AND PRACTITIONERS. Based on the relative values of articles and preparations in the British Pharmacopœia. Ninth edition, 32mo, 1s. 6d.

W. S. HEDLEY, M.D.

THE HYDRO-ELECTRIC METHODS IN MEDICINE. With Chapters on Current from the Main, Cure-Gymnastics, &c. With Illustrations, 8vo, 4s. 6d. [*Now ready.*

C. HIGGENS, F.R.C.S.
Ophthalmic Surgeon to Guy's Hospital; Lecturer on Ophthalmology at Guy's Hospital Medical School.

MANUAL OF OPHTHALMIC PRACTICE. Illustrations, crown 8vo, 6s. [LEWIS'S PRACTICAL SERIES.]

BERKELEY HILL, M.B. LOND., F.R.C.S.
Professor of Clinical Surgery in University College; Surgeon to University College Hospital and to the Lock Hospital.

THE ESSENTIALS OF BANDAGING. With directions for Managing Fractures and Dislocations; for administering Ether and Chloroform; and for using other Surgical Apparatus; with a Chapter on Surgical Landmarks. Sixth Edition, revised and enlarged, Illustrated by 144 Wood Engravings, crown 8vo, 5s.

BERKELEY HILL, M.B. LOND., F.R.C.S.
Professor of Clinical Surgery in University College; Surgeon to University College Hospital and to the Lock Hospital.

AND

ARTHUR COOPER, L.R.C.P., M.R.C.S.
Surgeon to the Westminster General Dispensary.

I.

SYPHILIS AND LOCAL CONTAGIOUS DISORDERS. Second edition, entirely re-written, royal 8vo, 18s.

II.

THE STUDENT'S MANUAL OF VENEREAL DISEASES. Being a Concise Description of those Affections and of their Treatment. Fourth edition, post 8vo, 2s. 6d.

FROM HOSPITAL WARD TO CONSULTING ROOM, with Notes by the Way; a Medical Autobiography. By a Graduate of the London University. Post 8vo, 3s. 6d.

PROCTER S. HUTCHINSON, M.R.C.S.
Assistant Surgeon to the Hospital for Diseases of the Throat.

A MANUAL OF DISEASES OF THE NOSE AND THROAT; including the Nose, Naso-pharynx, Pharynx, and Larynx. With Illustrations, crown 8vo, 3s. 6d. [*Now ready.*

C. R. ILLINGWORTH, M.D. ED., M.R.C.S.

THE ABORTIVE TREATMENT OF SPECIFIC FE-BRILE DISORDERS BY THE BINIODIDE OF MERCURY. Crown 8vo, 3s. 6d.

SIR W. JENNER, Bart., M.D.
Physician in Ordinary to H.M. the Queen, and to H.R.H. the Prince of Wales.

THE PRACTICAL MEDICINE OF TO-DAY: Two Addresses delivered before the British Medical Association, and the Epidemiological Society, (1869). Small 8vo, 1s. 6d.

GEORGE LINDSAY JOHNSON, M.A., M.B., B.C. CANTAB.
Clinical Assistant, late House Surgeon and Chloroformist, Royal Westminster Ophthalmic Hospital, &c.

A NEW METHOD OF TREATING CHRONIC GLAU-COMA, based on Recent Researches into its Pathology. With Illustrations and coloured frontispiece, demy 8vo, 3s. 6d.

JOHN M. KEATING,
Fellow of the College of Physicians, Philadelphia, &c.
AND
HENRY HAMILTON.

POCKET MEDICAL LEXICON.
32mo, 3s. *nett.*

T. N. KELYNACK, M.D.
Pathologist to the Manchester Royal Infirmary; Demonstrator and Lecturer on Pathology in the Owens College.

A CONTRIBUTION TO THE PATHOLOGY OF THE VERMIFORM APPENDIX. With Illustrations, large 8vo, 10s. 6d.

HENRY R. KENWOOD, M.B., D.P.H., F.C.S.
Instructor in the Hygienic Laboratory, University College, and Assistant to Professor Corfield in the Public Health Department, University College.

PUBLIC HEALTH LABORATORY WORK, including Methods employed in Bacteriological Research, with special reference to the Examination of Air, Water and Food, contributed by RUBERT BOYCE, M.B., Assistant Professor of Pathology, University College. With Illustrations, cr. 8vo, 10s. 6d. [*Now ready.*

[LEWIS'S PRACTICAL SERIES.]

NORMAN KERR, M.D., F.L.S.
President of the Society for the Study of Inebriety; Consulting Physician, Dalrymple Home for Inebriates, etc.

INEBRIETY: its Etiology, Pathology, Treatment, and Jurisprudence. Third edition, 8vo. [*Nearly ready.*

NORMAN W. KINGSLEY, M.D.S., D.D.S.
President of the Board of Censors of the State of New York; Member of the American Academy of Dental Science, &c.

A TREATISE ON ORAL DEFORMITIES AS A BRANCH OF MECHANICAL SURGERY. With over 350 Illustrations, 8vo, 16s.

F. CHARLES LARKIN, F.R.C.S. ENG.
Surgeon to the Stanley Hospital; late Assistant Lecturer in Physiology in University College, Liverpool,

AND

RANDLE LEIGH, M.B., B.SC. LOND.
Senior Demonstrator of Physiology in University College, Liverpool.

OUTLINES OF PRACTICAL PHYSIOLOGICAL CHEMISTRY. Second edition, with Illustrations, crown 8vo, paper 2s. 6d. *nett*, or cloth 3s. *nett*. [*Now ready.*

J. WICKHAM LEGG, F.R.C.P.
Late Assistant Physician to Saint Bartholomew's Hospital, and Lecturer on Pathological Anatomy in the Medical School.

I.

ON THE BILE, JAUNDICE, AND BILIOUS DISEASES. With Illustrations in chromo-lithography, 719 pages, roy. 8vo, 25s.

II.

A GUIDE TO THE EXAMINATION OF THE URINE; intended chiefly for Clinical Clerks and Students. Seventh Edition, revised and enlarged, by H. LEWIS JONES, M.D., Medical Officer in charge of the Electrical Department in St. Barthlomew's Hospital. With Illustrations, fcap. 8vo, 3s. 6d. [*Just ready.*

ARTHUR H. N. LEWERS, M.D. LOND., M.R.C.P. LOND.
Obstetric Physician to the London Hospital; Examiner in Midwifery and Diseases of Women to the Society of Apothecaries of London, &c.

A PRACTICAL TEXTBOOK OF THE DISEASES OF WOMEN. Fourth edition, Illustrations, crown 8vo, 10s. 6d. [*Now ready.*
[LEWIS'S PRACTICAL SERIES.]

LEWIS'S POCKET CASE BOOK FOR PRACTITIONERS AND STUDENTS. Roan, with pencil, 3s. 6d. *nett.*

LEWIS'S POCKET MEDICAL VOCABULARY. Second Edition, thoroughly revised, 32mo, roan, 3s. 6d.

T. R. LEWIS, M.B., F.R.S. ELECT, ETC.
Late Fellow of the Calcutta University, Surgeon-Major Army Medical Staff, &c.

PHYSIOLOGICAL & PATHOLOGICAL RESEARCHES. Arranged and edited by SIR WM. AITKEN, M.D., F.R.S., G. E. DOBSON, M.B., F.R.S., and A. E. BROWN, B.Sc. Crown 4to, portrait, 5 maps. 43 plates including 15 chromo-lithographs, and 67 wood engravings, 30s. *nett.*

*** A few copies only of this work remain for sale

C. B. LOCKWOOD, F.R.C.S.
Hunterian Professor, Royal College of Surgeons of England; Surgeon to the Great Northern Hospital; Senior Demonstrator of Anatomy and Operative Surgery in St. Bartholomew's Hospital.

HUNTERIAN LECTURES ON THE MORBID ANATOMY, PATHOLOGY AND TREATMENT OF HERNIA. 36 illustrations, Demy 8vo, 5s.

J. S. LOMBARD, M.D.
Formerly Assistant Professor of Physiology in Harvard College.

I.

EXPERIMENTAL RESEARCHES ON THE REGIONAL TEMPERATURE OF THE HEAD, under Conditions of Rest, Intellectual Activity, and Emotion. With Illustrations, 8vo, 8s.

II.

ON THE NORMAL TEMPERATURE OF THE HEAD. 8vo, 5s.

WILLIAM THOMPSON LUSK, A.M., M.D.
Professor of Obstetrics and Diseases of Women in the Bellevue Hospital Medical College, &c.

THE SCIENCE AND ART OF MIDWIFERY. Fourth Edition, with numerous Illustrations, 8vo, 18s.

A. W. MACFARLANE, M.D., F.R.C.P. EDIN.
Examiner in Medical Jurisprudence in the University of Glasgow; Honorary Consulting Physician (late Physician) Kilmarnock Infirmary.

INSOMNIA AND ITS THERAPEUTICS. Medium 8vo, 12s. 6d.

SURGEON-MAJOR C. J. McNALLY, M.D., D.P.H. CAMB.
Fellow of the Madras University; Professor of Chemistry, Madras Medical College.

THE ELEMENTS OF SANITARY SCIENCE. Plates, Demy 8vo, 8s. 6d.

RAWDON MACNAMARA.
Professor of Materia Medica, Royal College of Surgeons, Ireland; Senior Surgeon to the Westmoreland (Lock) Government Hospital; Surgeon to the Meath Hospital, &c.

AN INTRODUCTION TO THE STUDY OF THE BRITISH PHARMACOPŒIA. Demy 32mo, 1s. 6d. [*Just published.*

JOHN MACPHERSON, M.D.
Inspector-General of Hospitals H.M. Bengal Army (Retired). Author of "Cholera in its Home," &c.

ANNALS OF CHOLERA FROM THE EARLIEST PERIODS TO THE YEAR 1817. With a map. Demy 8vo, 7s. 6d.

A. COWLEY MALLEY, B.A., M.B., B.CH., T.C.D.

PHOTO-MICROGRAPHY; including a description of the Wet Collodion and Gelatino-Bromide Processes, together with the best methods of Mounting and Preparing Microscopic Objects for Photo-Micrography. Second Edition, with Photographs and Illustrations, crown 8vo, 7s. 6d.

PATRICK MANSON, M.D., C.M.

THE FILARIA SANGUINIS HOMINIS; AND CERTAIN NEW FORMS OF PARASITIC DISEASE IN INDIA, CHINA, AND WARM COUNTRIES. Illustrated with Plates and Charts. 8vo, 10s. 6d.

JEFFERY A. MARSTON, M.D., C.B., F.R.C.S., M.R.C.P. LOND.
Surgeon General Medical Staff (Retired).

NOTES ON TYPHOID FEVER: Tropical Life and its Sequelæ. Crown 8vo, 3s. 6d. [*Now ready.*

EDWARD MARTIN, A.M., M.D.

MINOR SURGERY AND BANDAGING WITH AN APPENDIX ON VENEREAL DISEASES. 82 Illustrations, crown 8vo, 4s.

WILLIAM MARTINDALE, F.C.S.
Late Examiner of the Pharmaceutical Society, and late Teacher of Pharmacy and Demonstrator of Materia Medica at University College,

AND

W. WYNN WESTCOTT, M.B. LOND.
Deputy Coroner for Central Middlesex.

THE EXTRA PHARMACOPŒIA, with Medical References, and a Therapeutic Index of Diseases and Symptoms. Seventh Edition, limp roan, med. 24mo, 7s. 6d. [*Now ready.*

WILLIAM MARTINDALE, F.C.S.
Late Examiner of the Pharmaceutical Society, &c.

COCA, AND COCAINE. Their History, Medical and Economic Uses, and Medicinal Preparations. Second edition, coloured plate, fcap 8vo, 2s.

MATERIA MEDICA LABELS.

Adapted for Public and Private Collections. Compiled from the British Pharmacopœia of 1885, with the additions of 1890. The Labels are arranged in Two Divisions:—

Division I.—Comprises, with few exceptions, Substances of Organized Structure, obtained from the Vegetable and Animal Kingdoms.

Division II.—Comprises Chemical Materia Medica, including Alcohols, Alkaloids, Sugars, and Neutral Bodies.

On plain paper, 10s. 6d. *nett.* On gummed paper, 12s. 6d. *nett.*

The 24 additional Labels of 1890 only, 1s. *nett.*

*** Specimens of the Labels, of which there are over 470, will be sent on application.

S. E. MAUNSELL, L.R.C.S.I.
Surgeon-Major, Medical Staff.

NOTES OF MEDICAL EXPERIENCES IN INDIA PRINCIPALLY WITH REFERENCE TO DISEASES OF THE EYE. With Map, post 8vo, 3s. 6d.

Wm. JULIUS MICKLE, M.D., F.R.C.P. LOND.
Medical Superintendent, Grove Hall Asylum, London, &c.

GENERAL PARALYSIS OF THE INSANE. Second Edition, enlarged and rewritten, 8vo, 14s.

ANGEL MONEY, M.D. LOND., F.R.C.P.
Late Assistant Physician to University College Hospital, and to the Hospital for Sick Children Great Ormond Street.

I.

TREATMENT OF DISEASE IN CHILDREN: EMBODYING THE OUTLINES OF DIAGNOSIS AND THE CHIEF PATHOLOGICAL DIFFERENCES BETWEEN CHILDREN AND ADULTS. Second edition, with plates, crown 8vo, 10s. 6d.
[LEWIS'S PRACTICAL SERIES.]

II.

THE STUDENT'S TEXTBOOK OF THE PRACTICE OF MEDICINE. Fcap. 8vo, 6s. 6d.

A. STANFORD MORTON, M.B., F.R.C.S. ENG.
Assistant Surgeon to the Moorfields Ophthalmic Hospital; Ophthalmic Surgeon to the Great Northern Central Hospital.

REFRACTION OF THE EYE: Its Diagnosis, and the Correction of its Errors. Fourth Edition, with Illustrations, small 8vo, 3s. 6d.

C. W. MANSELL MOULLIN, M.A., M.D. OXON., F.R.C.S. ENG.
Assistant Surgeon and Senior Demonstrator of Anatomy at the London Hospital; formerly Radcliffe Travelling Fellow and Fellow of Pembroke College, Oxford.

SPRAINS; THEIR CONSEQUENCES AND TREATMENT. Crown 8vo, 5s.

PAUL F. MUNDE, M.D.
Professor of Gynecology at the New York Polyclinic; President of the New York Obstetrica Society and Vice-President of the British Gynecological Society, &c.

THE MANAGEMENT OF PREGNANCY, PARTURITION, AND THE PUERPERAL STATE. Second edition, square 8vo, 3s. 6d.

WILLIAM MURRAY, M.D., F.R.C.P. LOND.
Consulting Physician to the Children's Hospital, Newcastle-on-Tyne, &c.

ILLUSTRATIONS OF THE INDUCTIVE METHOD IN MEDICINE. Crown 8vo, 3s. 6d.

WILLIAM MURRELL, M.D., F.R.C.P.
Physician to, and Lecturer on Pharmacology and Therapeutics at Westminster Hospital; late Examiner in Materia Medica to the Royal College of Physicians of London, &c.

I.

MASSOTHERAPEUTICS, OR MASSAGE AS A MODE OF TREATMENT. Fifth edition, with Illustrations, crown 8vo, 4s. 6d.

II.

WHAT TO DO IN CASES OF POISONING. Seventh edition, royal 32mo., 3s. 6d. [*Now ready.*

III.

CHRONIC BRONCHITIS AND ITS TREATMENT. Crown 8vo, 3s. 6d.

DR. FELIX von NIEMEYER.

Late Professor of Pathology and Therapeutics; Director of the Medical Clinic of the University of Tübingen.

A TEXT-BOOK OF PRACTICAL MEDICINE, WITH PARTICULAR REFERENCE TO PHYSIOLOGY AND PATHOLOGICAL ANATOMY. Translated from the Eighth German Edition by special permission of the Author, by GEORGE H. HUMPHERY, M.D., and CHARLES E. HACKLEY, M.D. Revised edition, 2 vols. large 8vo, 36s.

GEORGE OLIVER, M.D., F.R.C.P.

I.

THE HARROGATE WATERS: Data Chemical and Therapeutical, with notes on the Climate of Harrogate. Addressed to the Medical Profession. With Map of the Wells, crown 8vo, 3s. 6d.

II.

ON BEDSIDE URINE TESTING: a Clinical Guide to the Observation of Urine in the course of Work. Fourth Edition, fcap. 8vo, 3s. 6d.

SAMUEL OSBORN, F.R.C.S.

Surgeon to the Hospital for Women, Soho Square; Surgeon to the Royal Naval Artillery Volunteers.

I.

AMBULANCE LECTURES: FIRST AID. Second edition, with Illustrations, fcap. 8vo, 1s. 6d.

II.

AMBULANCE LECTURES: HOME NURSING AND HYGIENE. Second edition, with Illustrations, fcap. 8vo, 2s.

[*Just published.*

WILLIAM OSLER, M.D., F.R.C.P. LOND.

Professor of Clinical Medicine in the University of Pennsylvania, &c.

THE CEREBRAL PALSIES OF CHILDREN. A Clinical Study from the Infirmary for Nervous Diseases, Philadelphia. Demy 8vo, 5s.

KURRE W. OSTROM.

Instructor in Massage and Swedish Movements in the Philadelphia Polyclinic and College for Graduates in Medicine.

MASSAGE AND THE ORIGINAL SWEDISH MOVE-MENTS; their application to various diseases of the body. Second edition, with Illustrations, 12mo, 3s. 6d. *nett.* [*Now ready.*

ROBERT W. PARKER.

Senior Surgeon to the East London Hospital for Children; Surgeon to the German Hospital.

I

DIPHTHERIA: ITS NATURE AND TREATMENT, WITH SPECIAL REFERENCE TO THE OPERATION, AFTER-TREATMENT AND COMPLICATIONS OF TRACHEOTOMY. Third Edition, with Illustrations, 8vo, 6s. [*Now ready.*

II.

CONGENITAL CLUB-FOOT; ITS NATURE AND TREATMENT. With special reference to the subcutaneous division of Tarsal Ligaments. 8vo, 7s. 6d.

LOUIS C. PARKES, M.D., D.P.H. LOND. UNIV.
Fellow of the Sanitary Institute, and Member of the Board of Examiners; Lecturer on Public Health at St. George's Hospital Medical School.

HYGIENE AND PUBLIC HEALTH. Third edition, with numerous Illustrations, crown 8vo, 10s. 6d. [*Just Published.*
[LEWIS'S PRACTICAL SERIES.]

JOHN S. PARRY, M.D.
Obstetrician to the Philadelphia Hospital, Vice-President of the Obstetrical and Pathological Societies of Philadelphia, &c.

EXTRA-UTERINE PREGNANCY; Its Causes, Species, Pathological Anatomy, Clinical History, Diagnosis, Prognosis and Treatment. 8vo, 8s.

THEOPHILUS PARVIN, M.D.
Professor of Obstetrics and Diseases of Women and Children at the Jefferson Medical School.

LECTURES ON OBSTETRIC NURSING, Delivered at the Training School for Nurses of the Philadelphia Hospital. Post 8vo, 2s. 6d.

E. RANDOLPH PEASLEE, M.D., LL.D.
Late Professor of Gynæcology in the Medical Department of Dartmouth College; President of New York Academy of Medicine, &c., &c.

OVARIAN TUMOURS: Their Pathology, Diagnosis, and Treatment, especially by Ovariotomy. Illustrations, roy. 8vo, 16s.

HENRY G. PIFFARD, A.M., M.D.
Clinical Professor of Dermatology, University of the City of New York; Surgeon in Charge of the New York Dispensary for Diseases of the Skin, &c.

A PRACTICAL TREATISE ON DISEASES OF THE SKIN. With 50 full page Original Plates and 33 Illustrations in the Text, 4to, £2 12s. 6d. *nett.* [*Just published.*

G. V. POORE, M.D., F.R.C.P.
Professor of Medical Jurisprudence, University College; Assistant Physician to, and Physician in charge of the Throat Department of, University College Hospital.

LECTURES ON THE PHYSICAL EXAMINATION OF THE MOUTH AND THROAT. With an Appendix of Cases. 8vo, 3s. 6d.

R. DOUGLAS POWELL, M.D., F.R.C.P.,
Physician Extra-ordinary to H.M. the Queen; Physician to the Middlesex Hospital; Consulting Physician to the Hospital for Consumption and Diseases of the Chest at Brompton.

DISEASES OF THE LUNGS AND PLEURÆ, INCLUD-ING CONSUMPTION. Fourth Edition, with coloured plates and wood engravings, 8vo, 18s. [*Now ready*

TABLE OF PHYSICAL EXAMINATION OF THE LUNGS: with Note on International Nomenclature of Physical Signs (reprinted from DR. POWELL'S "Diseases of the Lungs,"). On one sheet, 6d.

HERBERT A. POWELL, M.A., M.D., M.CH. OXON., F.R.C.S.E.

THE SURGICAL ASPECT OF TRAUMATIC IN-SANITY. Medium 8vo, 2s. 6d.

URBAN PRITCHARD, M.D. EDIN., F.R.C.S. ENG.
Professor of Aural Surgery at King's College, London; Aural Surgeon to King's College Hospital; Senior Surgeon to the Royal Ear Hospital.

HANDBOOK OF DISEASES OF THE EAR FOR THE USE OF STUDENTS AND PRACTITIONERS. Second edition, With Illustrations, crown 8vo, 5s. [LEWIS'S PRACTICAL SERIES.]

CHARLES W. PURDY, M.D. (QUEEN'S UNIV.)
Professor of Genito-Urinary and Renal Diseases in the Chicago Polyclinic, &c.,&c.

BRIGHT'S DISEASE AND THE ALLIED AFFECTIONS OF THE KIDNEYS. With Illustrations, large 8vo, 8s. 6d.

DR. THEODOR PUSCHMANN.
Public Professor in Ordinary at the University of Vienna.

A HISTORY OF MEDICAL EDUCATION FROM THE MOST REMOTE TO THE MOST RECENT TIMES. Translated and edited by EVAN H. HARE, M.A. OXON., F.R.C.S. ENG., L.S.A. Demy 8vo, 21s. [*Now ready.*

CHARLES HENRY RALFE, M.A., M.D. CANTAB., F.R.C.P. LOND.
Assistant Physician to the London Hospital; Examiner in Medicine to the University of Durham, &c., &c

A PRACTICAL TREATISE ON DISEASES OF THE KIDNEYS AND URINARY DERANGEMENTS. With Illustrations, crown 8vo, 10s. 6d. [LEWIS'S PRACTICAL SERIES.]

FRANCIS H. RANKIN, M.D.
President of the New York Medical Society.

HYGIENE OF CHILDHOOD. Suggestions for the care of Children after the Period of Infancy to the completion of Puberty. Crown 8vo, 3s.

AMBROSE L. RANNEY, A.M., M.D.
Professor of the Anatomy and Physiology of the Nervous System in the New York Post-Graduate Medical School and Hospital, &c.

THE APPLIED ANATOMY OF THE NERVOUS SYS-TEM. Second edition, 238 Illustrations, large 8vo, 21s.

H. A. REEVES, F.R.C.S. EDIN.
Senior Assistant Surgeon and Teacher of Practical Surgery at the London Hospital; Surgeon to the Royal Orthopædic Hospital.

BODILY DEFORMITIES AND THEIR TREATMENT: A HANDBOOK OF PRACTICAL ORTHOPÆDICS. Illustrations, crown 8vo, 8s. 6d. [LEWIS'S PRACTICAL SERIES.]

RALPH RICHARDSON, M.A., M.D.
Fellow of the College of Physicians, Edinburgh.

ON THE NATURE OF LIFE: An Introductory Chapter to Pathology. Second edition, revised and enlarged. Fcap. 4to, 10s. 6d.

W. RICHARDSON, M.A., M.D., M.R.C.P.

REMARKS ON DIABETES, ESPECIALLY IN REFERENCE TO TREATMENT. Demy 8vo, 4s. 6d.

SAMUEL RIDEAL, D.SC. (LOND.), F.I.C., F.C.S., F.G.S.
Fellow of University College, London.

PRACTICAL ORGANIC CHEMISTRY; The Detection and Properties of some of the more important Organic Compounds. 12mo, 2s. 6d.

II.

PRACTICAL CHEMISTRY FOR MEDICAL STUDENTS, required at the First Examination of the Conjoint Examining Board in England. Foolscap 8vo, 2s. [*Just published.*

J. JAMES RIDGE, M.D.
Medical Officer of Health, Enfield.

ALCOHOL AND PUBLIC HEALTH.
Second Edition, crown 8vo, 2s. [*Now ready.*

E. A. RIDSDALE.
Associate of the Royal School of Mines.

COSMIC EVOLUTION; being Speculations on the Origin of our Environment. Fcap. 8vo, 3s.

SYDNEY RINGER, M.D., F.R.S.
Professor of the Principles and Practice of Medicine in University College; Physician to, and Professor of Clinical Medicine in, University College Hospital.

I.

A HANDBOOK OF THERAPEUTICS. Twelfth Edition, thoroughly revised, 8vo, 15s.

II.

ON THE TEMPERATURE OF THE BODY AS A MEANS OF DIAGNOSIS AND PROGNOSIS IN PHTHISIS. Second edition, small 8vo, 2s. 6d.

FREDERICK T. ROBERTS, M.D., B.SC., F.R.C.P.
Examiner in Medicine at the University of London and for the Conjoint Board; Professor of Materia Medica and Therapeutics and of Clinical Medicine in University College; Physician to University College Hospital; Physician to Brompton Consumption Hospital, &c.

I.

A HANDBOOK OF THE THEORY AND PRACTICE OF MEDICINE. Eighth edition, with Illustrations, in one volume, large 8vo, 21s.

II.

THE OFFICINAL MATERIA MEDICA.
Second edition, entirely rewritten in accordance with the latest British Pharmacopœia, fcap. 8vo, 7s. 6d.

III.

NOTES ON THE ADDITIONS MADE TO THE BRITISH PHARMACOPŒIA, 1890. Fcap. 8vo, 1s. [*Now ready*

R. LAWTON ROBERTS, M.D. LOND., D.P.H. CAMB., M.R.C.S. ENG.
Honorary Life Member of, and Lecturer and Examiner to, the St. John Ambulance Association.

I.

ILLUSTRATED LECTURES ON AMBULANCE WORK. Fourth edition, copiously Illustrated, crown 8vo, 2s. 6d. [*Now ready.*

II.

ILLUSTRATED LECTURES ON NURSING AND HYGIENE. Second edition, with Illustrations, crown 8vo, 2s. 6d. [*Now ready.*

D. B. ST. JOHN ROOSA, M.D.
Professor of Diseases of the Eye and Ear in the New York Post-Graduate Medical School; Consulting Surgeon to the Brooklyn Eye and Ear Hospital, &c.

A PRACTICAL TREATISE ON THE DISEASES OF THE EAR: Including a Sketch of Aural Anatomy and Physiology. Seventh edition, Illustrated, large 8vo, 25s. [*Now ready.*

ROBSON ROOSE, M.D., LL.D., F.C.S.
Fellow of the Royal College of Physicians in Edinburgh.

I.

GOUT, AND ITS RELATIONS TO DISEASES OF THE LIVER AND KIDNEYS. Sixth Edition, crown 8vo, 3s. 6d.

II.

NERVE PROSTRATION AND OTHER FUNCTIONAL DISORDERS OF DAILY LIFE. Second edition, demy 8vo, 18s. [*Now ready.*

III.

LEPROSY AND ITS PREVENTION: as Illustrated by Norwegian Experience. Crown 8vo, 3s. 6d.

WILLIAM ROSE, M.B., B.S. LOND., F.R.C.S.
Professor of Surgery in King's College, London, and Surgeon to King's College Hospital

HARELIP AND CLEFT PALATE. With Illustrations, demy 8vo, 6s. [*Just published.*

BERNARD ROTH, F.R.C.S.
Fellow of the Medical Society of London; Member of the Clinical and Pathological Societies and of the Medical Officers of Schools' Association.

THE TREATMENT OF LATERAL CURVATURE OF THE SPINE. With Photographic and other Illustrations, demy 8vo, 5s.

J. BURDON SANDERSON, M.D., LL.D., F.R.S.
Jodrell Professor of Physiology in University College, London.

UNIVERSITY COLLEGE COURSE OF PRACTICAL EXERCISES IN PHYSIOLOGY. With the co-operation of F. J. M. PAGE, B.Sc., F.C.S.; W. NORTH, B.A., F.C.S., and AUG. WALLER, M.D. Demy 8vo, 3s. 6d.

W. H. O. SANKEY, M.D. LOND., F.R.C.P.

Late Lecturer on Mental Diseases, University College, London, etc.

LECTURES ON MENTAL DISEASE. Second Edition, with coloured Plates, 8vo, 12s. 6d.

THOMAS D. SAVILL, M.D. LOND., D.P.H. CAMB.

Medical Superintendent of the Paddington Infirmary, London; Corresponding Member of the Société Anatomique, Paris; formerly Assistant Physician and Pathologist to the West London Hospital.

ON AN EPIDEMIC SKIN DISEASE, RESEMBLING ECZEMA AND PITYRIASIS RUBRA IN SOME RESPECTS. 8vo, 3s. *nett.*

JOHN SAVORY.

Member of the Society of Apothecaries, London.

A COMPENDIUM OF DOMESTIC MEDICINE AND COMPANION TO THE MEDICINE CHEST: Intended as a source of easy reference for Clergymen, Master Mariners, and Travellers; and for Families resident at a distance from professional assistance. Tenth Edition, sm. 8vo, 5s.

E. SCHMIEGELOW, M.D.

Consulting Physician in Laryngology to the Municipal Hospital and Director of the Oto-Laryngological Department in the Polyclinic at Copenhagen.

ASTHMA: Especially in its Relation to Nasal Disease. Demy 8vo, 4s. 6d.

DR. B. S. SCHULTZE.

Professor of Gynecology; Director of the Lying-in Hospital, and of the Gynecological Clinic at Jena.

THE PATHOLOGY AND TREATMENT OF DIS-PLACEMENTS OF THE UTERUS. Translated by J. J. MACAN, M.A., M.R.C.S. and edited by A. V. MACAN, M.B., M.Ch., Master of the Rotunda Lying-in Hospital, Dublin. With 120 Illustrations, medium 8vo, 12s. 6d.

JOHN SCOTT, B.A., R.U.I.

Scholar and Prizeman in Medicine, Queen's College, Belfast; Gold Medallist in Obstetrics, Gynæcology, and Diseases of Children, Ulster Hospital, Belfast.

MANUAL OF URINE TESTING INCLUDING THE PHYSICAL CHARACTERS, QUALITATIVE AND QUANTITATIVE EXAMINATION OF THE URINE: together with Clinical information to be derived therefrom. 32mo, 1s.

JOHN SHAW, M.D. LOND., M.R.C.P.

Obstetric Physician to the North-West London Hospital.

ANTISEPTICS IN OBSTETRIC NURSING. A Text-book for Nurses on the Application of Antiseptics to Gynæcology and Midwifery. Coloured plate and woodcuts, 8vo, 3s. 6d.

A. J. C. SKENE, M.D.

Professor of Gynecology in the Long Island College Hospital, Brooklyn, New York.

TREATISE ON THE DISEASES OF WOMEN, FOR THE USE OF STUDENTS AND PRACTITIONERS. Second edition with coloured plates and 251 engravings, large 8vo, 28s.

J. LEWIS SMITH, M.D.

Physician to the New York Foundling Asylum; Clinical Professor of Diseases of Children in Bellevue Hospital Medical College.

A TREATISE ON THE DISEASES OF INFANCY AND CHILDHOOD. Seventh Edition, with Illustrations, large 8vo, 21s. [*Just published.*

FRANCIS W. SMITH, M.B., B.S.

THE SALINE WATERS OF LEAMINGTON. Second Edit., with Illustrations, crown 8vo, 1s. *nett.*

JOHN KENT SPENDER, M.D. LOND.

Physician to the Royal Mineral Water Hospital, Bath.

THE EARLY SYMPTOMS AND THE EARLY TREAT-MENT OF OSTEO-ARTHRITIS, commonly called Rheumatoid Arthritis, with special reference to the Bath Thermal Waters. Sm. 8vo, 2s. 6d.

LOUIS STARR, M.D.

Physician to the Children's Hospital, Philadelphia; late Clinical Professor of Diseases of Children in the Hospital of the University of Pennsylvania.

HYGIENE OF THE NURSERY. Including the General Regimen and Feeding of Infants and Children; Massage, and the Domestic Management of the Ordinary Emergencies of Early Life. Third edition, with Illustrations, crown 8vo, 3s. 6d. [*Just published.*

JAMES STARTIN, M.B., M.R.C.S.

Senior Surgeon to the London Skin Hospital.

I.

A PHARMACOPŒIA FOR DISEASES OF THE SKIN. Third Edition, 32mo, 2s. 6d.

II.

LECTURES ON THE PARASITIC DISEASES OF THE SKIN. VEGETOID AND ANIMAL. With Illustrations, crown 8vo, 2s. 6d.

W. E. STEAVENSON, M.D.

Late in charge of the Electrical Department in St. Bartholomew's Hospital,

AND

H. LEWIS JONES, M.A., M.D., M.R.C.P.

Medical Officer in charge of the Electrical Department in St. Bartholomew's Hospital.

MEDICAL ELECTRICITY. A Practical Handbook for Students and Practitioners. With Illustrations, crown 8vo, 9s.

[*Now ready.*

[LEWIS'S PRACTICAL SERIES].

JOHN LINDSAY STEVEN, M.D.

Assistant Physician and Pathologist, Glasgow Royal Infirmary; Physician for Out-patients, Royal Hospital for Sick Children, Glasgow; Lecturer on Pathology, St. Mungo's and Queen Margaret Colleges, Glasgow, &c.

THE PATHOLOGY OF MEDIASTINAL TUMOURS. With special reference to Diagnosis. With Plates, 8vo, 4s. 6d.

[*Just published.*

LEWIS A. STIMSON, B.A., M.D.

Surgeon to the Presbyterian and Bellevue Hospitals; Professor of Clinical Surgery in the Medical Faculty of the University of the City of New York, &c.

A MANUAL OF OPERATIVE SURGERY. Second Edition, with three hundred and forty-two Illustrations, post 8vo, 10s. 6d.

ADOLF STRÜMPELL.

Professor and Director of the Medical Clinique at Erlangen.

A TEXT-BOOK OF MEDICINE FOR STUDENTS AND PRACTITIONERS. Second edition translated from the German by Dr. H. F. VICKERY and Dr. P. C. KNAPP, with Editorial Notes by Dr. F. C. SHATTUCK, Visiting Physician to the Massachusetts General Hospital, etc. Complete in one large vol., with 119 Illustrations, imp. 8vo, 28s.

JUKES DE STYRAP, M.K.Q.C.P., ETC.

Physician-Extraordinary, late Physician in Ordinary, to the Salop Infirmary; Consulting Physician to the South Salop and Montgomeryshire Infirmaries, etc.

I.

THE YOUNG PRACTITIONER: WITH PRACTICAL HINTS AND INSTRUCTIVE SUGGESTIONS, AS SUBSIDIARY AIDS, FOR HIS GUIDANCE ON ENTERING INTO PRIVATE PRACTICE. Demy 8vo, 7s. 6d. *nett.*

II.

A CODE OF MEDICAL ETHICS: WITH GENERAL AND SPECIAL RULES FOR THE GUIDANCE OF THE FACULTY AND THE PUBLIC IN THE COMPLEX RELATIONS OF PROFESSIONAL LIFE. Third edition, demy 8vo 3s. *nett.*

III.

MEDICO-CHIRURGICAL TARIFFS.
Fourth Edition, fcap. 4to, revised and enlarged, 2s. *nett.*

IV.

THE YOUNG PRACTITIONER: HIS CODE AND TARIFF. Being the above three works in one volume. Demy 8vo, 10s. 6d. *nett.*

C. W. SUCKLING, M.D. LOND., M.R.C.P.

Professor of Materia Medica and Therapeutics at the Queen's College, Physician to the Queen's Hospital, Birmingham, etc.

I.

ON THE DIAGNOSIS OF DISEASES OF THE BRAIN, SPINAL CORD, AND NERVES. With Illustrations, crown 8vo, 8s. 6d.

II.

ON THE TREATMENT OF DISEASES OF THE NERVOUS SYSTEM. Crown 8vo, 7s. 6d.

JOHN BLAND SUTTON, F.R.C.S.

Lecturer on Comparative Anatomy, Senior Demonstrator of Anatomy, and Assistant Surgeon to the Middlesex Hospital; Erasmus Wilson Lecturer, Royal College of Surgeons, England.

LIGAMENTS: THEIR NATURE AND MORPHOLOGY.
With numerous Illustrations, post 8vo, 4s. 6d.

HENRY R. SWANZY, A.M., M.B., F.R.C.S.I.

Examiner in Ophthalmic Surgery in the University of Dublin, and in the Royal University of Ireland; Surgeon to the National Eye and Ear Infirmary, and Ophthalmic Surgeon to the Adelaide Hospital, Dublin.

A HANDBOOK OF THE DISEASES OF THE EYE AND THEIR TREATMENT. Fourth Edition, Illustrated with wood-engravings, coloured plates, colour tests, etc., small 8vo, 10s. 6d.
[*Just Published.*

EUGENE S. TALBOT, M.D., D.D.S.

Professor of Dental Surgery in the Woman's Medical College; Lecturer on Dental Pathology and Surgery in Rush Medical College, Chicago.

IRREGULARITIES OF THE TEETH AND THEIR TREATMENT. With 152 Illustrations, royal 8vo, 10s. 6d.

ALBERT TAYLOR.

Associate Sanitary Institute; Chief Sanitary Inspector to the Vestry of St. George, Hanover Square, etc.

THE SANITARY INSPECTOR'S HANDBOOK. With Illustrations, cr. 8vo., 5s. [*Now ready.*

H. COUPLAND TAYLOR, M.D.

Fellow of the Royal Meteorological Society.

WANDERINGS IN SEARCH OF HEALTH, OR MEDICAL AND METEOROLOGICAL NOTES ON VARIOUS FOREIGN HEALTH RESORTS. With Illustrations, crown 8vo, 9s.

JOHN DAVIES THOMAS, M.D. LOND., F.R.C.S. ENG.

Physician to the Adelaide Hospital, S. Australia.

HYDATID DISEASE OF THE LUNGS. Demy 8vo, 2s.

HUGH OWEN THOMAS, M.R.C.S.

CONTRIBUTIONS TO SURGERY AND MEDICINE:—

PART 1.—Intestinal Obstruction; with an Appendix on the Action of Remedies. 10s.

" 2.—The Principles of the Treatment of Joint Disease, Inflammation, Anchylosis, Reduction of Joint Deformity, Bone Setting. 5s.

" 3.—Fractures, Dislocations, Diseases and Deformities of the Bones of the Trunk and Upper Extremities. 10s.

" 4.—The Collegian of 1666 and the Collegians of 1885; or what is recognised treatment? Second Edition, 1s.

" 5.—On Fractures of the Lower Jaw. 1s.

" 6.—The Principles of the Treatment of Fractures and Dislocations. 10s.

" 7.—Fractures, Dislocations, Deformities, and Diseases of the Lower Extremities, 10s.

" 8.—The Inhibition of Nerves by Drugs. Proof that Inhibitory Nerve-Fibres do not exist. 1s.

J. C. THOROWGOOD, M.D.

Assistant Physician to the City of London Hospital for Diseases of the Chest.

THE CLIMATIC TREATMENT OF CONSUMPTION AND CHRONIC LUNG DISEASES. Third Edition, post 8vo, 3s. 6d.

D. HACK TUKE, M.D., LL.D.

Fellow of the Royal College of Physicians, London.

THE INSANE IN THE UNITED STATES AND CANADA. Demy 8vo, 7s. 6d.

DR. R. ULTZMANN.

ON STERILITY AND IMPOTENCE IN MAN. Translated from the German with notes and additions by ARTHUR COOPER, L.R.C.P., M.R.C.S., Surgeon to the Westminster General Dispensary. With Illustrations, fcap. 8vo, 2s. 6d.

W. H. VAN BUREN, M.D., LL.D.

Professor of Surgery in the Bellevue Hospital Medical College.

DISEASES OF THE RECTUM: And the Surgery of the Lower Bowel. Second Edition, with Illustrations, 8vo, 14s.

ALFRED VOGEL, M.D.

Professor of Clinical Medicine in the University of Dorpat, Russia.

A PRACTICAL TREATISE ON THE DISEASES OF CHILDREN. Third Edition, translated and edited by H. RAPHAEL, M.D., from the Eighth German Edition, illustrated by six lithographic plates, part coloured, royal 8vo, 18s.

A. DUNBAR WALKER, M.D., C.M.

THE PARENT'S MEDICAL NOTE BOOK. Oblong post 8vo, cloth, 1s. 6d.

JOHN RICHARD WARDELL, M.D. EDIN., F.R.C.P. LOND.

Late Consulting Physician to the General Hospital Tunbridge Wells.

CONTRIBUTIONS TO PATHOLOGY AND THE PRAC- TICE OF MEDICINE. Medium 8vo, 21s.

W. SPENCER WATSON, B.M. LOND., F.R.C.S. ENG.

Surgeon to the Throat Department of the Great Northern Hospital; Senior Surgeon to the Royal South London Ophthalmic Hospital.

DISEASES OF THE NOSE AND ITS ACCESSORY CAVITIES. Second edition, with Illustrations, demy 8vo, 12s. 6d. [*Now ready.*

II.

THE ANATOMY AND DISEASES OF THE LACHRY-MAL PASSAGES. With Illustrations, demy 8vo, 2s. 6d. [*Now ready.*

III.

EYEBALL-TENSION: Its Effects on the Sight and its Treatment. With woodcuts, p. 8vo, 2s. 6d.

IV.

ON ABSCESS AND TUMOURS OF THE ORBIT. Post 8vo, 2s. 6d.

FRANCIS H. WELCH, F.R.C.S.

Surgeon Major, A.M.D.

ENTERIC FEVER: as Illustrated by Army Data at Home and Abroad, its Prevalence and Modifications, Ætiology, Pathology and Treatment. 8vo, 5s. 6d.

W. WYNN WESTCOTT, M.B.

Deputy Coroner for Central Middlesex.

SUICIDE; its History, Literature, Jurisprudence, and Prevention. Crown 8vo, 6s.

FRANK J. WETHERED, M.D.

Medical Registrar to the Middlesex Hospital, and Demonstrator of Practical Medicine in the Middlesex Hospital Medical School; late Assistant Physician to the City of London Chest Hospital, Victoria Park.

MEDICAL MICROSCOPY. A Guide to the Use of the Microscope in Medical Practice. With Illustrations, crown 8vo, 9s. [*Now ready.*

[LEWIS'S PRACTICAL SERIES].

E. G. WHITTLE, M.D. LOND., F.R.C.S. ENG.

Senior Surgeon to the Royal Alexandra Hospital for Sick Children, Brighton.

CONGESTIVE NEURASTHENIA, OR INSOMNIA AND NERVE DEPRESSION. Crown 8vo, 3s. 6d.

JOHN WILLIAMS, M.D., F.R.C.P.
Professor of Midwifery in University College, London; Obstetric Physician to University College Hospital; Physician Accoucheur to H.R.H. Princess Beatrice, &c.

CANCER OF THE UTERUS: Being the Harveian Lectures for 1886. Illustrated with Lithographic Plates, royal 8vo, 10s. 6d.

E. F. WILLOUGHBY, M.D. LOND.

THE NATURAL HISTORY OF SPECIFIC DISEASES OR STUDIES IN ŒTIOLOGY, IMMUNITY, AND PROPHYLAXIS. 8vo, 2s. 6d.

E. T. WILSON, M.B. OXON., F.R.C.P. LOND.
Physician to the Cheltenham General Hospital; Associate Metropolitan Association of Medical Officers of Health.

DISINFECTANTS AND ANTISEPTICS: HOW TO USE THEM. In Packets of one doz. price 1s., by post 1s. 1d.
[*Just thoroughly revised.*

DR. F. WINCKEL.
Formerly Professor and Director of the Gynæcological Clinic at the University of Rostock.

THE PATHOLOGY AND TREATMENT OF CHILD-BED: A Treatise for Physicians and Students. Translated from the Second German edition, with many additional notes by the Author, by J. R. CHADWICK, M.D. 8vo, 14s.

BERTRAM C. A. WINDLE, M.A., M.D. DUBL.
Professor of Anatomy in the Queen's College, Birmingham; Examiner in Anatomy in the Universities of Cambridge and Durham.

A HANDBOOK OF SURFACE ANATOMY AND LAND-MARKS. Illustrated, post 8vo, 3s. 6d.

EDWARD WOAKES, M.D. LOND.
Senior Aural Surgeon and Lecturer on Aural Surgery at the London Hospital; Surgeon to the London Throat Hospital.

I.

ON DEAFNESS, GIDDINESS AND NOISES IN THE HEAD.

VOL. I.—POST-NASAL CATARRH, AND DISEASES OF THE NOSE CAUSING DEAFNESS. With Illustrations, cr. 8vo, 6s. 6d.

VOL. II.—ON DEAFNESS, GIDDINESS AND NOISES IN THE HEAD. Third Edition, with Illustrations, cr. 8vo. [*In preparation.*

II.

NASAL POLYPUS: WITH NEURALGIA, HAY-FEVER, AND ASTHMA, IN RELATION TO ETHMOIDITIS. With Illustrations, cr. 8vo, 4s. 6d.

DAVID YOUNG, M.C., M.B., M.D.
Licentiate of the Royal College of Physicians, Edinburgh; Licentiate of the Royal College of Surgeons, Edinburgh, etc.

ROME IN WINTER AND THE TUSCAN HILLS IN SUMMER. A CONTRIBUTION TO THE CLIMATE OF ITALY. Small 8vo, 6s.

HERMANN VON ZEISSL, M.D.
Late Professor at the Imperial Royal University of Vienna

OUTLINES OF THE PATHOLOGY AND TREAT-MENT OF SYPHILIS AND ALLIED VENEREAL DISEASES. Second Edition, revised by M. VON ZEISSL, M.D., Privat-Docent for Diseases of the Skin and Syphilis at the Imperial Royal University of Vienna. Translated, with Notes, by H. RAPHAEL, M.D., Attending Physician for Diseases of Genito-Urinary Organs and Syphilis, Bellevue Hospital, Out-Patient Department. Large 8vo, 18s.

OSWALD ZIEMSSEN, M.D.
Knight of the Iron Cross, and of the Prussian Order of the Crown.

THE TREATMENT OF CONSTITUTIONAL SYPHI-LIS. Post 8vo, 3s. 6d.

Lewis's Diet Charts.
Price 6s. 6d. per packet of 100 charts, by post 6s. 10½d.

A suggestive set of diet tables for the use of Physicians, for handing to patients after consultation, modified to suit individual requirements, for Albuminuria, Alcoholism, Anæmia and Debility, Constipation, Diabetes, Diarrhœa, Dyspepsia, Fevers, Gout, Nervous Diseases, Obesity, Phthisis, Rheumatism (chronic), with blank chart for other diseases.

Lewis's Four-Hour Temperature Charts.
25s. per 1000, 14s. per 500, 3s. 6d. per 100, 2s. per 50, 1s. per 20, carriage free.

This form has been drawn up to meet the requirements of a chart on which the temperature and other observations can be recorded at intervals of four hours. They will be found most convenient in hospital and private practice. Each chart will last a week.

Clinical Charts for Temperature Observations, etc.
Arranged by W. RIGDEN, M.R.C.S. 50s. per 1000, 28s. per 500, 15s. per 250, 7s. per 100, or 1s. per dozen.

Each Chart is arranged for four weeks, and is ruled at the back for making notes of Cases; they are convenient in size, and are suitable both for hospital and private practice.

Lewis's Clinical Chart, specially designed for use with the Visiting List. This Temperature Chart is arranged for four weeks and measures 6 × 3 inches. 30s. per 1000, 16s. 6d. per 500, 3s. 6d. per 100, 1s. per 25, 6d. per 12.

Lewis's Nursing Chart.
25s. per 1000, 14s. per 500, 3s. 6d. per 100, 2s. per 50, or 1s. per 20.

These Charts afford a ready method of recording the progress of the case from day to day.

Boards to hold the Charts, price 1s.

Chart for Recording the Examination of Urine.
40s. per 1000; 25s. per 500; 15s. per 250; 7s. 6d. per 100; 1s. per 10.

These Charts are designed for the use of Medical Men, Analysts, and others making examinations of the urine of patients, and afford a very ready and convenient method of recording the results of the examination.

LEWIS'S PRACTICAL SERIES.

Under this title Mr. LEWIS is publishing a Series of Monographs, embracing the various branches of Medicine and Surgery.

The volumes are written by well-known Hospital Physicians and Surgeons, recognized as authorities in the subjects of which they treat. The works are intended to be of a THOROUGHLY PRACTICAL nature, calculated to meet the requirements of the practitioner and student, and to present the most recent information in a compact and readable form.

PUBLIC HEALTH LABORATORY WORK.
By HENRY R KENWOOD, M.B., D.P.H., F.C.S., Instructor in the Hygienic Laboratory, University College, and Assistant to Professor Corfield in the Public Health Department, University College. With Illustrations, cr. 8vo, 10s. 6d.

MEDICAL MICROSCOPY: A GUIDE TO THE USE OF THE MICROSCOPE IN MEDICAL PRACTICE. By FRANK J. WETHERED, M.D., M.R.C.P., Demonstrator of Practical Medicine in the Middlesex Hospital Medical School, &c. With Illustrations, crown 8vo, 9s.

MEDICAL ELECTRICITY. A PRACTICAL HANDBOOK FOR STUDENTS AND PRACTITIONERS. By W. E. STEAVENSON, M D., and H. LEWIS JONES, M.A, M.D., M.R.C.P., Medical Officer in charge of the Electrical Department in St Bartholomew's Hospital. With Illustrations, crown 8vo, 9s.

HYGIENE AND PUBLIC HEALTH.
By LOUIS C PARKES, M.D., D.P.H. LOND. UNIV., Fellow of the Sanitary Institute, and Member of the Board of Examiners. Third edition, with numerous Illustrations, cr. 8vo, 10s. 6d.

MANUAL OF OPHTHALMIC PRACTICE.
By C. HIGGENS, F.R.C.S., Ophthalmic Surgeon to Guy's Hospital; Lecturer on Ophthalmology at Guy's Hospital Medical School. Illustrations, cr. 8vo, 6s.

A PRACTICAL TEXTBOOK OF THE DISEASES OF WOMEN.
By A. H. N LEWERS, M.D. Lond., M.R.C.P., Obstetric Physician to the London Hospital, etc. Fourth Edition, with Illustrations, crown 8vo, 10s. 6d.

ANÆSTHETICS THEIR USES AND ADMINISTRATION.
By DUDLEY W. BUXTON, M.D., B.S., M.R.C.P., Administrator of Anæsthetics and Lecturer in University College Hospital, etc. Second Edition, with Illustrations, crown 8vo, 5s.

TREATMENT OF DISEASE IN CHILDREN.
By ANGEL MONEY, M.D., F.R.C.P., late Assistant Physician to the Hospital for Sick Children, Great Ormond Street. Second edition, cr. 8vo, 10s. 6d.

ON FEVERS: THEIR HISTORY, ETIOLOGY, DIAGNOSIS, PROGNOSIS, AND TREATMENT. By ALEXANDER COLLIE, M.D. Aberd., M.R.C.P. Illustrated with Coloured Plates, crown 8vo, 8s. 6d.

HANDBOOK OF DISEASES OF THE EAR FOR THE USE OF STUDENTS AND PRACTITIONERS. By URBAN PRITCHARD, M.D. Edin., F R.C.S. Eng., Professor of Aural Surgery at King's College, London. Second Edition, with Illustrations, crown 8vo, 5s.

A PRACTICAL TREATISE ON DISEASES OF THE KIDNEYS AND URINARY DERANGEMENTS. By C. H. RALFE, M.A., M.D. Cantab., F.R.C.P., Assistant Physician to the London Hospital; Examiner in Medicine to the University of Durham, etc., etc. Illustrations, cr. 8vo, 10s. 6d.

DENTAL SURGERY FOR MEDICAL PRACTITIONERS AND STUDENTS OF MEDICINE. By ASHLEY W. BARRETT, M.B. Lond., M.R.C.S., L.D.S., Dental Surgeon to, and Lecturer on Dental Surgery in the Medical School of, the London Hospital. Second edition, with Illustrations, cr. 8vo, 3s. 6d.

BODILY DEFORMITIES AND THEIR TREATMENT: A HANDBOOK OF PRACTICAL ORTHOPÆDICS. By H. A. REEVES, F.R.C.S. Edin., Senior Assistant Surgeon and Teacher of Practical Surgery at the London Hospital; etc. With numerous Illustrations, cr. 8vo, 8s 6d.

*** Further volumes will be announced in due course.

THE NEW SYDENHAM SOCIETY'S PUBLICATIONS.

President:—J. HUGHLINGS JACKSON, M.D., F.R.S.
Honorary Secretary:—JONATHAN HUTCHINSON, ESQ., F.R.S.
Treasurer:—W. SEDGWICK SAUNDERS, M.D., F.S.A.

Annual Subscription, One Guinea.

The Society issues translations of recent standard works by continental authors on subjects of general interest to the profession.

Amongst works recently issued are "Pozzi's Gynecology," "Flügge's Micro-Organisms," "Cohnheim's Pathology," "Henoch's Children," "Spiegelberg's Midwifery," "Hirsch's Historical and Geographical Pathology," "Ewald's Disorders of Digestion," works by Charcot, Duchenne, Begbie, Billroth, Graves, Koch, Hebra, Guttmann, etc.

The Society also has in hand an Atlas of Pathology with Coloured Plates, and a valuable and exhaustive "Lexicon of Medicine and the Allied Sciences."

The Annual Report, with full list of works published, and all further information will be sent on application.

PERIODICAL WORKS PUBLISHED BY H. K. LEWIS.

THE BRITISH JOURNAL OF DERMATOLOGY. Edited by William Anderson, H. G. Brooke, H. Radcliffe Crocker, T. Colcott Fox, Stephen Mackenzie, Malcolm Morris, J. F. Payne and J. J. Pringle. Published monthly, 1s. Annual Subscription, 12s. post free.

THE NEW YORK MEDICAL JOURNAL. A Weekly Review of Medicine. Annual Subscription, Thirty Shillings, post free.

THE THERAPEUTIC GAZETTE. A Monthly Journal, devoted to the Science of Pharmacology, and to the introduction of New Therapeutic Agents. Edited by Dr. R. M. Smith. Annual Subscription, 10s., post free.

THE GLASGOW MEDICAL JOURNAL. Published Monthly. Annual Subscription 20s., post free. Single numbers, 2s. each.

LIVERPOOL MEDICO-CHIRURGICAL JOURNAL, including the Proceedings of the Liverpool Medical Institution. Published twice yearly, 3s. 6d. each number.

TRANSACTIONS OF THE COLLEGE OF PHYSICIANS OF PHILADELPHIA Volumes I. to VI., 8vo, 10s. 6d. each.

MIDDLESEX HOSPITAL, REPORTS OF THE MEDICAL, SURGICAL, AND Pathological Registrars for 1883 to 1888. Demy 8vo, 2s. 6d. *nett* each volume.

THE NEW YORK JOURNAL OF GYNÆCOLOGY AND OBSTETRICS. Edited by Drs. A. H. Buckmaster and J. D. Emmet. Published monthly. Annual Subscription, 12s. 6d., post free.

ARCHIVES OF PEDIATRICS. A Monthly Journal, devoted to the Diseases of Infants and Children. Edited by Dr. W. P. Watson. Annual Subscription, 12s. 6d., post free.

*** MR. LEWIS is in constant communication with the leading publishing firms in America, and has transactions with them for the sale of his publications in that country. Advantageous arrangements are made in the interests of Authors for the publishing of their works in the United States.

Mr. Lewis's publications can be procured of all Booksellers in any part of the world.

London: Printed by H. K. Lewis, 136 Gower Street, W.C

7/1918

28.N.92.
A treatise on "unripe" cataract1898
Countway Library BEY8407
3 2044 046 138 426

28.N.92.
A treatise on "unripe" cataract1898
Countway Library BEY8407
3 2044 046 138 426